

MORPHOLOGY OF BRACHIALIS MUSCLE: VARIATIONS AND CLINICAL SIGNIFICANCE

Shifan Khandey.

Assistant Professor, Dept of Anatomy, DMCG, UAE.

ABSTRACT

Background: Though rare but variations of brachialis muscle insertion have been reported.

Material and Methods: The study was conducted on 115 upper limbs over a period of 4 years. The dissection of arm and forearm was done carefully to preserve all minute details, observing the morphology of insertion pattern and nerve supply.

Observation: Out of 115 specimens, 2 specimens showed insertion of brachialis into bicipital aponeuroses. Accessory slips were seen in 4 specimens which are mixed with main fibers at insertion point. Rarest of all was insertion of an accessory brachialis muscle on radial tuberosity in 2 specimens. The muscle originated from lateral border of shaft of humerus and shared a few fibers with main Brachialis muscle. The muscle was inserted into radius just below the radial tuberosity.

Conclusion: The identification of an inter-nervous plane may allow for improvement in the current anterior and anterolateral surgical approaches to the humerus. This could be one of a possible etiology of Radial tunnel syndrome.

KEYWORDS: Accessory brachialis; Radial tuberosity; Radial tunnel syndrome.

Address for Correspondence: Dr Shifan Khandey, Assistant Professor, Dept of Anatomy, DMCG, UAE. **E-Mail:** shifanafzal@yahoo.co.in

Access this Article online

Quick Response code



Web site: International Journal of Anatomy and Research
ISSN 2321-4287
www.ijmhr.org/ijar.htm

Received: 19 Dec 2013

Peer Review: 20 Dec 2013 Published (O):31 Jan 2014

Accepted: 09 Jan 2014 Published (P):30 Mar 2014

INTRODUCTION

Brachialis muscle or commonly known as workhorse of elbow is a powerful flexor of elbow joint. It is a muscle of the front of arm and takes origin from anterolateral and antero medial surfaces of the distal part of the shaft of the humerus. It also arises from intermuscular septa of arm. The muscle is inserted onto tuberosity of ulna and anterior surface of coronoid process of ulna. It is innervated by musculocutaneous nerve and proprioception by radial nerve. The muscle is occasionally doubled, inserted on antebrachial fascia, can give extra slip to biceps brachii, supinator or pronator teres. Rarest of all insertion on radial tuberosity [1, 2].

MATERIALS AND METHODS

The study was conducted on 115 upper limbs over a period of 4 years. The dissection of arm

and forearm was done carefully to preserve all minute details, observing the morphology of insertion pattern and nerve supply.

OBSERVATIONS

Out of 115 specimen, 2 specimen showed insertion of brachialis into bicipital aponeurosis. Accessory slips were seen in 4 specimens, which were mixed with main fibers at insertion point. Rarest of all was insertion of an accessory brachialis muscle on radial tuberosity. The muscle originated from lateral border of shaft of humerus and shared a few fibers with main brachialis muscle. The muscle was inserted into radius just below the radial tuberosity. It was supplied by radial nerve.

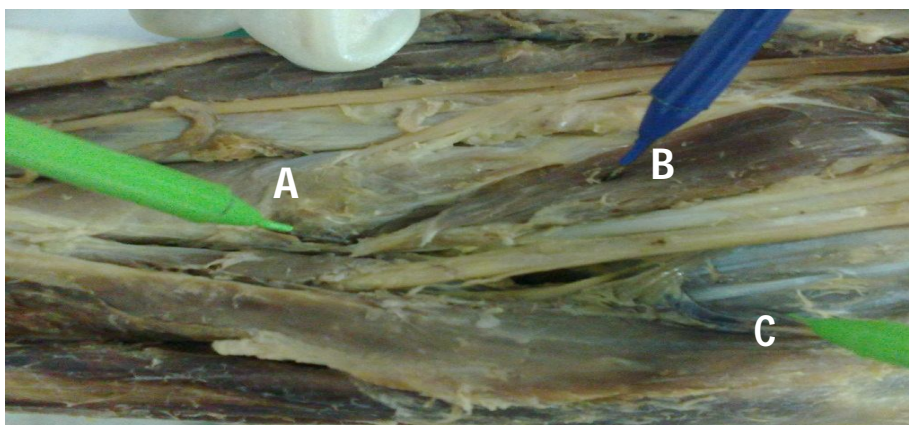


Fig. 1: **A** - Showing insertion of accessory slip onto Radial Tuberosity
B - Showing accessory slip
C - Showing main brachialis.

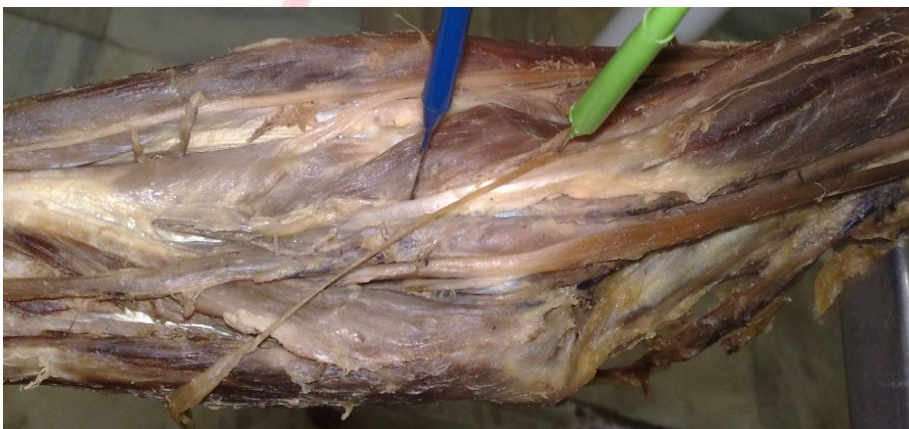

Fig. 2: Showing Accessory slips insertion into the main brachialis muscle.

DISCUSSION

Leonella et al [3], in his study of the brachialis through loupe magnification, described two heads of origin of the brachialis, the superficial head and the deep head. The superficial head was larger and proximal and it was inserted into the ulnar tuberosity. The deep head was smaller and distal and it was attached to the process of the ulna. Krishnamurthy A et al [4] described in a case report the radial insertion of brachialis muscle.

Benjamin et al [5], in his histological study on the insertion of the brachialis, described that the coronoid process of the ulna, which was the main site of attachment of the brachialis, contained more cortical tissue, as it played a very important role in the mechanical stabilization of the elbow joint. In the present study, there were no separate superficial and deep heads of origin of the brachialis.

Loukas et al [6], described the accessory brachialis from the mid shaft of the humerus and from the medial inter-muscular septa which compressed the median nerve and the brachial artery inserted into the fascia which covered the flexors of the ante brachial compartment.

Pai et al [7] described the accessory brachialis which originated from the lateral aspect of the brachialis and the lateral intermuscular septa inserted in the form of a tendon which splitted into two slips. The medial slip crossed the ulnar artery and merged with the deep fascia which covered the pronator teres and the lateral slip blended with the fascia which covered the supinator. Biswas et al [8], described the accessory brachialis from the medial supracondylar ridge, which compressed the neurovascular structures which were inserted into the fascia which covered the common flexor origin. In this case, the accessory muscle originated from the lateral surface of the shaft of the humerus and the lateral intermuscular septa.

The accessory slip compressed the radial nerve and blended with the main muscle and they got inserted into the radial tuberosity.

The clinical significance here, is the compression of the radial nerve, leading to entrapment neuropathy.

In the present study, instead of it's usual insertion into the ulna, the insertion of the brachialis into the posterior aspect of the radial

tuberosity, compromises the ulnar component of the elbow flexion.

The insertion of the biceps brachii into the posterior aspect of the radial tuberosity makes it a powerful supinator. However, in the present case, the biceps inserted anteriorly and the brachialis inserted posteriorly, which made the biceps a weak supinator.

EMBRYOLOGICAL BASIS:

Variation in muscle shape, number of slips, origin point and insertion can be well understood on embryological basis. The muscles of upper limb take origin from muscle primordia which is mesodermal in origin. After the formation of skeletal elements the single muscle mass starts to shape up into different muscles. Failure of the muscle primordia to disappear at certain places leads to all these variants of muscles [9]. The additional slip of brachialis and its insertion on radius can be explained on embryological basis.

CONCLUSION

The identification of an inter-nervous plane may allow for improvement in the current anterior and anterolateral surgical approaches to the humerus. This could be one of a possible etiology of Radial tunnel syndrome.

Conflicts of Interests: None

How to cite this article:

Shifan Khandey. MORPHOLOGY OF BRACHIALIS MUSCLE: VARIATIONS AND CLINICAL SIGNIFICANCE. *Int J Anat Res* 2014;2(1):184-86.

REFERENCES

- [1]. Williams PL, Dyson M. Gray's Anatomy. 37th edition. ELBS and Churchill Livingstone;p61.
- [2]. Moore KL. Clinically oriented anatomy. 3rd edition. Williams and Wilkins;p54.
- [3]. Leonello DT, Galley IJ, Bain GI. The brachialis muscle anatomy- A study in cadavers. *Journal of Bone and Joint Surgery*. 2007;89:1293.
- [4]. Krishnamurthy A, David S, Bagoji IB. The accessory brachialis muscle associated with a high division of the brachial artery. *International Journal of Anatomical Variations*, 2010;3:160.
- [5]. Benjamin M, Newell RLM, Ejevans. A study of the insertion of the tendon of the biceps brachii, the triceps and the brachialis in elderly dissection room cadavers. *Journal of Anatomy*;1992;180:327.
- [6]. Lukas M, Louis RG Jr. A case of an accessory brachialis muscle. *Clinical Anatomy*. 2006 Sept; 19;6:550.
- [7]. Pai MM, Nayak SR, Vadgaonkar R. Accessory brachialis muscle: a case report. *Morphologie* 2008 (Mar); 92:296
- [8]. Biswas S, Adhigari A, Kundu P. Variations in the cubital fossa. *International Journal of Anatomical Variations*, 2010;3:122.
- [9]. Langman J. *Medical embryology*. 2nd Ed .,Baltimore,Williams and Wilkins.1969:143-146.