

Case Report

DOUBLE INFERIOR VENA CAVA: A RARE BUT IMPORTANT ANATOMICAL VARIATION

Zhou Yaw Loo¹, Namrata Jhummon-Mahadnac².

^{*1} MBChB, PG Dip Surg Anat, ² B Med Sci, MBBS, PG Dip Surg Anat.

¹ & ² Department of Anatomy and Neuroscience, University of Melbourne, Grattan Street, Parkville, Melbourne, Victoria 3010, Australia.

ABSTRACT

Background: Congenital variations of the inferior vena cava are uncommon and are usually detected radiologically or at post-mortem. The present study describes two cases of double inferior vena cava, one encountered at routine anatomical dissection of a female cadaver and the other an incidental finding of a similar variation on pre-operative CT scan. The presence of such venous variations may lead to radiological misdiagnosis, inadvertent ligation during retroperitoneal surgery and has important implications for thromboembolic disease.

KEYWORDS: Double inferior vena cava; congenital.

Address for Correspondence: Dr. Zhou Yaw Loo, Department of Surgery, Box Hill Hospital, Nelson Road, Melbourne, VIC 3128, Australia. Phone: +614 3033 5733. **E-Mail:** zhouyaw.loo@gmail.com

Access this Article online

Quick Response code



Web site: International Journal of Anatomy and Research
ISSN 2321-4287
www.ijmhr.org/ijar.htm

Received: 04 Dec 2013

Peer Review: 04 Dec 2013 Published (O):30 Dec 2013

Accepted: 14 Dec 2013 Published (P):30 Dec 2013

INTRODUCTION

The inferior vena cava (IVC) usually forms from the union of both common iliac veins posterior to the right common iliac artery at the level of L5 vertebra. It courses superiorly on the right side of the abdominal aorta, grooving the bare area of the liver, passing through the central tendon of diaphragm at T8 vertebral level, and finally terminates in the right atrium of the heart [1].

Anomalies of the IVC are fairly rare and thought to result from mistakes in the complex embryological basis of this vessel [2,3]. The most common of IVC variations, the duplication of the IVC, has a reported incidence of 0.2 % to 3% in the general population [4,5,6] and with the advent of more modern radiological modalities, many such cases have been described in the literature [7]. Although usually asymptomatic and picked up at outpatient visits, these variations can be potentially dangerous in the operative setting.

In this study, we present two rare cases of duplication of the inferior vena cava. The first case describes a cadaveric occurrence of duplication of the IVC reproduced in vivo and in the second case, in a patient preparing for surgery highlighting the clinical relevance of this variation. Finally, we discuss the embryologic basis of IVC variations and review the clinical importance of this unusual finding.

CASE REPORTS

Case 1: The presence of a double inferior vena cava was observed during a routine dissection of a 80-year old female cadaver in the Department of Anatomy and Neuroscience of the University of Melbourne, Australia who died of metastatic lung cancer. The duplicated left IVC commenced at the left common iliac vein, ascended on the left lateral wall of the abdominal aorta, before joining with the left renal vein, which then crossed the abdominal aorta anteriorly to enter the right IVC.

Along its course, it received tributaries from the right IVC (via an abnormal venous anastomoses passing behind the aorta) and the left ovarian vein. The right ovarian vein joined the right renal vein. Both renal veins drained into the right IVC, which was formed from the union of both common iliac veins. (Figure 1) The origin, course and territories of other vessels as well as kidneys and ureters did not show any variation.

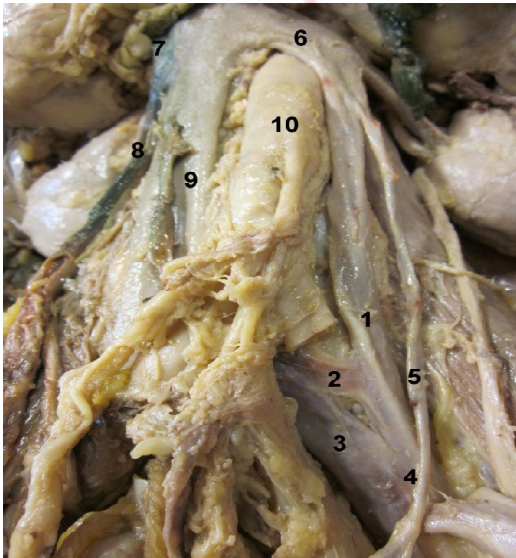


Figure 1: Duplicated left IVC (1) runs parallel to the right IVC (9), commencing at the left common iliac vein (4) and joins the left renal vein (6) which empties into the right IVC (9) by crossing anterior to the abdominal aorta (10). It receives tributaries from right IVC via an abnormal venous channel (2) and the left ovarian vein (5). The right ovarian vein (8) can be seen draining into the right renal vein (7). Both the common iliac veins are joined by a venous anastomosis (3).

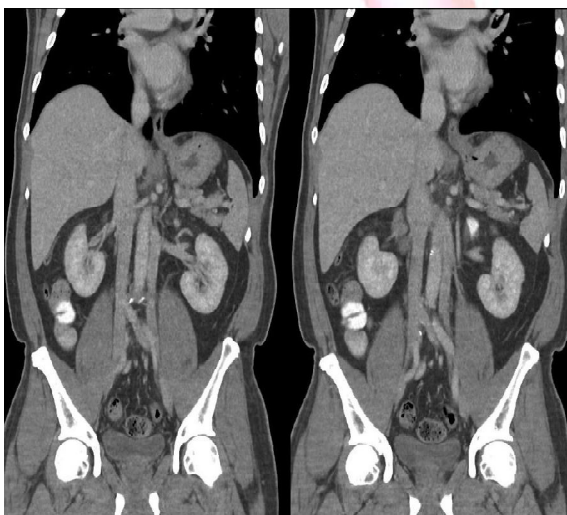

Figure 2: Coronal views of a CT scan showing double inferior vena cava in an asymptomatic patient. The variation is very similar to figure 1, with the duplicated left IVC originating from the left common iliac, terminating at the left renal vein which joins the right IVC by crossing anterior to the abdominal aorta.

Case 2: A 59 year-old man underwent a staging CT scan as part of the pre-operative work-up for radical prostatectomy after a positive biopsy for prostatic adenocarcinoma. The scan revealed an incidental finding of a double inferior vena cava, similar to the one described in Case 1. The duplicated left IVC can be seen originating from the left common iliac vein, terminating at the left renal vein, which then joined the right IVC via a pre aortic trunk as above. Both common iliac veins were connected by a venous anastomosis (Figure 2).

DISCUSSION

The complex embryological basis for the development of the IVC accounts for the many variations reported and, indeed, many systems of classifications of IVC variations are based on the embryological precursors to this vessel [2,3].

The most acknowledged theory of the development of the infra-renal segment of the vena cava, the *Nomina Embryologica*, describes the successive appearance, anastomosis and regression of three paired embryonic veins (posterior cardinal, subcardinal and supracardinal veins) between the 6th and 10th week of embryonic life [8]. First to appear are the posterior cardinal veins: all but their most distal portion regress and forms the iliac bifurcation. Next, the subcardinal veins form anteromedial to the posterior cardinal veins: the right subcardinal forms the suprarenal IVC while its left counterpart regresses. Lastly, the supracardinal veins develop dorsal to the subcardinal veins, with the right vein forming the infrarenal IVC while the left vein regresses [2,3].

Failure to regress of any of the three left venous counterparts are thought to be responsible for congenital abnormalities of the vena cava [9]. In the case of duplication of the IVC, the persistence of the left supracardinal vein is thought to be the cause [2,5]. The left IVC thus formed is a mirror image of the right receiving corresponding vessels: thus the ovarian vessels each joining the IVC on its own side. In our first case, as in most reports of duplicated IVC, the left IVC usually crosses over to join with its right counterpart at the level of the renal vein [10], although there have been incidences of it crossing at a lower level [11].

There have also been reported cases of the left IVC draining into the right IVC via a pre aortic trunk while the left renal veins empties into the left IVC at a lower level [12].

Our dissection also showed that apart from the left renal vein connecting the left vena cava to the right, another venous connection exist between the two IVCs but this time crossing behind the aorta and these have been previously thought to represent the anastomoses between the supracardinal veins [13]. The caliber of the two IVCs have also been the subject of many studies on this variation and there have been suggestions of classifying IVC duplication as per the diameter of each IVC and in our case, no significant difference in the diameters were recorded [12].

The importance of describing these congenital abnormalities lie in the clinical implications, especially when most of these variations are found at routine clinical visits [14]. It may create diagnostic problems where it may be misinterpreted radiologically as a saccular aortic aneurysm, aorto-lumbar lymphadenopathy, left pyeloureteric dilatation, retroperitoneal cysts or loops of small bowel [14,15], leading to unnecessary interventions and morbidity. For instance, there are reported cases of surgical exploration for presumed metastatic testicular carcinoma based on the CT findings of lymphadenopathy [16,17]. These can be avoided by the use of lower limb intravenous contrast injection and CT interpretation during venous phase, which allow better opacification of the IVC [18]. The use of magnetic resonance and digital subtraction angiography may also be considered [4].

In addition, the presence of a duplicated IVC may complicate retroperitoneal surgery as it can be misidentified as a lumbar vein or a variant of the internal spermatic vein [6]. Therefore, it is crucial to identify such congenital variations preoperatively to avoid iatrogenic injury or inadvertent ligation.

There have been reported cases of thromboembolic events in patients with duplicated IVC [19]. It is unclear whether congenital IVC variations predispose to thromboembolism. The exact mechanism is un-

known, although it has been suggested that venous stasis plays a role [20]. In patients with deep vein thrombosis necessitating caval interruption, it is paramount to identify such variations as an IVC filter needs to be inserted into both IVC to prevent recurrent pulmonary embolism [19].

CONCLUSION

Double inferior vena cava is an uncommon but clinically important congenital variation. The astute clinician needs to be aware of such malformation as it carries important diagnostic and therapeutic pitfalls.

Acknowledgements: The authors would like to thank Professor Chris Briggs and Dr Gerard Ahern for their valuable input in giving the final shape of this manuscript.

Conflicts of Interests: None

REFERENCES

- [1]. Zollinger J, Zollinger S (2011) Plate 4: anatomy of the abdominal aorta and inferior vena cava (monograph on internet). New York: Mc Graw Hill. Available from Access Surgery.
- [2]. Maxwell EW and Erwin GS. Four cases of anomalous inferior vena cava with an explanation of their developmental origin 1928;62:184-197.
- [3]. McClure ChFW, Butler EG. The development of the vena cava inferior in man. *Am J Anat* 1925;35:331-383.
- [4]. Evans JC, Earis J, Curtis J. Thrombosed double inferior vena cava mimicking paraaortic lymphadenopathy. *Br J Radiol* 2001;74: 192-4.
- [5]. Bass JE, Redwine MD, Kramer LA, Huynh PT, Harris JH. Spectrum of congenital anomalies of the inferior vena cava: cross-sectional imaging findings. *Radiographics* 2000;20:639-52.
- [6]. Shingleton WB, Hutton M, Resnick MI. Duplication of inferior vena cava: Its importance in retroperitoneal surgery. *Urology* 1994;43:113-5.
- [7]. Kapetanakis S, Papadopoulos C, Galani P, Dimitrakopoulou G, Fiska A. Anomalies of the inferior vena cava: a report of two cases and a short review of literature. *Folia Morphologica* 2010;69 (3):123-127.
- [8]. *Nomina anatomina*: approved by the eleventh International Congress of Anatomists at Mexico City, 1980 together with *Nomina Histologica*, Second edition and *Nomina Embryologica*, Second edition. Prepared by subcommittees of the International anatomical nomenclature committee 1983, n.p. Baltimore M.D. Williams and Wilkins, c1983, Harvard Library of Bibliographic dataset.
- [9]. Reagan FP, Robinson A. The later development of the inferior vena cava in man and in carcinoma. *J Anat* 1927;61:482-484.

- [10]. Pillari G, Wind ES, Wiener SL, Baron MG (1978) Left inferior vena cava. *AJR* 130:366 - 367
- [11]. Hirsch DM, Chan KF (1963) Bilateral inferior vena cava. *JAMA* 185:729 – 730.
- [12]. Natsis K, Apostolidis S, Noussios G, Papathanasiou E, Kyriazidou A, Vyzas V. Duplication of the inferior vena cava: anatomy, embryology and classification proposal. *Anat Sci Int* 2010;85:56-60
- [13]. Edwards EA. Clinical anatomy of lesser variations of the inferior vena cava; and proposal for classifying the anomalies of this vessel. *Angiology* 1951;2:85-99.
- [14]. Senecail B, Lefevre C, Person H, Meriot P. Radiologic anatomy of duplication of the inferior vena cava: a trap in abdominal imaging A report of 8 cases. *Surg Radiol Anat* 1987;9:151-7.
- [15]. Jasinski RW, Yang CF, Rubin JM. Vena cava anomalies simulating adenopathy on computed tomography. *J Comput Assist Tomogr* 1981;5:921-924.
- [16]. Cohen SI, Hochsztein P, Cambio J, Susset J. Duplicated inferior vena cava misinterpreted by computerized tomography as metastatic retroperitoneal testicular tumor. *J Urol* 1982;128:389-91.
- [17]. Klimbert I, Wajzman Z. Duplicated inferior vena cava simulating retroperitoneal lymphadenopathy in a patient with embryonal cell carcinoma of the testicle. *J Urol* 1986;136:678-79.
- [18]. Van breda A, Rubin BE, Druy E. Detection of inferior vena cava abnormalities by computed tomography. *J Comput assist tomogr* 1979;3(2):164–169.
- [19]. Kouroukis C, Leclerc JR. Pulmonary embolism with duplicated inferior vena cava. *Chest* 1996;109:1111-3.
- [20]. Milani C, Constantinou M, Berz D, Butera JN, Colvin GA. Left sided inferior vena cava duplication and venous thromboembolism: case report and review of literature. *J Hematol Oncol* 2008;1:24.

How to cite this article:

Z Y Loo, Jhummon-Mahadnac N. DOUBLE INFERIOR VENA CAVA: A RARE BUT IMPORTANT ANATOMICAL VARIATION. *Int J Anat Res* 2013;03:174-177.