

Original Research Article

## A Cadaveric study on Rectus Sternalis muscle and its clinical significance in Western part of Tamilnadu state (Kongunadu region)

Vijaianand M<sup>\*1</sup>, Sakthivel M<sup>2</sup>, Sheela Grace Jeevamani<sup>3</sup>, Geeta Anasuya D<sup>4</sup>.

<sup>\*1</sup> Associate Professor, Department of Anatomy, KMCH Institute of Health Sciences and Research, Coimbatore, Tamilnadu, India.

<sup>2</sup> Tutor, Department of Anatomy, KMCH Institute of Health Sciences and Research, Coimbatore, Tamilnadu, India.

<sup>3</sup> Professor and Head, Department of Anatomy, KMCH Institute of Health Sciences and Research, Coimbatore, Tamilnadu, India.

<sup>4</sup> Assistant Professor, Department of Anatomy, KMCH Institute of Health Sciences and Research, Coimbatore, Tamilnadu, India.

### ABSTRACT

**Background:** Rectus sternalis is considered as an unusual accessory or supernumerary muscle which appears either unilateral or bilateral in the anterior thoracic wall of human beings. It varies in length, breadth, thickness and incidence among different races and in both sexes. Regarding its origin and insertion still a clear conclusion has not been reached because some authors says it originates and ascends for insertion while some of them opines it originates and descends for insertion. Clinically, its presence also leads to false diagnosis such as Breast tumours, lipoma etc.

**Aim of the study:** To find out the presence of Rectus sternalis muscle in the anterior chest wall during routine dissection.

**Materials and Methods:** 37 well embalmed and preserved cadavers of both sexes which is used for routine dissection to Phase-I MBBS students were taken into consideration. The pectoral region on either side of sternum was dissected in layers and visualised for the presence of Rectus sternalis.

**Results:** Among 37 cadavers dissected, Rectus sternalis was found in the pectoral region of a male and a female cadaver. In male it appeared bilateral, whereas in female it is unilateral. In both the cases it lie superficial to pectoralis major.

**Conclusion:** The incidence of Rectus sternalis reported from our study was 5.4%. In the earlier days it lead to misdiagnosis and made great challenge to radiologists and surgeons, but now-a days with advancement in imaging techniques its presence can be detected clearly thus avoiding unnecessary expenditure and invitro techniques. Clinically it is also used as pedicle flap in breast reconstructive surgeries.

**KEY WORDS:** Cadaver, Dissection, Pectoral region, Rectus sternalis, sternocleidomastoid.

**Corresponding Author:** Dr. Vijaianand M, Associate Professor, Department of Anatomy, KMCH Institute of Health Sciences and Research, Coimbatore, Tamilnadu, India.

**E-Mail:** [dr.vijaitarun7474@gmail.com](mailto:dr.vijaitarun7474@gmail.com)

Access this Article online	Journal Information
<b>Quick Response code</b>  DOI: 10.16965/ijar.2021.114	<b>International Journal of Anatomy and Research</b> ISSN (E) 2321-4287   ISSN (P) 2321-8967 <a href="https://www.ijmhr.org/ijar.htm">https://www.ijmhr.org/ijar.htm</a> DOI-Prefix: <a href="https://dx.doi.org/10.16965/ijar">https://dx.doi.org/10.16965/ijar</a> 
	Article Information
	Received: 13 Feb 2021 Peer Review: 15 Feb 2021 Revised: None
	Accepted: 15 Mar 2021 Published (O): 15 Apr 2021 Published (P): 05 Jun 2021

### INTRODUCTION

Getting an unusual anatomical variation during routine dissection not only provokes

interest to anatomists, but also alarms the surgeons, radiologists and other medical personnel what function or dysfunction does

it may produce or how it appears on imaging studies and it mimics what. One such variation is Rectus sternalis which is an accessory or supernumerary muscle seen in the anterior chest wall on either side of the sternum overlying the Pectoralis major muscle. Rectus sternalis has been simply called Sternalis or Episternalis or Presternalis or Rectus thoracis and Superficial Rectus abdominis [1] Costa pointed out from his study [2] this muscle has been termed 'abdomino-cutaneous' by Klein; 'abdomino-guttural' by Duges; 'sternalis brutorum' by Kuhff and 'cutaneous pectoris' by Zenker. This muscle was first reported in 1604 by Cabrollius and its description was given in the year 1726 by Dupuy [3-6].

Rectus sternalis is found to be reported in both sexes, but more commonly in women, white-skinned individuals and its occurrence is mostly unilateral as compared to bilateral. Its length, breadth and thickness also varies with higher incidence being reported in Chinese and lower in Taiwanese [7]. Based on the origin, it has been called by various names such as Sternocleidomastoid, Pectoralis major, Rectus abdominis or a remnant of Panniculus carnosus [8]. Based on the innervation the authors opine that Rectus sternalis could be a part of Pectoralis major or a part of Rectus abdominis.

### MATERIALS AND METHODS

Based on the standard dissection techniques of Cunningham manual, 37 well embalmed cadavers which was preserved and stored in formalin tanks in the Department of Anatomy, Karpagam faculty of Medical Sciences and Research, Coimbatore, Tamilnadu, South India, were utilised for routine dissection classes to Phase I MBBS students. The study was carried over a period of 3 years and 6 months. The Pectoral region was dissected in layers, such that after reflection of skin and superficial fascia, muscular variation if any was observed carefully particularly in the parasternal region which was traced from its origin to insertion, its innervation was viewed, its length, breadth and thickness were measured using digital caliper / measuring scale and adequate photographs was taken.

### RESULTS

Out of 37 cadavers dissected (22 males and 15 females) all belonging to Indian origin, Rectus sternalis muscle was found to be present in two cadavers of which one was male and the other was female respectively.

**Case 1:** In the female cadaver aged around 45 years, a unilateral Rectus sternalis muscle on the Right Pectoral region was identified. It is fleshy in the middle and tendinous in the upper and lower parts. Its length, breadth and thickness measured was 11cm, 1.5cm (mid part of muscle) and 0.35cm respectively. It is parasternal in position, lying deep to the skin and superficial fascia but superficial to the pectoralis major and its covering fascia.

Inferiorly it arises by few tendinous slips from the aponeurosis of external oblique muscle and also from the fascia overlying the pectoralis major muscle at the level of right 5th and 6th costal cartilage. Then it passes upwards in a slightly oblique manner and at the level of right 2nd costal cartilage it becomes narrow and tendinous ascends vertically over the sternum and ends by blending with tendinous fibers of sternal head of Sternocleidomastoid muscle of both sides.

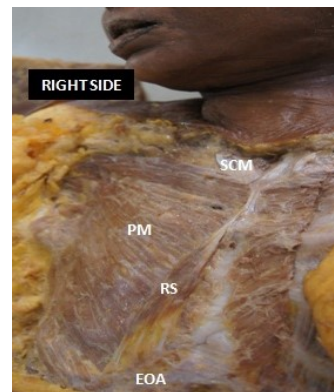


Fig. 1(A): Shows Unilateral Rectus sternalis in Right pectoral region of a female cadaver.

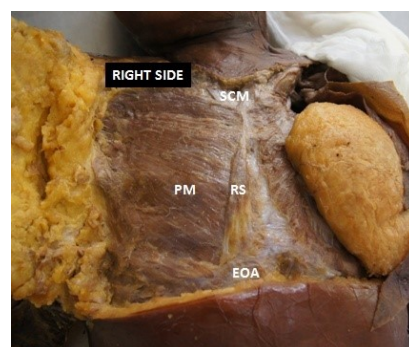



Fig. 1(B): Shows Unilateral Rectus sternalis in Right pectoral region of a female cadaver.

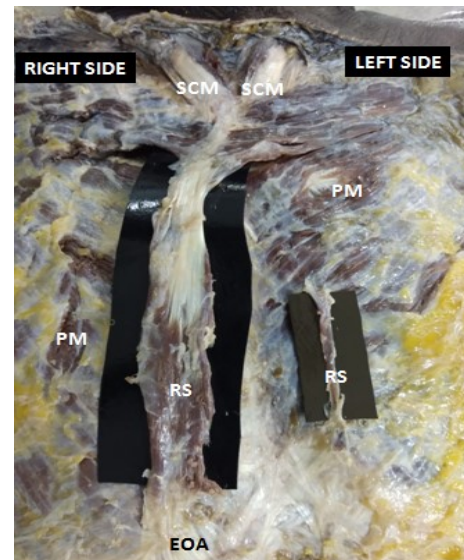
**Case 2:** In a well built male cadaver aged around 65 years, Rectus sternalis muscle was identified bilaterally in the pectoral region lying deep to the skin and superficial fascia but superficial to the pectoralis major muscle and its covering fascia.

On the left pectoral region, it appears as a thin narrow fleshy strip measuring about 4cm in length, 0.4cm in breadth and 0.2cm in thickness. Throughout its entire extent it appears fleshy and was of same breadth. Inferiorly it arises from the fascia overlying the pectoralis major muscle 1.5cm away from the left border of sternum at the level of left 5th costal cartilage and ascends vertically for about 3.5cm over the pectoralis major muscle, and ends superiorly by blending with the left pectoralis major muscle and its covering fascia at the level of left 3rd costal cartilage.

On the right side, the Rectus sternalis measured 17cm in length, 3cm in breadth and 0.6cm in thickness. Inferiorly it is fleshy, arising from the aponeurosis of external oblique muscle and pectoralis major and its covering fascia at the level of right 6th and 7th costal cartilage then runs vertically upwards in front of pectoralis major a little lateral to the right border of sternum and at the level of right 2nd costal cartilage it abruptly turns at an acute angle towards left and ends superiorly by blending with the clavicular fibers of pectoralis major and the sternal head of Sternocleidomastoid muscle of both sides.



**Fig. 2(A):** Shows Bilateral Rectus sternalis in a male cadaver.



**Fig. 2(B):** Shows Bilateral Rectus sternalis in a male cadaver

## DISCUSSION

Rectus sternalis is found to be reported in both sexes with an incidence of 8.7% in females and 6.4% in males [9]. It has been reported mostly as unilateral occurrence rather than bilateral. The incidence in blacks is 8.4% which is slightly higher than whites varying from 4-7%. Previous studies described a higher incidence in Chinese population with 23.5% and lowest in Taiwanese with 1%. Among Indian population the incidence varies from 4 -8% [10]. The incidence depends on sex, race and ethnicity such that in Europeans - 4.4%, Africans - 8.4% and Asians - 11.5%. It can be unilateral or bilateral with an average incidence rate of 3 - 6% [11]. An overall incidence of 0.69% among Indians has been reported during modified radical mastectomy. Pichler stated that the whole year in dissection hall got ended up without the occurrence of Rectus

sternalis [12]. Sarikcioglu from their studies reported the incidence of 3 Rectus sternalis muscle in a single cadaver of which one on Right pectoral region; two on Left pectoral region [13] whereas the study reported by Ramachandran Kalpana and Kothandaraman Usha 3 Rectus sternalis muscle was seen on the Right pectoral region [14]. In the present study, Rectus sternalis was found in both sexes with unilateral and bilateral occurrence and the incidence was 5.4% which nearly coincides with the study made by Nisha who reported unilateral and bilateral occurrence with an



incidence of 5% and Shah AC presented an incidence of 4 - 8% in indians. Ruge in 1905 reported Rectus sternalis in the subcutaneous part of the trunk which is considered vestige of cuticular muscle of mammals [15]. Clemente in 1985 described the misplaced portion of pectoralis major as sternalis [16]. Barlow stated it as a remnant of panniculus carnosus [17]. Sadler in 1995 explained that it arises at the ventral tips of hypomeres as a part of ventral longitudinal column muscle and its representative include infrahyoid muscle in the neck, Rectus abdominis in the abdomen while in the thoracic region it gets disappeared but occasionally present in the form of Rectus sternalis [18], this concept supported the fact that Rectus sternalis fibers are continuous with either Sternomastoid or Rectus abdominis or both. Hung made a concept that Rectus sternalis is formed from cleavage or unusual migration of pectoral muscle [19]. Snosek et al quoted from his studies that Bergman et al described Rectus sternalis is due to disturbance in normal process of development of pectoralis major that include variation similar like pectoralis minimus, pectoralis tertius, infraclavicularis, chondroepitrochlearis [20]. From the studies made by Harish, Gopinath, the separated fibers of pectoralis muscle form sternalis, this is supported by the evidence of innervation that pectoral nerve supplies both the muscles [11]. Cunningham declared that aberrant, displaced and rotated segment of pectoralis muscle mass form sternalis [21].

Some connections found to exist between sternalis and pectoralis major and these connections vary from small muscle fibers to large fascicles and that could have produced by partial or incomplete rotation of pectoralis major segments. These segments cannot fulfill pectoralis major and such segments if they get displaced and migrated from their normal position they can make connections with Rectus abdominis inferiorly or superiorly with sternocleidomastoid [22, 23]. Our study strongly agree with the above mentioned embryological aspects.

Regarding the origin and insertion of Rectus sternalis, various views are proposed by many authors. According to Jelev, this muscle arises

from sternum or infraclavicular region and gets inserted into rectus sheath, costal cartilage, lower ribs or external oblique aponeurosis, but Gray's Anatomy described this muscle originates from lower costal cartilages and rectus sheath undergoes an ascending course and ends by blending with sternocleidomastoid or gets attached to upper sternum or costal cartilages. Another view given by some authors are it originates from nearby muscles such as sternomastoid, pectoralis major, rectus abdominis and panniculus carnosus and this was supported by Novakov and his co-workers that Rectus sternalis gets originated from pectoralis major [24]. Amrutha et al from her case report said Rectus sternalis on both sides arise from external oblique aponeurosis and become continuous with sternocleidomastoid muscle [25]. Minnie pillay and Kumar Bhat from their studies concluded Rectus sternalis originated from pectoral fascia and external oblique aponeurosis and gets inserted into sternocleidomastoid [26].

In a study made by Nisha and Levent et al the Rectus sternalis muscle got inserted in sternocleidomastoid [27]. The present study follows Gray's anatomy and strongly agree with the studies made by Amrutha, Kumar Bhat and Minnie pillay as far as origin and insertion concerned.

Cunningham's emphasis and Kida et al from his studies expressed that very fine twigs arising from pectoral nerve and supplying sternalis muscle is very difficult to trace because it gets damaged or cut accidentally while clearly tracing the muscle or rather it may get confused with fascia. O'Neil and Folan-Curran concluded from their studies that external or internal thoracic nerves innervate the sternalis muscle in 55% cases, while intercostal nerves provide nerve supply in 43% cases and in remaining 2% cases it is supplied by both [28]. Harish and Gopinath, Shah, Jelev, Yap and Barlow pointed out sternalis receives its nerve supply accordingly from where it gets derived such that if it is from pectoralis major it is innervated by pectoral nerves or if it is from rectus abdominis it get its nerve supply from anterior cutaneous branches of intercostal nerve. Barlows quote according to literature

review made by 17 authors in over 147 cases of sternalis, 68.5% of sternalis is supplied by pectoral nerves, 26.7% by intercostal nerves and in remaining 4.8% is supplied by a combination of both [17]. Motabagani recorded that the arterial supply to Rectus sternalis is derived from perforating branches of internal mammary artery [29]. In our study we strongly abide with Cunningham and Kida et al that during fine dissection made on Rectus sternalis the nerve supplying the muscle may get damaged hence the focus regarding innervation and vascularisation was overlooked.

A strong association exist between sternalis muscle and anencephalic fetuses and further Eiscler from his investigation reported that this muscle is almost present in half of the anencephalic fetuses [30]. Harish and Gopinath contributed from their side, a coexistence occurs between the sternalis muscle and variations in kidney, suprarenal gland and testes. According to Pereira presence of Rectus sternalis mimic a large number clinical conditions such as abscess, lymphadenitis, lipoma, hematoma, breast tumours, herniation of pectoralis major [31] etc. Bailey and Khan suggested its presence could lead to asymmetry of chest or mammary gland with ipsilateral deviation of nipple and areola [32,33]. Glasser opine alterations in ECG may occur due to the presence of sternalis [34]. Schulman made an easy way to detect the presence of sternalis muscle, according to him keeping the elbow flexed and moving the arm towards the opposite anterior superior iliac spine causes tension of the muscle if present [35]. Bradley et al reported this muscle was identified in 4 out of 32,000 patients in approximate, who underwent screening procedures such as mammography [36].

## CONCLUSION

Previous studies reported its presence was also detected during surgical procedures such as mastectomy or breast reconstruction surgeries. But today with advancement in imaging techniques such as multidetector CT and MRI, presence of sternalis can be detected easily without any dilemma. Functional aspects of sternalis still remains obscure, but however based on the location and direction of muscle

fibers it acts as an accessory muscle of inspiration, participate in the movements of shoulder joint and helps in the elevation of lower chest wall [37]. It is used as flap in plastic and reconstructive surgeries involving head and neck, and also used to cover the prosthesis in augmentation mammoplasty [33].

**Conflicts of Interests: None**

## REFERENCES

- [1]. Kida MY, Izumi A, Tanaka S. Sternalis muscle topic for debate. *Clinical Anatomy*. 2000;13(2):13-140.
- [2]. Costa VB: O musculo Pre-esternal. *Dissertacao de Doutorado*. Lisboa; 1950:524.
- [3]. Kumar MRB, Bhagath KP, Siddaraju G. Sternalis muscle revisited in South Indian male cadaver: a case report. *Cases Journal*. 2009;2:63-8.
- [4]. Arraez-Aybar LA, Sobrao Perez J, Merida-velasco JR. Left musculus sternalis. *Clinical Anatomy*. 2003;16(4):350-354.
- [5]. Deepali UK, Umesh KK. Unilateral rectus sternalis muscle- A Case report. *AL Ameen Journal of Medical sciences*. 2010;3(2):169-171.
- [6]. Loukas M, Bowers M, Hullett J. Sternalis muscle: a mystery still. *Folia Morphologica*. 2004;63(2):147-49.
- [7]. Bergman RA, Thompson SA, Afifi AK, Saadeh FA. *Compendium of human anatomic variation: text, atlas, and world literature* Munich: Urban and Schwarzenberg; 1982;7.
- [8]. SAEED, M., MURSHID, KR; RUFAL, AA., ELSAYED, SE. and SADIQ, MS. An anatomic variant of chest wall musculature. *Saudi Med Journal*. 2002;23(10).
- [9]. Scott-Conner CE, Al-Jurf AS: The sternalis muscle. *Clin Anat* 2002;15:67-69.
- [10]. Marious: Sternalis muscle; a mystery still. *Folia Morphol*. 2003;63(2):147-149.
- [11]. Harish K, Gopinath KS. Sternalis muscle: Importance in surgery of the breast. *Surg Radiol Anat* 2003;25:311-314.
- [12]. Pichler K: Ueber das Vorkommen des M. sternalis. *Nach Untersuchungen am Lebenden*. *Anat Anzeig* 1911;39:155-160.
- [13]. Sarikcioglu L, Demirel BM, Ocuç N, Ucar Y. Three sternalis muscles associated with abnormal attachments of the pectoralis major muscle. *I J Exp Clin Anat*. [Internet]. 2008;2:67-71.
- [14]. Ramachandran Kalpana, Kothandaraman Usha. Three Unilateral recti sternalis muscles-an unusual variation and its clinical significance. *Eur J Anat* 2010;14(1):99-103.
- [15]. Ruge G, Der Hautrumpfmuskel, dersaugetiere, der M. sternalis und der Achselbogen des Menschen. *Morph Jahrb* 1905;33:379-531.
- [16]. Cemente CD. In: *Gray's anatomy*. 30<sup>th</sup> Edition Lea and Febiger. Philadelphia, 1985, PP.520.
- [17]. Barlow RN. The sternalis muscle in American Whites and Negroes. *Anat Record* 1934; 61:413-426. doi:10.1002/ar1090610405.

- [18]. Sadler T. Langman's Medical Embryology. 11<sup>th</sup> Ed, Maryand, Lippincott Williams and Wilkins. 2010; 143-149.
- [19]. Hung LY, Lucaciu OC. Viewpoint: The Embryological Development of Sternalis Muscle and Implications for Trigger Point Pain. UTMJ 2012; 90(2); 24-7.
- [20]. Snosek M, Tubbs SR, Loukas M. Sternalis muscle. What every anatomist and clinician should know. Clinical Anatomy. 2014; 27: 866-84.
- [21]. Cunningham, D.J. The musculus sternalis. J. Anat. Physiol., 22(3): 390.1-407, 1888.
- [22]. Jelev L, Georgiev G, Surchev L. The sternalis muscle in the Bulgarian population: Classification of sternales. J Anat. 2001; 199: 359-63.
- [23]. Turner WM. On the musculus sternalis. J Anat Physiol. 1867; 1: 246-53.
- [24]. Novakov SS, Yotova NI, Petleshkova TD, Muletarov SM. Sternalis muscle- a riddle that still awaits an answer short communication. Folia Med (Plovdiv) 2008; 50(2): 6-66.
- [25]. Amrutha K V, Joseph Abraham, Admasu Arsicha, Teshome Belachew, Assefa Hamato. International Journal of Research and Review. 2018; 5(5).
- [26]. Minnie Pillay, Swapna Ramakrishnan and Mahendran Mayilswamy. Two cases of Rectus Sternalis Muscle. 10.7860/JCDR/2016/17196.7023
- [27]. Nisha D. Parmar, Deepa S. Gupta. A STUDY OF MORPHOLOGICAL VARIATION OF PECTORAL REGION MUSCLE 'RECTUS STERNALIS' IN SOUTH GUJARAT REGION. Int J Anat Res 2016; 4(2): 2423-28. ISSN 2321-4287.
- [28]. O'Neill MN, Folan-Curran J: Case report : bilateral sternalis muscles with a bilateral pectoralis major anomaly. J Anat 1998; 193: 289-292.
- [29]. Motabagani MA, Sonalia A, Abdel-Meguid E, Bakheit MA. Morphological study of the uncommon rectus sterni muscle in German cadaver. East African medical journal. 2004; 81(3): 130-133.
- [30]. Eisler noted by Schaeffert (1942) Morris Human Anatomy 10<sup>th</sup> edition. The Blackiston Company, Philadelphia. p. 437.
- [31]. Pereira BDV, Tavares AS: Sobre um caso de coexistencia do musculo pre-esternal e de arco axillar muscular. Clinico Contemporanea 1946; 9: 526-528.
- [32]. Bailey PM, Tzarnas CD: The sternalis muscle: a normal finding encountered during breast surgery. Plast Reconstr Surg 1999; 103: 1189-1190.
- [33]. Khan UD: Use of the rectus sternalis in augmentation mammoplasty: case report and literature search. Aesthetic Plast Surg 2008; 32: 21-24.
- [34]. Glasser SP: Electrocardiogram of the month. J Louisiana State M Soc 1975; 127: 136-150.
- [35]. Schulman MR, Chun JK. The conjoined sternalis-pectoralis muscle flap in immediate tissue expander reconstruction after mastectomy. Ann Plast Surg. 2005; 55: 872-875.
- [36]. Bradley FM, Hoover HC, Hulka CA, Whitman GJ, McCarthy KA, Hall DA et al. The sternalis muscle: An unusual normal finding seen on mammography. American journal of Roentgenology. 1996; 166(1): 33-36.
- [37]. Young LB, Young BJ. The sternalis muscles: its incidence and imaging finding on MDCT. J Thoracic Imaging, 2006; 21: 179-83.

#### How to cite this article:

Vijaianand M, Sakthivel M, Sheela Grace Jeevamani, Geeta Anasuya D. A Cadaveric study on Rectus Sternalis muscle and its clinical significance in Western part of Tamilnadu state (Kongunadu region). Int J Anat Res 2021; 9(2.1): 7942-7947. DOI: 10.16965/ijar.2021.114