

## Incidence of supratrochlear foramen of humerus

Kalpna Thounaojam<sup>1</sup>, Renuca Karam<sup>\*1</sup>, Gurumayum Tarunkumar Sharma<sup>2</sup>.

<sup>\*1</sup> Associate Professor, Department of Anatomy, Jawaharlal Nehru Institute of Medical Sciences, Porompat, Imphal, Manipur, India.

<sup>2</sup> Demonstrator, Department of Anatomy, Jawaharlal Nehru Institute of Medical Sciences, Porompat, Imphal, Manipur, India.

### ABSTRACT

**Introduction:** The supratrochlear foramen of humerus is a small hole located above the trochlea of humerus. The supratrochlear foramen was first described by Meckel in 1825. The knowledge of the presence of supratrochlear foramen in the humerus is important for preoperative planning and management of supracondylar fractures and the interpretation of the abnormalities in the radiographs.

**Materials and Methods:** The study was conducted in Jawaharlal Nehru Institute of Medical Sciences, Imphal. 60 dry humerus were studied. The parameters of the supratrochlear foramen of humerus. Supratrochlear foramen were measured with digital vernier caliper. The supratrochlear foramen observed were photographed.

**Result and conclusion:** The supratrochlear foramen was observed in 5 humerus. The supratrochlear foramen so observed were all on the left side. The incidence of supratrochlear foramen according to our present study is 8.33%. Two of the supratrochlear foramen observed were circular in shape. Another two were oval in shape. The fifth one was a slit. The present study may help the researchers in comparing the incidences of supratrochlear foramen of humerus.

**KEY WORDS:** Humerus, Supratrochlear foramen of humerus.

**Corresponding Author:** Dr Renuca Karam, Associate Professor, Department of Anatomy, Jawaharlal Nehru Institute of Medical Sciences, Porompat, Imphal, Manipur, India.

**E-Mail:** [kalpanathounaojam@yahoo.co.in](mailto:kalpanathounaojam@yahoo.co.in)

Access this Article online	Journal Information
<b>Quick Response code</b>  DOI: 10.16965/ijar.2020.247	<b>International Journal of Anatomy and Research</b> ISSN (E) 2321-4287   ISSN (P) 2321-8967 <a href="https://www.ijmhr.org/ijar.htm">https://www.ijmhr.org/ijar.htm</a> DOI-Prefix: <a href="https://dx.doi.org/10.16965/ijar">https://dx.doi.org/10.16965/ijar</a> 
	Article Information
	Received: 07 Dec 2020 Peer Review: 08 Dec 2020 Revised: None
	Accepted: 29 Dec 2020 Published (O): 30 Jan 2021 Published (P): 05 Mar 2021

### INTRODUCTION

The humerus is the longest and largest bone of the upper limb. It has expanded ends and a shaft. The olecranon fossa is a deep hollow on the posterior surface of the condyle, immediately above the trochlea, that lodges the tip of the olecranon of the ulna when the elbow is extended. The floor of the fossa is always thin and may be partially deficient [1].

A thin plate of compact bone known as supratrochlear septum, which is lined by a synovial membrane, usually separates the olecranon

fossa and coronoid fossa in the supratrochlear area of the distal part of the humerus [2].

The supratrochlear foramen of humerus is a small hole located above the trochlea of humerus. The supratrochlear foramen was first described by Meckel in 1825 [3].

It is the aperture that forms when the septum separating the coronoid and olecranon fossa is perforated [4]. The term septal aperture defines an oval or round shaped bony defect of the septum that separates the olecranon from the coronoid fossa of the humerus.

It is of significance for surgeons because it may alter the fracture pattern at the region and thus their management[5].The knowledge of the presence of supratrochlear foramen in the humerus is important for preoperative planning and management of supracondylar fractures and the interpretation of the abnormalities in the radiographs[6].

**MATERIALS AND METHODS**

The study was conducted in Jawaharlal Nehru Institute of Medical Sciences, Imphal. 60 dry humerus were studied. Sex was not considered as a criterion for the study. 30 humerus were of left side and the remaining 30 were of right side. The parameters of the supratrochlear foramen were measured with digital vernier caliper (Fig 1). The supratrochlear foramen observed were photographed.

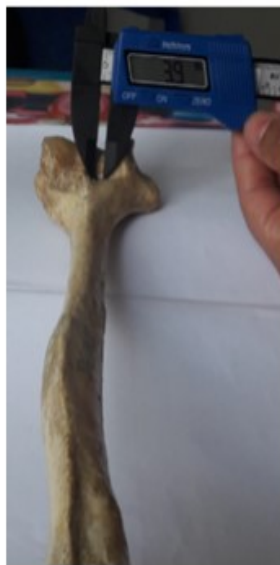

Figure 1

**RESULTS**

The supratrochlear foramen was studied in 60 dry humerus. Sex of the bone was unknown. The supratrochlear foramen was observed in 5 humerus. The supratrochlear foramen so observed were all on the left side. The incidence of supratrochlear foramen according to our present study is 8.33%. Two of the supratrochlear foramen observed were circular in shape (Figure 3 and 5). Another two were oval in shape (Figure 2 and 6). The fifth one was a slit (Figure 4). The parameters of the present study is shown in Table 1.

**Table 1:** Showing the supratrochlear foramen various shapes and its vertical and transverse diameters.

S. no.	Shape of the supratrochlear foramen	Vertical diameter	Transverse diameter
1	Oval(Figure 2)	1.7 mm	3.9 mm
2	Circular(Figure 3)	1.9mm	1.8mm
3	Slit (Figure 4)	0.9 mm	2.7mm
4	Circular(Figure 5)	1.5mm	1.5mm
5	Oval(Figure 6)	2.3 mm	3.2 mm

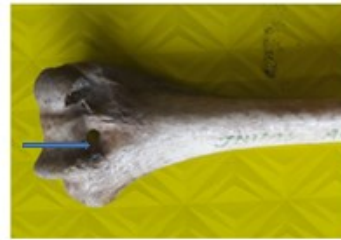


Figure 2



Figure 3



Figure 4



Figure 5

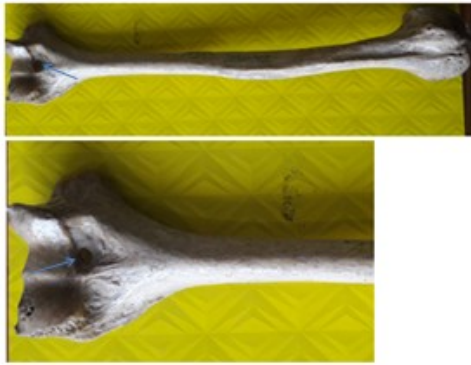


Figure 6

## DISCUSSION

The supratrochlear foramen is of great interest to anthropologists, who claim it as important in establishing relationships between humans and lower animals [7]. The knowledge of the presence of supratrochlear foramen in the humerus is important for preoperative planning and management of supracondylar fractures and the interpretation of the abnormalities in the radiographs [6].

It has been noted by Hirsh in 1972 that the septum is intact and lined by synovial membrane until the age of 7 years [8]. Perforations if any occur only after such time [9].

No anatomical structure is known to pass through the supratrochlear foramen [10]. The commonest shape noted was oval [10]. In our study circular and oval supratrochlear foramen showed equal incidence. The foramina of the right side were found to be larger, regardless of shape [10]. In our study, the supratrochlear foramen was observed on left side only which is very much contradictory to the above study.

Supratrochlear foramen of humerus appears relatively radiolucent and may commonly be confused with osteolytic or cystic lesion [11]. Supratrochlear foramen can alter the line of fracture as it is linked with a small medullary canal, which can modify our decision of point of entry of the nail in the medullary nailing procedure [12]. An increase in hyperextension was found in association with a bilateral supratrochlear foramen in a child [13].

Individuals with STF are prone to supracondylar humeral fractures, which might include unusual fracture patterns and necessity of an X-ray before and after surgery [14]. Research

has shown that the humerus is not perforated during the embryonic development phase and typically develops in adolescence or adulthood [15].

## CONCLUSION

There are many studies on supratrochlear foramen of humerus. The present study might help the researchers in comparing the incidences of supratrochlear foramen of humerus. The incidence of supratrochlear foramen according to our present study is 8.33%. The supratrochlear foramen so observed was all on the left side only. This study will not only be useful to Anatomists only, but also to Radiologists and Orthopaedic surgeons.

**Conflicts of Interests: None**

## REFERENCES

- [1]. Standing S, Leela CB. Elbow and forearm. Gray's Anatomy. The Anatomical basis of clinical practice. 41st edition. London: Churchill Livingstone Elsevier, 2016; 839.
- [2]. Bhanu PS, Sankar KD. Anatomical note of supratrochlear foramen of humerus in south coastal population of Andhra Pradesh. Narayana Medical Journal. 2012;1(2):28–34.
- [3]. Diwan RK, Rani A, Chopra J, et al. Incidence of Supratrochlear foramen of Humerus in North Indian Population. Biomedical Research. 2013;24(1):142–45.
- [4]. Ndou R, Smith P, Gemell R, Mohatla O. The supratrochlear foramen of the humerus in a South African dry bone sample. Clin Anat. 2013;26(7):870–4.
- [5]. Paraskevas GK<sup>1</sup>, Natsis K, Anastasopoulos N, Ioannidis O, Kitsoulis P. Humeral septal aperture associated with supracondylar process: a case report and review of the literature. Ital J Anat Embryol. 2012;117(3):135–41.
- [6]. Anuradha M. Morphological study of supratrochlear foramen of humerus. University Journal of Pre and Para Clinical Sciences 2019;5(8).
- [7]. Kate BR, Dubey PN. A note on the septal apertures in the humerus of Central Indians. Eastern Anthropol. 1970;33:105–10.
- [8]. Asha Joselet Mathew, Geetha Sulochana Gopidas, Tintu Thottiyil Sukumaran. A Study of the Supratrochlear Foramen of the Humerus: Anatomical and Clinical Perspective. J Clin Diagn. Res. 2016;10(2):AC05–AC08.
- [9]. Hirsh IS. The supratrochlear foramen: clinical and anthropological considerations. Am J Surg. 1927;2:500–05.

- [10]. Asha Joselet Mathew, Geetha Sulochana Gopidas, Tintu Thottiyil Sukumaran A Study of the Supratrochlear Foramen of the Humerus: Anatomical and Clinical Perspective J Clin Diagn Res. 2016;10(2):AC05–AC08.
- [11]. De Wilde V, De Maeseneer M, Lenchik L, Van Roy P, Beeckman P, Osteaux M. Normal osseous variants presenting as cystic or lucent areas on radiography and CT imaging: a pictorial overview. Eur J Radiol. 2004;51(1):77–84.
- [12]. Soni S, Verma M, Ghulyani T, Saxena A. Supratrochlear foramen: An incidental finding in the foothills of Himalayas. OA Case Reports 2013;2(8):75.
- [13]. I. Seth Hersh MD. The Supratrochlear foramen: Clinical and anthropological considerations. The American Journal of Surgery. 1927;2(5):500-505.
- [14]. D.T. Sahajpal, D. Pichora . Septal aperture: an anatomic variant predisposing to bilateral low-energy fractures of the distal humerus. Can. J. Surg. 2006;49:363-364.
- [15]. S. Mays. Septal aperture of the humerus in a mediaeval human skeletal population Am. J. Phys. Anthropol. 2008;136:432-440.

**How to cite this article:**

Kalpna Thounaojam, Renuca Karam, Gurumayum Tarunkumar Sharma. Incidence of supratrochlear foramen of humerus. Int J Anat Res 2021;9(1.1):7865-7868. DOI: 10.16965/ijar.2020.247