International Journal of Anatomy and Research,
Int J Anat Res 2020, Vol 8(4.2):7829-34. ISSN 2321-4287
DOI: https://dx.doi.org/10.16965/ijar.2020.238

Case Report

SUPRADIAPHRAGMATIC ORIGIN OF RIGHT RENAL ARTERY FROM THORACIC AORTA: CASE REPORT AND LITERATURE REVIEW

Rameshbabu CS *[1], Kumar A [2], Gupta OP [3], Sharma Y [4].

*[1] Associate Professor of Anatomy, Muzaffarnagar Medical College, N.H-58, Opp. Begrajpur Industrial Area, Muzaffarnagar. (U.P) 251203 India.

[2] Dr. O.P. Gupta Imaging Centre, Bachcha Park, Meerut- 250001, (U.P), India.

[3] Senior Consultant Radiologist, Dr. O.P. Gupta Imaging Centre, Bachcha Park, Meerut, (U.P), India.

[4] Yashika Sharma, BRDIT, Dr. O.P. Gupta Imaging Centre, Bachcha Park, Meerut, (U.P), India.

ABSTRACT

Numerical anomalies of renal arteries are frequently encountered at radiological investigations. Origin of main renal artery from abdominal aorta above the level of origin of celiac trunk and supplying normally positioned kidney is encountered occasionally. But ectopic supradiaphragmatic thoracic origin of main renal artery supplying a normally positioned kidney is extremely rare and reported only as case reports and till recently only ten such cases have been reported. Incidentally all cases reporting thoracic origin are right renal arteries. The present case report is an incidental observation of origin of main right renal artery from thoracic aorta at the level of upper part of body of T-12 vertebra in a male patient undergoing contrast enhanced CT for suspected lung pathology. The normally positioned right kidney was supplied by an accessory renal artery arising just below the level of origin of superior mesenteric artery. Our literature search has yielded 23 cases (excluding the present case) out of which 19 were thoracic right renal arteries and 4 thoracic left renal arteries. Additionally the present case was associated with the presence of variations of celiac and superior mesenteric arteries in the form of gastrosplenic and hepatomesenteric trunks. This association of variant gastrosplenic and hepatomesenteric trunks with thoracic origin of main renal artery is reported for the first time. Knowledge of such rare variations is crucial for radiologists, surgeons and urologists for better outcome of surgical and interventional procedures.

KEY WORDS: Thoracic renal artery, Supradiaphragmatic renal artery, Ectopic renal artery origin, Hepatomesenteric trunk, Gastrosplenic trunk.

Corresponding Author: C.S. Ramesh Babu, Associate Professor of Anatomy, Muzaffarnagar Medical College, N.H. 58, Opp. Begrajpur Industrial Area, Muzaffarnagar- 251203. India. Mobile: +91- 9897249202. **E-Mail:** csrameshb@gmail.com

Access this Article online	Journal Information
Quick Response code	**International Journal of Anatomy and Research** ISSN (E) 2321-4287 | ISSN (P) 2321-8967 **https://www.ijmhr.org/ijar.htm** **DOI-Prefix:** https://dx.doi.org/10.16965/ijar
DOI: 10.16965/ijar.2020.238	**Article Information** Received: 19 Oct 2020 Accepted: 13 Nov 2020 Peer Review: 20 Oct 2020 Published (O): 05 Dec 2020 Revised: None Published (P): 05 Dec 2020

INTRODUCTION

Renal arteries are paired lateral branches of abdominal aorta normally arising at the level of intervertebral disc between L1- L2 vertebrae just below the origin of superior mesenteric artery, but the level of origin can vary between upper border of L-1 and lower border of L-2 vertebra [1]. The most commonly reported variations of the renal arteries are early prehilar division and presence of additional renal arteries. Additional renal arteries are more common on the right side [1]. Additional renal arteries may arise from abdominal aorta at any level between T-12 and L-4 vertebrae

or its branches like iliac, inferior mesenteric, celiac, lumbar and gonadal arteries [2]. Ectopic origin of main renal artery or additional renal artery from thoracic aorta supplying a normally positioned kidney is extremely rare and the first case was reported by Doppman in 1967 [3]. Ichikawa et al (2014) reviewing earlier literature found 7 cases of ectopic thoracic origin of right renal artery [4]. Matusz et al (2015), after an extensive literature search, described 12 reports (14 cases in total) of single renal artery ectopically originating from abdominal aorta (4 cases), thoracic aorta (8 cases) and celiac trunk (2 cases) supplying a normally positioned kidney. All 8 cases of ectopic origin of renal arteries from thoracic aorta are right renal arteries [5]. Recently Ishida et al (2016) have claimed that renal artery origin from thoracic aorta has been sporadically reported as ten case reports in the literature including their case and all the thoracic renal arteries were found on the right side [6]. They also noted the presence of additional renal arteries arising from abdominal aorta along with ectopic thoracic origin of main renal artery in four previous reports [6].

Though thoracic origin of renal artery is very rare, its presence increases the risk of iatrogenic injury during thoracic endovascular and surgical procedures. Thorough knowledge of renal vascular variations and proper preoperative planning helps to reduce complications of laparoscopic and / or retroperitoneal surgeries. We describe here an incidental finding of supra-diaphragmatic origin of right renal artery from thoracic aorta in a male patient.

CASE REPORT

A 60 year old male patient was referred to our diagnostic centre for contrast enhanced computed tomography (CECT) of chest for suspected lung pathology. Before contrast injection written informed consent was obtained from the patient. He underwent CECT of chest and upper abdomen by a 64 channel multi-detector scanner ((GE Optima 660, 2011, Tokyo, Japan) and received 90-100 mL of non-ionic iohexol contrast (Omnipaque 350 mg I/mL; GE Healthcare, Shanghai, China)at the rate of 5 mL/s intravenously and was diagnosed of having interstitial lung disease. An incidental finding of origin of main right renal artery (MRRA) from descending thoracic aorta was noted arising 18.2 mm above the origin of celiac trunk at the level of upper third of body of T-12 vertebra (Figure No. 1, 3-A). The MRRA originating in the retrocrural space courses laterally and then downwards piercing the right crus of diaphragm to enter the abdomen and measured 69.3 mm in length (Figure No. 2). The MRRA presented a gentle S- shaped curvature before reaching the renal hilum. The normally positioned right kidney was also receiving an accessory renal artery (ARRA) arising from the anterolateral aspect of abdominal aorta 16.0 mm below the origin of celiac trunk (Figure No.1). The left kidney was supplied by a single left renal artery arising 16.4 mm below the origin of celiac trunk. Anomalous branching pattern of the celiac trunk and superior mesenteric artery was also observed. The celiac trunk branched into splenic (SA) and left gastric arteries (LGA) only (Gastrosplenic trunk- GST) and a replaced common hepatic artery (CHA) was arising from the superior mesenteric artery (SMA) (the Hepatomesenteric trunk- HMT) (Figure No. 3-B, 4). Right inferior phrenic artery (RIPA) was taking origin from the anterior and left surface of abdominal aorta, close to theorigin of gastrosplenic trunk and then crosses in front of the aorta to reach the right side (Fig.4).

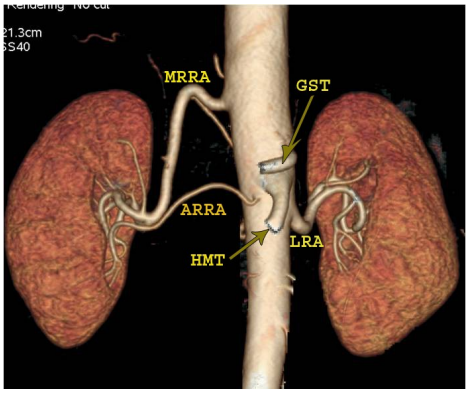

Fig. 1: Volume rendered image showing normally positioned kidneys and the normal origin of a single Left renal artery (LRA) from abdominal aorta. The right kidney is supplied by the main right renal artery (MRRA) arising from the thoracic aorta and exhibiting a long, gentle S- shaped course to reach the hilum. An accessory right renal artery (ARRA) is also seen entering the hilum. Celiac trunk and superior mesenteric artery showed variations in the form of gastrosplenic trunk (GST) and hepatomesenteric trunk (HMT).

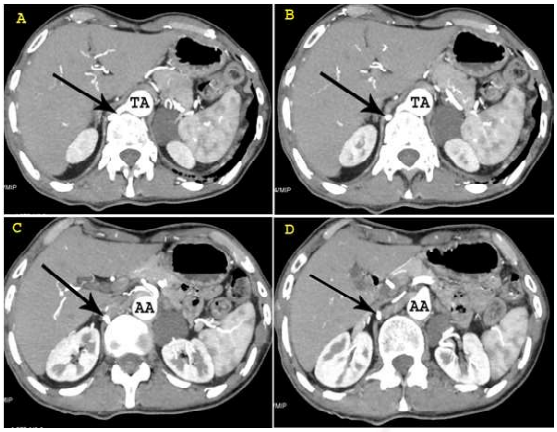

Fig. 2: A, B, C, D – Serial axial sections showing the origin of right renal artery (arrow) from thoracic aorta (TA) in the retrocrural space and piercing the right crus to enter the abdomen. AA – Abdominal aorta.

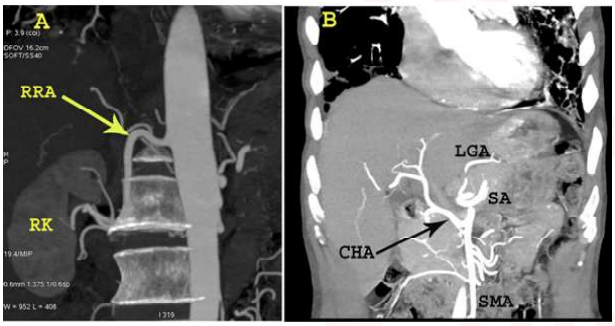

Fig. 3: (A) Coronal section showing the S- shaped course of right renal artery (RRA) supplying the right kidney (RK)
(B) Coronal section showing the gastrosplenic trunk dividing into left gastric artery (LGA) and splenic artery (SA). Note the origin of replaced common hepatic artery (CHA) from the superior mesenteric artery (SMA) forming the hepatomesenteric trunk.

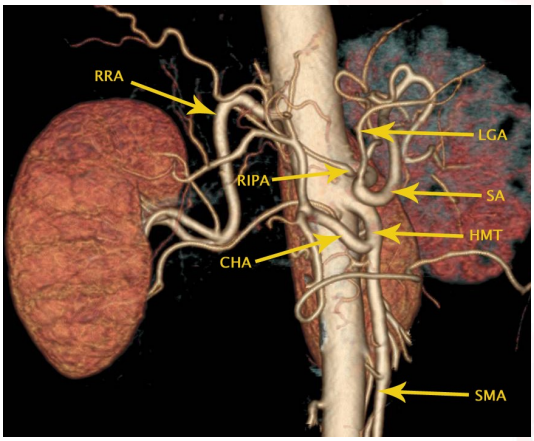

Fig. 4: Right lateral view of volume rendered image showing high origin of right renal artery (RRA) from thoracic aorta. In place of celiac trunk the gastrosplenic trunk is dividing into left gastric (LGA) and splenic arteries (SA). The common hepatic artery (CHA) is branching off the superior mesenteric (SMA), both forming a common trunk named hepatomesenteric trunk (HMT). The right inferior phrenic artery (RIPA) is arising from the front of abdominal aorta close to the origin of gastrosplenic trunk and is crossing anterior to the aorta.

DISCUSSION

Ectopic origin of main or accessory renal artery from thoracic aorta supplying a normally positioned kidney is an uncommon vascular anomaly sporadically reported in the literature, mainly as case reports. Such an artery is called as supradiaphragmatic renal artery or thoracic renal artery and obviously pierces the diaphragm to reach the renal hilum [7]. This variant needs to be distinguished from ectopic high origin of renal artery from abdominal aorta above the level of the celiac trunk and opposite to the level of T-11 or T-12 vertebral bodies [8]. After an extensive literature search Ishida et al (2016) found ten case reports including their own describing thoracic origin of renal artery and incidentally all cases were thoracic right renal arteries [6].

Our literature search yielded 22 studies including our own, reporting 24 cases of supradiaphragmatic thoracic origin of renal arteries with 20 on the right and 4 on the left side [Table-1]. In 5 out of these 24 cases, additional renal arteries arising from abdominal aorta were found to supply the normally positioned right kidney. Increased detection of supradiaphragmatic thoracic origin of renal arteries in the recent past is attributed to wider usage of contrast enhanced CT imaging techniques for screening of thoraco-abdominal pathologies. Analysing two cases of single ectopic right renal arteries, Gadabanahalli and Bhat (2017) noted that these cases may be associated with anomalous origin and course of right inferior phrenic artery crossing the abdominal aorta anteriorly from left to right. [22] We have also observed in our case, a similar course of right inferior phrenic artery passing anterior to abdominal aorta (Figure - 4).

In addition we have noted the presence of a gastrosplenic trunk (common trunk of origin of splenic and left gastric arteries) and hepatomesenteric trunk (origin of common hepatic artery from superior mesenteric), variations involving both celiac trunk and superior mesenteric artery. Such an association is reported for the first time with the thoracic origin of right renal artery. Recent systematic reviews by Panagouli et al (2013)

Table 1: Features of reported cases of renal artery origin from thoracic aorta.

Sl. No.	Author & Year	Gender, Age	Modality of investigation	Number of thoracic renal arteries	Right/Left	Vertebral level of origin	Associated lesions / anomalies, if any.
1	Doppman, 1967 [3]	---	Aortogram	1	Right	T-11	---
2	Tegtmeyer & Stanton. 1969 [9]	F 40	Aortogram IV Urography	1	Right	T-11	Agenesis of left kidney
3	Cerny & Karsch, 1973 [10]	M 55	Aortogram	1	Right	T-11	Right renal artery aneurysm
4	Schaffer et al. 1981 [11]	F 31	-----	1 (2)*	Right	T-11	
5	Uchino et al 1983 [12]	F 76	-----	1 (2)*	Right	T-10 - T-11	
6	van Baalen & van Bockel, 1994 [13]	F 38	Angiography	1	Right	T-11	Fibrodysplastic disease of both RAs multiple stenoses,
7	Cocheteux et al 2001` [14]	---	Helical CT angiography	2 (2 /1389)	Right	T-11	
8	Sueyoshi et al 2009 [15]	M 35	CT Angio	1	Right	T-12 upper border	
9	Hazirolan et al 2011 [2]	---	CT Angio	1	Right	T-11	
10	Talovic & Voljevica 2013 [16]	Fetus	Dissection	1 (3)*	Right	T-11	
11	Ichikawa et al 2014 [4]	M 38	CT Angio	1 (2)*	Right	T-11	
12	Delasotta et al 2015 [17]	M 73	Helical CT angio	1	Right	T-10	
13	Matusz et al 2015 [5]	M 72	MDCT Angio	1	Right	T-12 upper third	Right renal artery stenosis
14	Hatem & Gray 2015 [7]	M 74	CT Angio	1	Right	T-12 upper third	
15	Ishida et al 2016 [6]	M 37	CE CT	1	Right	T-11	
16	Arazinska et al 2016 [18]	F 30	MDCT	1	Left	T-12 upper third	Compression of left renal artery by median arcuate ligament.
17	Stinson et al 2016 [19]	M 74	CT Angio	1	Left	T-12	
18	Saddoud et al 2017 [20]	F 62	MDCT	1	Left	T-11	Celiac trunk origin from thoracic aorta T11-T12
19	Ashalatha et al 2017 [21]	--	Cadaveric	1	Left	T -11	
20	Gadabanahalli & Bhat-2017 [22]	M 40	CECT	1	Right	T10 - T11	
		F 28		1	Right	T-11	
21	Rossi & Rolandi,2019 [23]	M 69	MDCT	1	Right	T-12	Infrarenal abdominal aortic aneurysm
22	Ramesh Babu et al (Present study)	M 60	MDCT	1 (2)*	Right	T-12 upper third	Interstitial lung disease (ILD) Hepatomesenteric & gastro-splenic trunks.

*Indicates presence of additional renal artery arising from abdominal aorta. The number in parenthesis denotes total number of renal arteries.

estimated the prevalence of these two trunks as 1.13 % (111 cases out of 9829) and by Whitley et al (2020) as 2.17 % (378 cases out of 17391) [24, 25]. A radiological study involving 5002 patients reported the incidence as 2.64 %. [26]. It is suggested that the presence of both these trunks is one of the common branching pattern variations of celiac trunk and superior mesenteric artery [27, 28].

Renal arteries develop from lateral mesonephric arteries arising from the dorsal aorta. Nine pairs of lateral mesonephric arteries develop in the thoracolumbar region supplying mesonephros, metanephros, suprarenal glands and gonads. These mesonephric arteries are grouped into three sets, cranial (1st and 2nd pair), middle (3rd to 5th pair) and caudal (6th to 9th pair). The caudal set of mesonephric arteries form an arterial network named rete arteriosum urogenitale which supplies metanephros. Renal artery develops from the lower most mesonephric artery of the middle group or upper most mesonephric artery of the caudal group. Mesonephric arteries of the middle group also develop into middle suprarenal and inferior phrenic arteries. One of the caudal mesonephric artery gives rise to gonadal artery and the rest degenerate. Persistence of caudal mesonephric arteries give rise to additional (accessory) renal arteries. Cranial set of mesonephric arteries completely disappear. Likely explanation for the thoracic origin of renal artery is the persistence of one of the cranial set of lateral

mesonephric arteries [17].

Though extremely rare, presence of thoracic origin of renal artery would result in complications while performing thoracic mediastinal surgeries and endovascular interventional procedures. Thorough knowledge and awareness of renal artery variations will lead to successful outcome of laparoscopic, retroperitoneal surgeries, renal transplantation and various interventional procedures. Multi-detector CT angiography offers an accurate depiction of renal vascular anatomy and should be employed as a pre-procedural diagnostic tool.

ACKNOWLEDGEMENTS

Technical assistance in preparation of images by Mr. Sushil Kumar of Muzaffarnagar Medical College is acknowledged.

Conflicts of Interests: None

REFERENCES

[1]. Ozkan U, Oguzkurt L, Teran F, Kizilkilic O, Koc Z, Koca N. Renal artery origins and variations: angiographic evaluation of 855 consecutive patients. Diagn Interv Radiol. 2006; 12: 183-186. PMID: 17160802

[2]. Hazirolan T, Oz M, Turkbey B, Karaosmanoglu AD, Oguz BS, Canyigit M. CT angiography of the renal arteries and veins: normal anatomy and variants. Diagn Interv Radiol. 2011; 17: 67-73. https://doi.org/10.4261/1305-3825.DIR.2902-09.1

[3]. Doppman J. An ectopic renal artery. Br J Radiol. 1967; 40:312-313. https://doi.org/10.1259/0007-1285-40-472-312 PMid:6020832

[4]. Ichikawa T, Iino M, Kaizumi J, Hara T, Kazama T, Sekiguchi T, Hashimoto J, Nakamura M, Imai Y. A case of right renal artery originating from the thoracic aorta. Jpn J Radiol. 2014; 32 : 716-720. https://doi.org/10.1007/s11604-014-0360-7 PMid:25217879

[5]. Matusz P, Miclaus GD, Gabriel A, Catereniuc I, Olariu S, Shane Tubbs R, Loukas M. Single ectopic thoracic renal artery associated with a normal kidney position and renal artery stenosis: a case report and review of literature. Rom J Morphol Embryol. 2015; 56 (2): 557-561.

[6]. Ishida M, Namiki Y, Watanabe M. Thoracic renal artery: a rare case of renal artery originating from the thoracic aorta and literature review. Anat Sci Int. 2016; 91: 211-214. https://doi.org/10.1007/s12565-015-0290-1 PMid:26173984

[7]. Hatem MA, Gray R. Aberrant supradiaphragmatic renal artery. Journal of Biomedical Graphics and Computing. 2015; 5 (1): 20-22. https://doi.org/10.5430/jbgc.v5n1p20

[8]. Patel K, Gandhi S, Modi P. Unusual origin of right renal artery: A report of two cases. J Clin Diagn Res. 2016; 10 (5): TJ03-TJ04. https://doi.org/10.7860/JCDR/2016/18428.7823 PMid:27437328 PMCid:PMC4948504

[9]. Tegtmeyer CJ, Stanton LW. Thoracic origin of a single renal artery. JAMA. 1969; 209 (8): 1223. https://doi.org/10.1001/jama. 1969. 0316021 005 5019 PMid:5819680

[10]. Cerny JC, Karsch D. Aberrant renal arteries. Urology. 1973; II (6): 623-626. https://doi.org/10.1016/0090-4295(73)90322-1

[11]. Schaffer R, Gordon DH, Glanz S. Renal artery originating above celiac axis. N Y State J Med. 1981; 81: 1109-1111.

[12]. Uchino A, Araki A, Tanaka M, Omoto T. Abnormally high origin of renal artery- a case report (in Japanese). Jpn J Clin Radiol. 1983. 28: 1001-1003. PMID:6663773

[13]. Van Baalen JM, van Bockel HJH, Overbosch EH. Thoracic origin of right renal artery. J Vasc Surg. 1994; 19 (4): 762-763. https://doi.org/10.1016/S0741-5214(94)70059-1

[14]. Cocheteux B, Mounier-Vehier C, Gaxotte V, Mc Fadden EP, Francke JP, Beregi JP. Rare variations in renal anatomy and blood supply: CT appearances and embryological background. A pictorial essay. Eur Radiol. 2001: 11 (5): 779-786. https://doi.org/10.1007/s003300000675 PMid:11372607

[15]. Sueyoshi E, Sakamoto I, Uetani M. Right renal artery originating above the celiac axis. J Vasc Surg. 2009; 49: 1588. https://doi.org/10.1016/j.jvs.2008.11.068 PMid:19307084

[16]. Talovic E, Voljevica A. An unusual renal accessory artery originating from the thoracic aorta and its potential clinical implications. Acta Medica Academica. 2013; 42 (1): 80-82. https://doi.org/10.5644/ama2006-124.74 PMid:23735070

[17]. Delasotta LA, Olivieri B, Malik A, Nguyen C, Bhatia V, Burke W. Thoracic renal artery: a rare variant. A case study and literature review. Surg Radiol Anat. 2015; 37: 561-564. https://doi.org/10.1007/s00276-014-1379-2 PMid:25270524

[18]. Arazinska A, Polguj M, Wojciechowski A, Trebinski L, Stefanczyk L. An unusual case of left renal artery compression: a rare type of median arcuate ligament syndrome. Surg Radiol Anat. 2016; 38: 379-382. https://doi.org/10.1007/s00276-015-1478-8 PMid:25940812 PMCid:PMC4823334

[19]. Stinson JM, Rivard AL, Mitchell ME. Intrathoracic origin of left renal artery. J Vasc Surg. 2016; 64 (6): 1851-1852. https://doi.org/10.1016/j.jvs.2015.06.052 PMid:27871500

[20]. Saddoud N, Bouktif I, Gmiha B, Daghfous MH. Left renal artery originating from the thoracic aorta: Three dimensional imaging findings. Diagnostic and Interventional Imaging. 2017; 98 (4): 359-360. https://doi.org/10.1016/j.diii.2017.02.001 PMid:28285894

[21].Ashalatha K, Teresa Rani S, Pavana Kumari KV, Rayappa Hanok Sritej. A study of anomalies of renal arteries. MedPulse-International Journal of Anatomy. 2017; 1 (3): 49-52.

[22]. Gadabanahalli K, Bhat V. Thoracic origin of single right renal artery: Some interesting facets. Int J Angiol. 2017; 26 (04): 264-266. https://doi.org/10.1055/s-0037-1604328 PMid:29142495 PMCid:PMC5685789

[23]. Rossi UG, Rolandi GA. Thoracic renal artery. Aorta 2019; 7: 96-97. https://doi.org/10.1055/s-0039-1693987 PMid:31614380 PMCid:PMC6794141

[24]. Panagouli E, Venieratos D, Lolis E, Skandalakis P. Variations in the anatomy of the celiac trunk: A systematic review and clinical implications. Ann Anat. 2013: 195: 501-511. https://doi.org/10.1016/j.aanat.2013.06.003 PMid:23972701

[25]. Whitley A, Oliverius M, Kocian P, Havluj L, Gurlich R, Kachlik D. Variations of the celiac trunk investigated by multidetector computed tomography: systematic review and meta-analysis with clinical correlations. Clinical Anatomy. 2020; 1-14. https://doi.org/10.1002/ca.23576 PMid:32012339

[26]. Song SY, Chung JW, Yin YH, Jae HJ, Kim HC, Jeon UB, et al. Celiac axis and common hepatic artery variations in 5002 patients. Systematic analysis with spiral CT and DSA. Radiology. 2010; 255 (1): 278-288. https://doi.org/10.1148/radiol.09090389 PMid:20308464

[27]. Ramesh Babu CS, Joshi S, Gupta KK, Gupta OP. Celiacomesenteric trunk and its variants a multidetector row computed tomography study. J Anat Soc Ind. 2015; 64: 32-41. https://doi.org/10.1016/j.jasi.2015.04.007

[28]. Sureka B, Mittal MK, Mittal A, Sinha M, Bhambri NK, Thukral BB. Variations of the celiac axis, common hepatic artery and its branches in 600 patients. Indian J Radiol Imaging. 2013; 23: 223-233. https://doi.org/10.4103/0971-3026.120273 PMid:24347852 PMCid:PMC3843330

How to cite this article:

Rameshbabu CS, Kumar A, Gupta OP, Sharma Y. SUPRADIAPHRAGMATIC ORIGIN OF RIGHT RENAL ARTERY FROM THORACIC AORTA: CASE REPORT AND LITERATURE REVIEW. Int J Anat Res 2020;8(4.2):7800-7801. **DOI:** 10.16965/ijar.2020.238