

POSTERIOR BELLY OF DIGASTRIC - A KEY MUSCLE TO LOCATE IMPORTANT NEUROVASCULAR STRUCTURES OF UPPER NECK REGION

Manjula Patil *¹, Sangamesh Rakaraddi².

*¹Associate Professor, S. Nijalingappa Medical College, Bagalkot, Karnataka, India.

²Assistant Professor, Department of Anatomy, S. Nijalingappa Medical College, Bagalkot, Karnataka, India.

ABSTRACT

Introduction: Posterior belly of digastric muscle (PBD) is located amidst of important neurovascular structures of head and neck region. Spinal accessory (SAN), Facial (FN) and Hypoglossal nerves (HGN), Common carotid artery (CCA) and internal jugular vein (IJV) are related deep to PBD. It is also easily identifiable landmark in this region. Establishing the accurate relationship between PBD and above mentioned structure would be of great help to head and neck surgeons to perform the surgeries with fewer complications.

Aims and objectives: To establish the near accurate relationship between PBD with HGN, FN, SAN, CCA and IJV.

Materials and methods: Fifty sagittal sections of head and neck region (25 right & 25 left sides) were studied for relation of PBD with various structures using Digital callipers: Length & extended length of PBD, distance between: tip of the mastoid process to HN loop, PBD to FN trunk, midpoint of PBD to midpoint of IJV & bifurcation of CCA, relationship between IJV and SAN above PBD. Statistical analysis carried out using SPSS version 16.

Results: Distances measured were, Length of PBD was 3.20 ± 0.08 cm & 3.56 ± 1.00 cm on right & left side respectively indicating slightly longer length on left side. Extended length was 6.5 ± 0.64 cms & 6.8 ± 1.12 cms on right and left side respectively, TMP to HGN- where it crossed the PBD was 2.17 ± 0.5 on right & 1.92 ± 0.47 cms on left, FN trunk and origin of PBD mean was 0.52cm (range 0.5 – 0.90cm), PBD to midpoint of IJV was 6.12 ± 0.88 cm on right & 6.44 ± 1.02 cm on left, midpoint of PBD to bifurcation of CCA 2.56 ± 0.74 cm on right & 2.99 ± 0.78 cm on left. Relationship b/w SAN & IJV above PBD lateral to IJV in 95% on right 93% on left side. There was no significant right & left difference between all the parameters..

Conclusions: PBD can be very good landmark to locate various neurovascular structures of head & neck region.

KEYWORDS: Posterior belly of digastric (PBD), Neurovascular bundle of head and neck, Facial nerve, Hypoglossal nerve, Spinal accessory nerve, Common carotid artery, Internal jugular vein.

Corresponding Author: Dr. Manjula Patil, Associate Professor, Department of Anatomy, S. Nijalingappa Medical College, Bagalkot, Karnataka, India. Ph. No: 9008616221

E-Mail: drmanjulapatil@gmail.com

Access this Article online	Journal Information
Quick Response code 	International Journal of Anatomy and Research ISSN (E) 2321-4287 ISSN (P) 2321-8967 https://www.ijmhr.org/ijar.htm DOI-Prefix: https://dx.doi.org/10.16965/ijar 
	Article Information
	Received: 03 Apr 2020 Peer Review: 03 Apr 2020 Revised: None
	Accepted: 07 May 2020 Published (O): 05 Jun 2020 Published (P): 05 Jun 2020
DOI: 10.16965/ijar.2020.153	

INTRODUCTION

Digastric muscle is located in the upper part of the neck. It has two bellies with separate embryological origins and innervations. It forms the

limits for submandibular, Submental and carotid triangles. Among the two bellies, posterior belly of digastric is located amidst of important neurovascular bundles of upper neck region [1].

The Spinal accessory nerve (SAN), Facial nerve (FN) and Hypoglossal nerve (HGN), Common carotid artery (CCA) and internal jugular vein (IJV) are related very closely deep to PBD [2].

Radical suprahyoid neck dissections are often required to remove metastatic lymph nodes in the carcinoma involving the floor of the mouth. In such dissections, PBD serves as a useful landmark [3].

Palpation of PBD is a mandatory procedure in temporomandibular disorders [4].

During the surgery, the PBD is the most easily identifiable landmark for facial nerve dissection during parotidectomy, with a consistent anatomical relationship with the facial nerve trunk [5] It is also easily identifiable landmark in this region. There is limited literature with respect to PBD. The accurate relationship between PBD and above mentioned structure would be of great help to head and neck surgeons to perform the surgeries with fewer complications.

Aims and objectives:

To establish the near accurate relationship between PBD with HGN, FN, SAN, CCA and IJV.

MATERIALS AND METHODS

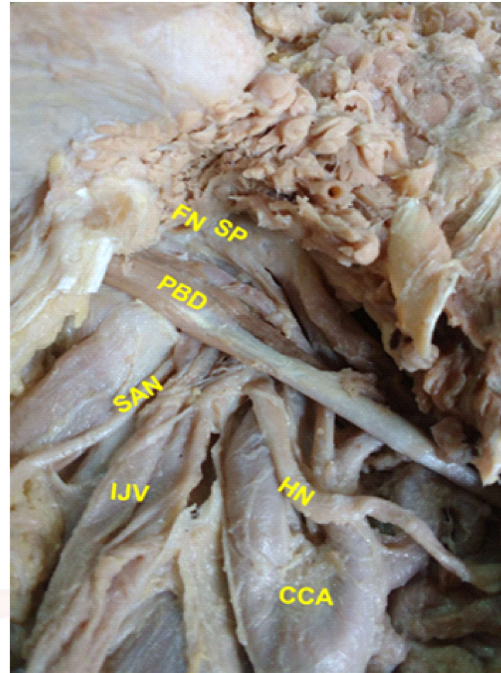
Fifty sagittal sections of head and neck region (25 right & 25 left sides) were studied for relation of PBD with various structures using Digital callipers at department of anatomy, S. N. Medical College, Bagalkot.

Following parameters were studied:

1. Length(Fleshy part)
2. Extended length of PBD (distance between tip of the mastoid process(TMP) to junction between body & greater cornu of hyoid bone)
3. Distance between tip of the mastoid process to HN loop
4. Distance between PBD to FN trunk,
5. Midpoint of PBD to midpoint of IJV(midpoint b/w angle of the mandible and sternoclavicular joint)
6. Midpoint of PBD to midpoint of CCA
7. Relationship between IJV and SAN above PBD.

Statistical analysis carried out using SPSS version 16.

Fig. 1: Showing the Posterior belly of digastric with other structures.



PBD- Posterior belly of digastric

FN- Facial nerve

HN- Hypoglossal nerve

SAN- Spinal accessory nerve

IJV- Internal jugular vein

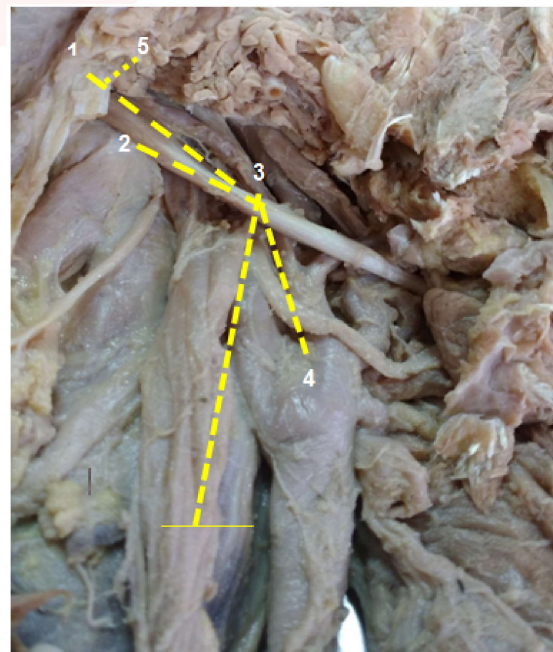
CCA- Common carotid artery

SP- Styloid process

TMP- Tip of mastoid process

PG- Parotid gland

Fig. 2: Showing the length of Posterior belly of digastric with other structures.



1- Length of PBD

2- Distance b/w TMP to HN where it crosses PBD

3- Midpoint of PBD to midpoint of IJV

4- Midpoint of PBD to bifurcation of CCA

5- Distance b/w PBD to trunk of FN

RESULTS

Sl.no	parameter	Right side	Left side
1	Length of PBD	3.20±0.08cm	3.56 ±1.00cm
2	Extended length of PBD	6.5±0.64cms	6.8±1.12cms
3	Distance b/w TMP to HGN	2.17±0.5 cms	1.92±0.47cms
4	FN trunk and origin of PBD	0.52cm	0.90 cm
5	Midpoint PBD to midpoint of IJV	6.12± 0.88cm	6.44±1.02cm
6	Midpoint of PBD to bifurcation of CCA	2.56±0.74cm.	2.99±0.78cm
7	Relationship b/w SAN & IJV above PBD lateral to IJV in	95% lateral to IJV	93% lateral to IJV

Table 1:Relation of Posterior belly of digastric with neurovascular bundles of head and neck region.

No variations were noted in the PBD. PBD length was more on left side (3.56 ±1.00cm) but no statistical significance was observed between the two sides. The HGN crossed PBD anterior to TMP at a distance of 2.17±0.5 cms and 1.92±0.47cms on right and left respectively. FN trunk was located about 0.52 to 0.90cms from the origin of PBD. The midpoint of IJV and CCA were located 6.12 to 6.44 cms and 2.56 to 2.99 cms from the midpoint of PBD respectively. Relation of SAN was lateral to IJV in 93-95% specimens above the PBD.

DISCUSSION

PBD is amidst of important neurovascular bundle of head & neck region[1]. Palpating PBD is a very important step in temporomandibular joint disorder[4]. Various authors have reported variation of PBD earlier [2]. Such a variations are important to note to avoid injury to nearby structures during operations. In our study we did not come across any variations among PBD.

We studied the length & extended length of PBD.

In contrary to Vrinda[1] and shin et al[6] study, our study showed slightly more length on left side. The variation in length may due to positioning of the sagittal heads and other minor contributory factors. These parameters may help radical suprahyoid neck procedures designed to remove metastatic lymph nodes in carcinoma involving floor of mouth. In such dissections, PBD serves as a useful landmark [7].(Table 2).

Studies	Length		Extended length	
	Right	Left	Right	Left
Vrinda et al [1]	3.77 ± 1.08 cm	3.15 ± 0.05 cm	6.7 ± 1.23 cm	6.7 ± 0.75 cm
Shin et al[6]	6.22 ± 0.60 cm	5.29 ± 0.72 cm		
Present study (Table 1)	3.20±0.08cm	3.56 ±1.00cm	6.5±0.64cms	6.8±1.12cms

Table 2:Extended length of Posterior belly of digastric.

HGN crossing the PBD anterior to TMP

These parameters are important in the neck region, especially in relation to submandibular gland resection, since this muscle and its tendon are anatomical reference points during operations[8](Table 3).

Distance between PBD to FN trunk

Identification of the facial nerve trunk is essential during surgery of the parotid gland to avoid its damage. Postoperative facial nerve weakness can be temporary (10-50%) or permanent(0.5 %.)[5]. Thus relationship between PBD and FN may give additional landmark to identify FN (Table 4)

Distance between Midpoint of PBD to midpoint of IJV(This distance is midpoint between the angle of the mandible and sternoclavicular joint)

When operating above the level of PBD, IJV and SAN are at risk. Therefore, it is necessary to recognize the morphometric anatomy of the digastric muscle in order to avoid complications to the IJV and spinal accessory nerve during therapeutic procedures[12](Table 5).

Distance between midpoint of PBD to bifurcation of CCA

This parameter helps to avoid injury to CCA in upper neck surgeries(Table 6).

Relationship between IJV and SAN above PBD.

The knowledge of relationship between SAN & IJV minimises the complication to these structures during upper neck surgeries(Table 7)[12]

Table 3:Distance between PBD to FN trunk,

Studies	Right side	Left side
Vrinda et al [1]	2.72 ± 0.8 cm	2.1 ± 0.57 cm
Shin et al[6]	found that the HN appeared under the PBD, and the crossing point corresponded to about 65.5% of the whole length of the PBD from the digastric groove	
Present study	2.17±0.5 cm	1.92±0.47cms

Table 4: Distance between PBD to FN trunk.

Studies	Results
Rea et al.[9]	5.5 ± 2.1 mm
Pather and Osman[10]	9.7–24.3 mm
Witt et al.[11]	12.4 mm (cad) 10.7 mm (live)
Shaha et al [5]	6–9.5 mm (cad) 6–11.5 mm (live)
Present study (Table 1)	0.52- 0.90 cms

Table 5:Distance between Midpoint of PBD to midpoint of IJV.

Studies	Right	Left
Vrinda et al[1]	6.58 ± 0.99 cm	6.1 ± 0.96 cm
Present study	6.12± 0.88cm	6.44±1.02cm

Table 6:Distance between midpoint of PBD to bifurcation of CCA.

Studies	Right	Left
Vrinda et al [1]	3.04 ± 0.61 cm	2.78 ± 0.74 cm
Present study (Table 1)	2.56±0.74cm.	2.99±0.78cm

Table 7:Relationship between IJV and SAN above PBD.

Studies	Right	Left
Hensley ML et al[12]	(96%) lateral, (3%) medial (1%) of SAN travelled directly through the IJV above the superior border of PBD	
Present study (Table 1)	95% lateral 5% Medial	93% lateral 7% medial

CONCLUSION

In view of complicated anatomy of upper neck region its not enough to have single landmark to locate the structures. PBD is an easily approachable landmark in the upper neck region. The PBD represents a good landmark during the upper neck dissection to identify the important neurovascular bundle.

Limitations:This study has inherent limitations of study on cadavers. To get accurate results study has to be done in living individuals. This study acts as a rough guide to locate the structures in relation to PBD.

Conflicts of Interests: None

REFERENCES

- [1]. Vrinda Hari Ankolekar, Anne D. Souza, Rohini Alva, Antony Sylvan D. Souza, Mamatha Hosapatna. Posterior belly of the digastric muscle: An important landmark for various head and neck surgeries. Archives of Clinical and Experimental Surgery 2015; 4(2):79-82 .
- [2]. Bergmann RA, Afifi AK, Miyauchi R. Muscular system: Alphabetical listing of muscles: D. Available from: <http://www.anatomyatlases.org/AnatomicVariants/MuscularSystem/Text/D/06Digastricus.shtml>. [Last accessed on May 06 2014].
- [3]. Mehta V, Gupta V, Arora J, Yadav Y, Suri RK, Rath G, et al. Bilateral bipartite origin of the posterior belly of digastric muscle: A clinico-anatomical appraisal. Int J Exp Clin Anat 2011;5:44-7.
- [4]. Türp JC, Arima T, Minagi S. Is the posterior belly of the digastric muscle palpable? A qualitative systematic review of the literature. Clin Anat 2005;18:318-22.
- [5]. Saha S, Pal S, Sengupta M, Chowdhury K, Saha VP, Mondal L. Identification of facial nerve during parotidectomy: A combined anatomical & surgical study. Indian J Otolaryngol Head Neck Surg 2014;66:63-8.
- [6]. Shin DS, Bae HG, Shim JJ, Yoon SM, Kim RS, Chang JC. Morphometric study of hypoglossal nerve and facial nerve on the submandibular region in Korean. J Korean Neurosurg Soc 2012;51:253-61.
- [7]. Suen JY, Stern SJ. Cancer of neck. In: Myers EN, Suen JY, editors. Cancer of Head and Neck. WB . Saunders Co, Philadelphia, 1996;462-84.
- [8]. Liquidato BM, Barros MD, Alves AL, Pereira CS. Anatomical study of the digastric muscle: Variations in the anterior belly. Int J Morphol 2007; 25:797-800.
- [9]. Rea PM, McGarry G, Shaw-Dunn J (2010) The precision of four commonly used surgical landmarks for locating the facial nerve in anterograde parotidectomy in humans. Ann Anat 192(1):27–32
- [10]. Pather N, Osman M (2006) Landmarks of the facial nerve: implications for parotidectomy. SurgRadiolAnat 28(2):170–175.
- [11]. Witt RL, Weinstein GS, Rejto LK (2005) Tympanomastoid suture and digastric muscle in cadaver and live parotidectomy. Laryngoscope 115(4):574–577.
- [12]. Hinsley ML, Hartig GK. Anatomic relationship between the spinal accessory nerve and internal jugular vein in the upper neck. Otolaryngol Head Neck Surg 2010;143:239-41.

How to cite this article: Manjula Patil, Sangamesh Rakaraddi. POSTERIOR BELLY OF DIGASTRIC - A KEY MUSCLE TO LOCATE IMPORTANT NEUROVASCULAR STRUCTURES OF UPPER NECK REGION. Int J Anat Res 2020;8(2.3):7539-7542. DOI: 10.16965/ijar.2020.153