International Journal of Anatomy and Research,
Int J Anat Res 2018, Vol 6(4.3):5950-53. ISSN 2321-4287
DOI: https://dx.doi.org/10.16965/ijar.2018.381

Original Research Article

A STUDY OF MANDIBULAR FORAMEN IN NORTH INDIAN POPULATION

Sadiq Siddiqui *[1], Alok Kumar Singh [2], Abdul Rehman Khan [3].

*[1] Assistant professor, Department of Anatomy, Rajshree medical research institute, Bareilly (UP), India.

[2] Assistant professor, Department of Anatomy, Govt. Medical College, Jalaun (UP), India.

[3] Assistant professor, Department of ENT, Rajshree medical research institute, Bareilly (UP),India.

ABSTRACT

Background: Mandibular foramen (MF), present on the medial surface of ramus of the mandible, leads to the mandibular canal through which inferior alveolar nerve (IAN) and vessels transmit. IAN block is a common anaesthetic procedure before dental and reconstructive surgeries. Surgeons usually do IAN block in their clinics and encounter failure of block because of variable position of MF.

Objective: The present study was carried out to find the most common position of MF in north Indian population.

Materials and Methods: Study was done on 50 dry adult human mandibles of unknown sex and age of north Indian origin. Height was measured from the angle of the mandible to the highest point on condyloid process. Mid point of the line joining these points was noted. The position of MF was observed in relation to pre noted mid point.

Results: MF was placed below the level of mid point in 40 mandibles (80%).

Conclusion: The knowledge of most common position of MF will help the surgeons to reduce the chance of unsuccessful IAN block.

KEY WORDS: Inferior Alveolar Nerve block, Mandibular Foramen, ramus of mandible.

Address for Correspondence: Dr. Sadiq Siddiqui, Assistant professor, Department of anatomy, Rajshree medical research institute, Bareilly (UP), India. **E-Mail:** drsadiqsiddiqui@gmail.com

Access this Article online	Journal Information
Quick Response code	**International Journal of Anatomy and Research** ICV for 2016 90.30 ISSN (E) 2321-4287 | ISSN (P) 2321-8967 **https://www.ijmhr.org/ijar.htm** **DOI-Prefix:** https://dx.doi.org/10.16965/ijar
DOI: 10.16965/ijar.2018.381	**Article Information** Received: 11 Sep 2018 Accepted: 24 Oct 2018 Peer Review: 13 Sep 2018 Published (O): 05 Dec 2018 Revised: None Published (P): 05 Dec 2018

INTRODUCTION

Mandibular foramen (MF) is present on the medial surface of the quadrilateral ramus of the mandible. It is irregular in shape and lies just above the center, midway between the anterior and posterior border of the ramus. Mandibular foramen leads to the mandibular canal through which inferior alveolar nerve and vessels will transmit and supply the teeth of lower jaw [1].

Inferior alveolar nerve (IAN) block is a common anaesthetic procedure before dental and reconstructive surgeries. In this technique, anaesthetic solution is injected in infratemporal space near inferior alveolar nerve [2].

The success of this technique highly depends on the needle tip to the MF at the time of anaesthetic solution injection [3]. Malamed reported that it is successful in 80-85% of patients [4]. However some authors have estimated that failure of this method is 29-35% of

patients [5, 6]. Failure of Halsted approach may be attributed to absence of specific anatomic bony landmark and variations in the position of MF [7,8].

In most of the textbooks of anatomy, various positions of mandibular foramen are mentioned. Some author mentioned that MF to be located above the center of the ramus on medial surface, where as others described it to be present approximately in the center of the medial side of ramus mandibulae i.e. between the anterior and posterior ridge of mandibular ramus [1,9].

Marzola et al noted that there is scarcity of literature regarding the anatomical reference point for location of the mandibular foramen in the medial surface of the mandibular ramus [10].

Hence the goal of this study was to find the most common position of MF in north Indian population.

MATERIALS AND METHODS

Present study was conducted on 50 adult human dry mandibles of unknown sex and age in the department of anatomy, Rajshree medical research institute, Bareilly. Only those mandibles were selected which had both the molar tooth erupted into occlusion. Mandibles with alveolar bone resorptions, malposition of teeth, or having any other pathological deformity were excluded. The position of MF was observed and the height was measured from the angle of the mandible to the highest point on the condyloid process with the help of flexible measuring tape. The mid point of the line joining these points was noted. The position of the MF was observed on both the sides in relation to pre noted mid point. Three different positions of the mandibular foramen were categorized as:

-Above the mid point

- At the mid point

-Below the mid point

Data obtained was tabulated and percentage of all the locations was calculated. Above mentioned positions of MF were photographed by Sony DSLR.

RESULTS

In the present study, we observed that MF was present bilaterally in all the mandibles (50) (Table 1), but their position from the angle of mandible was variable. We noted that MF was placed above the mid point in one (2%) mandible (Fig. 1) and at the level of mid point in 9 (18%) mandibles which was second most common position both on right as well as left side (Fig. 2).

In majority (40) of the mandibles (80%), MF was placed below the level of mid point, which was same for both right and left side (Fig. 3).

Table 1: distribution of mandibular foramen.

Sl. No.	Position	Right side		Left side	
		Number	Percentage	Number	Percentage
1	Above the mid point	1	2%	1	2%
2	At the mid point	9	18%	9	18%
3	Below the mid point	40	80%	40	80%
Total		50	100%	50	100%

Fig. 1: Showing mandibular foramen above the mid point.

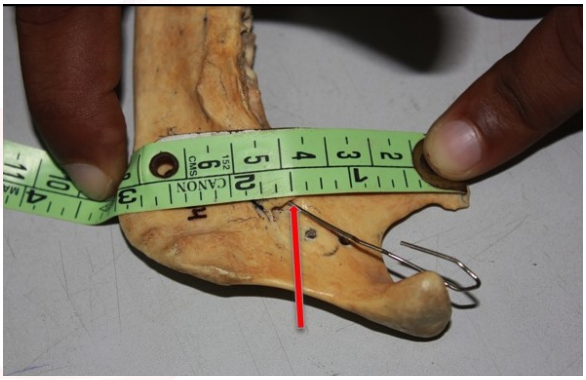

Fig. 2: Showing mandibular foramen at the mid point.

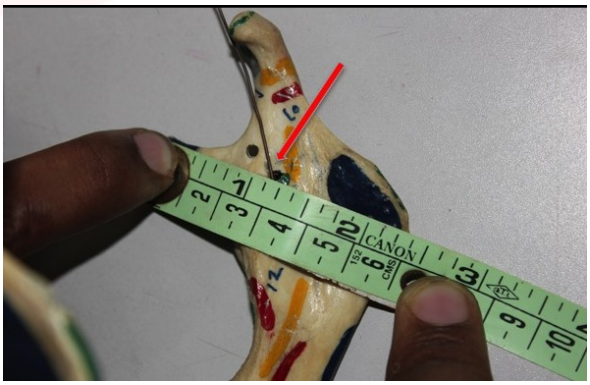

Fig. 3: Showing mandibular foramen below the mid point.

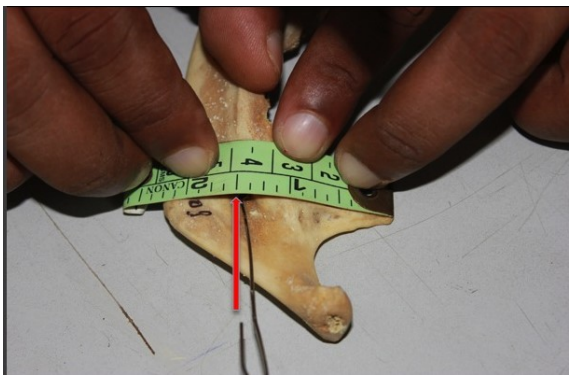

DISCUSSION

Mandibular foramen is an opening on the medial surface of ramus of mandible through which inferior alveolar nerve and vessels pass in to the mandibular canal.

Location of MF is useful for dental surgeons and anesthetists for successful mandibular anesthesia. Failure of inferior alveolar nerve block may be due to inadequate evaluation of anatomic landmarks due to variability in position of MF.

In the present study, the most common position of MF on both sides was below the mid point (80%) on medial side of ramus mandibulae, which is totally in contrast with the Grant's method of anatomy, in which author states that MF lies at the center of medial surface of ramus [11]. Least common position in present study was above the mid point (2%), which is again contradictory with the position of MF mentioned in Gray's, textbook of anatomy, where author described the position of MF a little above the center of the ramus [12].

Lavanya et al found that in majority of mandibles i.e. 71% of dentulous and 61% of edentulous mandibles, the MF was above the level of the occlusal plane in south Indian population which was in contrast to present study over north Indian population [13].

Yadaridee et al stated that the MF is located approximately at the junction between the upper two third (2/3rd) and lower one third (1/3rd) of a line joining the coronoid process and the angle of mandible, predominantly below the occlusal plane(87.43%) which was consistent with present study [14].

Narayana et al noted that MF maintains bilateral symmetry in dry mandibles in all ages [15]. According to the result of present study, we also concluded that location of mandibular foramen, in both right and left mandibular rami is in symmetry.

In a study on formalin preserved hemi mandibles by Daw et al, who noted that there exists great variability in the position of MF, which is similar with the findings of present study [16].

Nicholson et al stated that the position of MF were variable, and concluded that the marked variab-ility in the position of MF may be responsible for an occasional failure during IAN block [17].

Narayan et al studied the mandibles to determine the position of MF and also measured the position from different landmarks like 3rd molar tooth, anterior border of ramus and mandibular notch keeping the center of MF as reference point where as in some other studies lingula was chosen as the reference point which keeps on changing with advancing age. They found that the foramen was present in all the mandibles and maintains bilateral symmetry in human mandibles in all age group, which was in consistence with our study [15].

Mandibular foramen location becomes extremely important for dentists and other surgeons when anesthesia of inferior alveolar nerve is attempted. Dental surgeons in clinics usually encounter failure of anesthesia because of variable position of mandibular foramen.

CONCLUSION

Present study concludes that the most common positions of MF in north Indian population is below the mid point of ramus of mandible, this knowledge will help the dental surgeons in reducing the chance of unsuccessful IAN block. Even then block is not achieved, they can reattempt the block on other most frequent position of MF. It is advised do not inject overdose of anesthetic agent to achieve desired effect.

ABBREVIATIONS

MF – Mandibular nerve

IAN – Inferior alveolar nerve

Conflicts of Interests: None

REFERENCES

[1]. Standring S. Gray's Anatomy: The Anatomical Basis of Clinical Practice, 40th Edition; Churchill-Livingstone: Elsevier.2008. Chapter-31, Page 530-533, 595-614.

[2]. Afsar, A., D.A. Haas, P.E. Rossovw and R. Wood. Radiographic localization of mandibular anaesthesia landmarks. Oral Surgery Oral Med. Oral Pathol. Oral Radiol. Endod.,1998; 66: 234-241.

[3]. Shenoy V, Vijayalaxshmi S, Saraswathi P. osterometric analysis of mandibular foramen in dry human mandibles. Journal of clinical and diagnostic research., 2012; 6:557-560.

[4]. Malamed, S.F. Handbook of local Anesthesia, 4th edition; Mosby Publishers, St. Louis, 2004. Page 193.
[5]. Robertson, W.D. Clinical evaluation of mandibular conduction anesthesia. Gen. Den., 1979, 27:49-51.
[6]. Levy, T.B. An assessment of the Gow-Gates mandibular block for third molar surgery. J. Am. Dent. Assoc., 1981, 103: 37-41.
[7]. Grover, P.S and L. Lorton. Bifidmandibular nerve as a possible cause of inadequate anesthesia in the mandible. J. Oral. Maxillofac. Surg., 1983, 41: 177-179.
[8]. Kaafman, E., P. Weinstein and P. Milgrom. Difficulties in achiving local anesthesia. J. Am. Dent. Assoc., 1984, 108:205-208.
[9]. Sicher, H. and DuBrul E.L. Oral anatomy, 8th edition, St. Louis; Ishiyaku Euro America Inc. 1988.
[10]. Marzola, C; Frare, P. H. B; Toledo Filho, J. L. & Navarro, J.A.C. Mandibular foramen contribution to your localization to anesthetical techniques. Acad. Tirad. De Odon, 2005; 2(3): 235-258.
[11]. Basmajian JV**.** Grants method of anatomy, 10th edition Baltimore; Williams and Wilkins Co. 1980. Page 473.
[12]. William PL and Warwick R. Gray's Anatomy. 36th Edition, Edinburdg; Jarrold and Sons Ltd. 1980. Page 316-317.
[13]. Lavanya CV, Haq I and Rajeshwari T. Position of mandibular foramen in south Indian mandibles. Anatomica Karnatka, 2011; 5 (1): 53-56.
[14]. Yadaridee V and Vasan P. The mandibular foramen in Thais. Siriraj Hosp Gaz, 1989; 41(10):551-554.
[15]. Narayana K, Nayak SA, Narayan P and Prabhu LV. The location of the mandibular foramen maintains absolute bilateral symmetry in mandibles of different age groups. Hong Kong Dental Journal, 2005; 2: 35-7.
[16]. Daw, J. L. Jr; de La Paz, M.G.; Han, H.; Aitken, M. E. & Patel, P. K. the mandibular foramen: anatomic study and its relevance to the sagittal ramus osteotomy. J. Craniofac. Surg., 1999; 10: 475-9.
[17]. Nicholson ML. A study of the position of the mandibular foramen in the adult human mandible. Anat Rec., 1985;212:110-112.

How to cite this article:

Sadiq Siddiqui, Alok Kumar Singh, Abdul Rehman Khan. A STUDY OF MANDIBULAR FORAMEN IN NORTH INDIAN POPULATION. Int J Anat Res 2018;6(4.3):5950-5953. **DOI:** 10.16965/ijar.2018.381