

Case Report

PALMARIS INVERSUS MUSCLE: A CASE REPORT WITH CLINICAL AND SURGICAL DISCUSSIONS

Caio Fernando Cardoso Souza ¹, Lucas Alves Sarmiento Pires ¹, Leonardo de Oliveira de Figueiredo ², Claudio Pena Gonçalves², Rodrigo Mota Pacheco Fernandes ¹, Marcio Antonio Babinski ^{*1,2}.

¹Morphology Department, Biomedical Institute, Fluminense Federal University, Niterói, Rio de Janeiro, Brazil.

²Traumatology and Orthopedics Service, Salgado Filho Hospital, Rio de Janeiro, Brazil.

ABSTRACT

Background: The palmaris longus muscle is a slender fusiform muscle. It is especially prone to vary in comparison to other muscles in the upper limb and it is considered to be a vestigial structure. It is the most variable muscle in the human body, although its reverted state is barely discussed. The palmaris longus inversion can cause compression on neurovascular bundles, specially the median nerve on the carpal tunnel and the ulnar nerve on the Guyon canal.

Case report: The present report describes a case of reversed palmaris longus, whereas its origin was composed by fleshy tissue and its distal portion was composed by a tendinous component. Furthermore, the reversed palmaris longus muscle was in association with an incomplete superficial palmar arch.

Conclusion: Surgeons, radiologists and anatomists must be aware of the variations of the palmaris longus muscle. Prior knowledge those variations are helpful in planning intricate surgeries to which the palmaris longus muscle is useful.

KEY WORDS: Anatomical Variations, Palmaris Longus Muscle, Guyon Canal, Cadaver, Surgery, Palmaris Inversus, Reversed Palmaris Longus.

Address for Correspondence: Dr. Marcio Antonio Babinski, Morphology Department - Biomedical Institute - Fluminense Federal University, Av. Prof. Hernani Mello 101, CEP 24.210-150, Niterói, RJ, Brasil. (55) 21 2629-2335 **E-Mail:** mababinski@gmail.com

Access this Article online

Quick Response code



DOI: 10.16965/ijar.2017.383

Web site: International Journal of Anatomy and Research
ISSN 2321-4287
www.ijmhr.org/ijar.htm

Received: 30 Jul 2017
Peer Review: 31 Jul 2017
Revised: None

Accepted: 05 Sep 2017
Published (O): 01 Oct 2017
Published (P): 01 Oct 2017

INTRODUCTION

The palmaris longus muscle (PLM) is a superficial, slender, fusiform muscle of the forearm which acts as a weak wrist flexor together with the other forearm flexor muscles [1,2].

The proximal fleshy attachment is on the medial epicondyle of the humerus, the adjacent flexor muscles and the intermuscular septum or the flexor retinaculum. It inserts it self into the palmar aponeurosis [2,3]. It lies between the

flexor carpi radialis and flexor carpi ulnaris muscles and superficial to the median nerve [1-5]. It is supplied by branches of the ulnar and brachial arteries, and branches of the median nerve supply its innervations [2,6].

The PLM is described as one of the most variable muscles in our body and is classified as a phylogenetic and atavistic structure [5,7,8] Variations of the PLM can be responsible for compartment syndrome of the forearm, wrist

and hand. Those include carpal tunnel syndrome and Guyon syndrome. Moreover, its variations can be difficult to identify and be misleading in radiological investigations [3,4,9].

Furthermore, the tendon of this muscle can be used as a graft during many surgical procedures including pulley reconstruction, ligament reconstruction, ocular defects, reconstruction of ligaments of thumb and elbow [4,10].

The present report describes a case of an inversed palmaris longus muscle (palmaris inversus), followed by a literature review and an embryological, anatomical, clinical and surgical discussion.

CASE REPORT

During routine dissection of the right forearm of a male cadaver fixated in a 10% formalin solution, it was observed an uncommon variation of the PLM

The PLM was reversed (Palmaris longus inversus (PLI)) – its proximal portion was tendinous while its distal portion was composed by muscle tissue (Figure 1). Moreover, it was also observed the entrapment of the ulnar nerve on the Guyon canal and an incomplete superficial palmar arch (Figure 2). There were no other abnormalities on the right or left upper limbs.

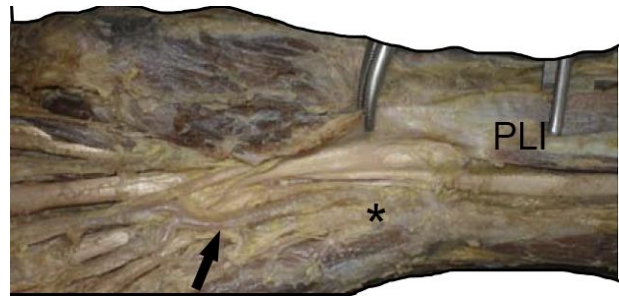
The PLI originated from the medial epicondyle of the humerus from a tendinous origin and in the middle third of the forearm the PLI became a hypertrophied fleshy structure that went downwards until the palmar aponeurosis and palmar carpal ligament (Figures 1 and 2).

This variation possessed 27.33 cm of length, and its tendon was 18.3 cm long and 0.9 cm wide. The muscular portion had a fusiform shape and was 9.03 cm long and 1.8 cm wide in its middle portion.

Fig. 1: Anomalous palmaris inversus muscle found during cadaveric dissection.



Fig. 2: Dissection of the anterior compartment of wrist showing the palmaris inversus muscle (PLI) and its insertion on the palmar carpal ligament. Ulnar nerve entrapment on the Guyon canal (black asterisk) and incomplete superficial palmar arch (black arrow) can be seen.



DISCUSSION

Variations of the PLM are vastly described in the literature [1,4,11-13].

The PLI is an uncommon variation and it has been described by a few authors [1,13,14]. A three headed PLI has also been reported as a surgical finding [11,13,15,16].

Some authors have described the PLM as a mere regressive metacarpophalangeal flexor because of its lack of effective function and its numerous anatomical variations [1,8,17,18].

It is seen to be prominent in mammals that use their forelimbs for walking. The PLM is a well-developed muscle in orangutans although it can be absent in chimpanzees and gorillas [1,16].

In cats and other carnivorous predators, the PLM tendon is involved in retracting its claws. Since we haven't had retractable claws at any time in the last several million years, this structure would serve no specific purpose to humans, thus, agenesis rates of this muscle are seemingly rising [8,16,19].

Agenesis of PLM are related to Mendelian principles, whereas its absence is autosomal dominant and its presence is autosomal recessive [1]. It is more common in women and bilaterally. Unilateral absence occurs usually on the left side. Furthermore, its absence was firstly reported by Colombo in 1559 [1,4, 5,12-14].

The PLI may cause compartment syndrome with pain and edema in the wrist area, carpal tunnel syndrome and Guyon's syndrome. The overuse of such PLI may cause its local hypertrophy and be associated with compression of median nerve and less frequently ulnar nerve at wrist

[1,7,11,12,16,18-20].

An increasing number of surgeons are reporting patient cases where this variation is the cause of median nerve compression in patients performing repetitive work tasks like the machine operators. Such patients end up with hypertrophy of the distal muscle belly, thus causing localized pressure on the median nerve which results in effort-related pain at wrist [14, 21]. Patients who complain of wrist pain with a palpable mass at the volar wrist should be examined thoroughly for variations of the PLM [21]. Some authors reported that the PLI is one among its common polymorphic variation in which the muscle is fleshy distally and tendinous proximally [11,22] and it was first described by John T. Morrison (1916) as an incidental post amputation finding, statement [1].

The PLI described herein had a tendinous origin from the medial epicondyle of humerus. At the wrist, the muscle fibres appeared and inserted in the palmar carpal ligament and continued into the palmar aponeurosis where they ultimately terminated. It was noted that the hypertrophied muscle belly displayed ulnar nerve entrapment in the Guyon canal. An incomplete superficial palmar arch artery was also noted. Measurements of the PLI described here was similar to data provided by other authors [11].

Anatomical studies states that the PLI is more often seen on the left side [13], although other studies describe a higher prevalence of PLI on the right side [11,14,15].

It is also important to be aware that symptoms of a muscular variation may occur depending on the use of the variant muscle [11, 22]. In the case of a PLI, the use of the right arm, forearm and hand might cause the muscle to hypertrophy, thus causing the ulnar nerve and median nerve compression symptoms [21]. On the other hand, hypertrophic PLM can results in pseudo mass of the forearm [15,21,23].

Dupuytren's contracture commonly begins at the root of the ring finger and draws it into palm. Later, this condition generally extends into the little finger. Pull on fibrous flexor sheath results in flexion at interphalangeal joints. Thus, this contracture results in flexion deformity of the fingers and loss of hand function with the acute

flexion of proximal and middle phalanges as the palmar aponeurosis is attached to them [24]. The variations observed here with multiple abnormal attachments of the PL may aggravate these symptoms with the possible involvement of the thumb [25].

A symptomatic PLI is of obvious clinical and surgical importance. However, an asymptomatic muscle may also be of interest in clinical situations because an unexpected muscular belly in the wrist region can cause difficulties in the interpretation of local radiological images [15, 21, 23]. Furthermore, difficulties during endoscopic wrist procedures and electromyographic studies of the median nerve may be encountered due to abnormalities of the PLM such as the PLI [1,11].

PLM muscle is usually the first choice in cosmetic, plastic and reconstructive surgeries, as tendon and muscle grafts are frequently needed. This is attributed to its morphology, since its tendon fulfills the criteria of length, breadth and easy surgical accessibility [4,5,23].

Knowledge of PLM variations is helpful for the surgeon and the radiologist during any diagnosis of the forearm because this fleshy part of muscle can be mistaken as a tumor or ganglion [23]. Moreover, a study suggested that patients with a PLI may develop edema and inflammation accompanied by a bluish discoloration, which leads to numbness or pain in the palmar surface of the hand and distal third of the forearm [26].

Thus, every surgeon, anatomist and physician must be aware of the variations of the PLM. Prior knowledge of the morphology of the muscle helps in planning intricate surgeries to which this tendon is put use to. Furthermore, it is an important muscle regarding anthropological and evolutionary studies.

CONCLUSION

To conclude, abnormalities of the PLM such as the PLI should not be overlooked due to the fact that it can imitate tumors and cause difficult in a great number of procedures. Moreover, it can cause compression of the ulnar and median nerves as well as mimic symptoms of Dupuytren's contracture.

Conflicts of Interests: None

REFERENCES

- [1]. Mathew AJ, Sukumaran TT, Joseph S. Versatile but temperamental: a morphological study of palmaris longus in the cadaver. *Journal of clinical and diagnostic research : JCDR*. 2015;9(2):AC01-3.
- [2]. Testut L, Latarjet A. *Tratado de Anatomía Humana*. 8th ed. Barcelona: Salvat; 1958.
- [3]. Ghosh B, Kalia V, Thakur B, Yadav S, Nanda K. Anatomical Variation of Palmaris Longus: Tendinous Origin and Fleshy Insertion. *International Journal of Anatomy and Research*. 2015;3(1):835-7.
- [4]. Natsis K, Didagelos M, Manoli SM, Vlasis K, Papatheanasiou E, Sofidis G, et al. Fleshy palmaris longus muscle - a cadaveric finding and its clinical significance: a case report. *Hippokratia*. 2012;16(4):378-80.
- [5]. Dimitriou I, Katsourakis A, Natsis K, Kostretzis L, Noussiosa G. Palmaris Longus Muscle's Prevalence in Different Nations and Interesting Anatomical Variations: Review of the Literature. *Journal of clinical medicine research*. 2015;7(11):825-30.
- [6]. Wafae N, Itezerote AM, Laurini Neto H. Arterial branches to the palmaris longus muscle. *Morphologie*. 1997;81(253):25-8.
- [7]. Pai MM, Prabhu LV, Nayak SR, Madhyastha S, Vadgaonkari R, Kirshnamurthy A, et al. The palmaris longus muscle: its anatomic variations and functional morphology. *Rom J Morphol Embryol*. 2008;49(2):215-7.
- [8]. Barkáts N. Change of the agenesis rate of palmaris longus muscle in an isolated village in Ukraine. *Folia Morphol*. 2015;74(4):470-4.
- [9]. O'Sullivan E, Mitchell BS. Association of the absence of palmaris longus tendon with an anomalous superficial palmar arch in the human hand. *J Anat*. 2002;201(5):405-8.
- [10]. Júnior LCA, Angelini FB, Oliveira BCd, Soares SA, Angelini LC, Cabral RH. Use of the Tendon of the Palmaris Longus Muscle in Surgical Procedures: Study on Cadavers. *Acta Ortop Bras*. 2012;20(4):226-9.
- [11]. Fazan VPS. Reversed palmaris longus muscle and median nerve relationships. Case report and literature review. *Braz J Morphol Sci*. 2007;24(2):88-91.
- [12]. Nayak SR, Kirshnamurthy A, Ramanathan LA, Prabhu LV, Kumar CG, Tom DK, et al. Multiple muscular anomalies of upper extremity: A cadaveric study. *Rom J Morphol Embryol*. 2008;49(3):411-5.
- [13]. Tubbs RS, Shoja MM, Loukas M, editors. *Bergman's Comprehensive Encyclopedia of Human Anatomical Variation*. Philadelphia: Wiley-Blackwell; 2016.
- [14]. Cope JM, Looney EM, Craig CA, Gawron R, Lampros R, Mahoney R. Median nerve compression and the reversed palmaris longus. *IJAV*. 2009;2:102-4.
- [15]. Yildiz M, Sener M, Aynaci O. Three-headed reversed palmaris longus muscle: a case report and review of the literature. *Surg Radiol Anat*. 2000;22(3-4):217-19.
- [16]. Sharma DK, Shukla CK, Sharma V. Clinical assessment of absence of palmaris longus and its association with gender, body sides, handedness and other anomalies in population of Central India. *Journal of Anatomical Society of India*. 2012;61(1):13-20.
- [17]. McMinn RMH, editor. *Last's Anatomy: Regional and Applied*. 9th ed. London: Churchill Livingstone; 1994.
- [18]. Zeybek A, Gürünlüoğlu R, Cavdar S, Bayramçılı M. A clinical reminder: a palmaris longus muscle variation. *Ann Plast Surg*. 1998;41(2):224-5.
- [19]. Abledu JK, Offei EB. Prevalence of agenesis of palmaris longus muscle and its association with gender, body side, handedness and other anomalies of the forearm in a student population in Ghana. *RMJ*. 2014;39(2):203-7.
- [20]. Murabit A, Gnarra M, Mohamed A. Reversed palmaris longus muscle: Anatomical variant – case report and literature review. *Can J Plast Surg*. 2013;21(1):55-6.
- [21]. Polesuk BS, Helms CA. Hypertrophied palmaris longus muscle, a pseudomass of the forearm: MR appearance – case report and review of the literature. *Radiology*. 1998;207(2):361-2.
- [22]. Depuydt KH, Schuurman AH, Kon M. Reversed Palmaris longus muscle causing effort-related median nerve compression. *J Hand Surg Br*. 1998;23(1):117-9.
- [23]. Bencteux P, Simonet J, el Ayoubi L, Renard M, Attignon I, Dacher JN, et al. Symptomatic palmaris longus muscle variation with MRI and surgical correlation: report of a single case. *Surg Radiol Anat*. 2001;23(4):273-5.
- [24]. Standring S. *Grays anatomy: The Anatomical basis of clinical practice*. 40th ed: Churchill Livingstone; 2008. 1576 p.
- [25]. Kumar N, Patil J, Swamy RS, Shetty SD, Abhinitha P, Rao MK, et al. Presence of multiple tendinous insertions of palmaris longus: a unique variation of a retrogressive muscle. *Ethiopian Journal of Health Sciences*. 2014;24(2):175-8.
- [26]. Park MJ, Namdari S, Yao J. Anatomic variations of the palmaris longus muscle. *Am J Orthop (Belle Mead NJ)*. 2010;39(2):89-94.

How to cite this article: Caio Fernando Cardoso Souza, Lucas Alves Sarmiento Pires, Leonardo de Oliveira de Figueiredo, Claudio Pena Gonçalves, Rodrigo Mota Pacheco Fernandes, Marcio Antonio Babinski. PALMARIS INVERSUS MUSCLE: A CASE REPORT WITH CLINICAL AND SURGICAL DISCUSSIONS. *Int J Anat Res* 2017;5(4.1):4500-4503. DOI: 10.16965/ijar.2017.383