

## Case Report

# BILATERAL VARIATION IN THE CAROTID ARTERIAL SYSTEM: A CASE REPORT

Padmashree.B.R <sup>1</sup>, Radhika P.M <sup>\*2</sup>, Veena Vidyashankar <sup>3</sup>, Shailaja Shetty <sup>4</sup>.

<sup>1</sup> Postgraduate, Department of Anatomy, Ramaiah Medical College, Bangalore, Karnataka, India.

<sup>\*2</sup> Assistant Professor, Department of Anatomy, Ramaiah Medical College, Bangalore, Karnataka, India.

<sup>3</sup> Associate Professor, Department of Anatomy, Ramaiah Medical College, Bangalore, Karnataka, India.

<sup>4</sup> Professor & HOD, Department of Anatomy, Ramaiah Medical College, Bangalore, Karnataka, India.

## ABSTRACT

**Introduction:** Common carotid artery is the most important arterial system which supplies the structures of head and neck region. Variations have been documented with respect to the course, branching and distribution of common carotid artery. Variations in the branching pattern of external carotid artery are also commonly documented. The branches of external carotid artery are important landmarks for adequate exposure and appropriate placement of cross clamps on the carotid artery. It is important for plastic surgeons in order to avoid iatrogenic injuries and create a blood less surgical field.

**Materials and Methods:** During the routine dissection of head and neck region of a 50 year old, male embalmed cadaver in the Department of Anatomy, Ramaiah Medical College during the year 2015-16, a variation in the position and branching pattern of external carotid artery was noted bilaterally. All the variations were documented and digitally photographed.

**Observation:** External carotid artery was anterolateral to internal carotid artery in the lower part of the carotid triangle on both right & left sides. On the right side, superior thyroid artery was arising from common carotid artery. On left side, Superior thyroid artery, ascending pharyngeal artery and the lingual artery were arising from common carotid artery proximal to its bifurcation.

**Conclusion:** A thorough knowledge of variations in carotid arterial system are very much important to surgeons during ligation of the blood vessels at the time of surgeries involving the head and neck region to prevent iatrogenic complications. Knowledge of these variations is also important for radiologist for interpretation of angiograms.

**KEY WORDS:** Common carotid artery, external carotid artery, carotid bifurcation, superior thyroid artery, lingual artery.

**Address for Correspondence:** Dr.Radhika P.M, Assistant Professor, Department of Anatomy, Ramaiah Medical College, MSRIT Post, Bangalore, 560054, India. Phone: 9035044023

**E-Mail:** [parameshradhika@gmail.com](mailto:parameshradhika@gmail.com)

## Access this Article online

### Quick Response code



DOI: 10.16965/ijar.2017.338

**Web site:** International Journal of Anatomy and Research  
ISSN 2321-4287  
[www.ijmhr.org/ijar.htm](http://www.ijmhr.org/ijar.htm)

Received: 07 Jul 2017  
Peer Review: 10 Jul 2017  
Revised: None

Accepted: 16 Aug 2017  
Published (O): 30 Sep 2017  
Published (P): 30 Sep 2017

## INTRODUCTION

The most important arterial system supplying

the head and neck region is the carotid arterial system. On the right side, it is a branch of

brachiocephalic trunk and on the left side, it is a branch of arch of aorta. Each common carotid artery extends upwards and laterally from the steno-clavicular joint to the upper border of the lamina of the thyroid cartilage where it divides into internal carotid artery and external carotid artery. Internal carotid artery is situated posterolaterally and external carotid artery anteromedially in the carotid triangle. There are no branches from internal carotid artery and the common carotid artery in the neck, but external carotid artery will give rise to eight branches: which are Ascending Pharyngeal artery, Superior thyroid artery, Lingual Artery, Facial artery, Occipital artery, Posterior auricular artery, Superficial temporal artery and Maxillary artery [1]. The variations which are most commonly found with respect to the common carotid arteries will be a variation in the level of bifurcation and in the branching pattern. These variations are important for plastic surgeons to get a bloodless field and to avoid iatrogenic injuries during the reconstructive surgeries of head & neck region and also in cervical lymphadenectomy [2,3]. It is of significance to the radiologists in the interpretation of angiograms of head and neck region. The knowledge of the branching pattern of external carotid artery forms the basis for the proper placement of cross clamps on the carotid artery [4]

## MATERIALS AND METHODS

During the routine dissection of head and neck region of a 50 year old, male embalmed cadaver in the Department of Anatomy, Ramaiah Medical College during the year 2015-16, a variation in the position and branching pattern of external carotid artery was noted bilaterally. All the variations were documented and digitally photographed.

## OBSERVATION

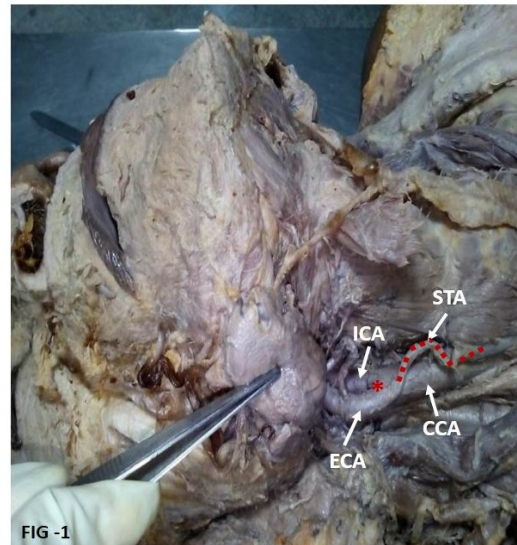
External carotid artery was anterolateral to internal carotid artery in the lower part of the carotid triangle on both right & left sides.

On the right side, superior thyroid artery was arising from common carotid artery.

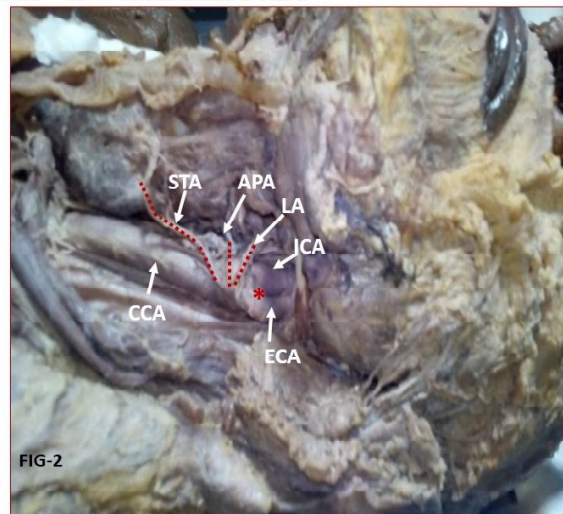
On left side, superior thyroid artery, ascending pharyngeal artery and the lingual artery were arising from common carotid artery proximal to

its bifurcation.

**Fig. 1:** On right side, external carotid artery (ECA) was anterolateral to internal carotid artery (ICA). Superior thyroid artery (STA) was arising from common carotid artery (CCA). Red asterisk indicates the bifurcation of CCA.



**Fig. 2:** On left side, external carotid artery (ECA) was anterolateral to internal carotid artery (ICA). Superior thyroid artery (STA), Ascending pharyngeal artery (APA) and Lingual artery (LA) was arising from common carotid artery (CCA). Red asterisk indicates the bifurcation of CCA.



## DISCUSSION

In the present case report, it has been noted that the external carotid artery was anterolateral to internal carotid artery bilaterally. The anterolateral position of external carotid artery was first reported by the anatomist Hyrtl in 1841. The anterolateral position of external carotid artery and a high bifurcation of common carotid artery can be the causative factor for hypoglossal nerve palsy [5].

The variation in the positioning of external carotid artery reported in various studies has been tabulated in Table 1.

**Table 1:** Previous studies reporting the lateral position of external carotid artery (ECA).

Authors	Studies of lateral position of ECA
Prendens et al [6]	5.30%
Bussaka et al [7]	4.30%
S.B.Rao [8]	A case report
Sujatha Manupathi [5]	A case report

The awareness of variation in the position of the external carotid artery is important in the correct interpretation of intravenous digital subtraction angiography and Doppler scanning images. The ligation of external carotid artery is done during bleeding from terminal branches of external carotid artery & a faulty ligation of internal carotid artery instead of external carotid artery can give rise to serious complications like hemiparesis [2, 9].

Carotid arteries develop from the third aortic arch and dorsal aorta. The common carotid artery develops from ventral part of third aortic arch and the elongation of aortic sac. External carotid artery appears as a new vessel and grows cranially from the aortic sac close to the ventral end of third arch artery. The internal carotid artery develops from third arch artery and dorsal aortae cranial to ductus caroticus [1].

During the eight week of development, the internal carotid artery course straightens out with the descent of dorsal aortic root into the thoracic cavity. Failure of straightening of the carotid vessels will lead to the persistence of embryonic angulations giving rise to a congenitally tortuous internal carotid artery [9]. The medial or lateral external carotid artery migration during development is probably responsible for the variation in positioning of external carotid artery [8].

The common carotid artery occasionally gives rise to vertebral, superior laryngeal, ascending pharyngeal, inferior thyroid or occipital arteries [10]. In the present case report, the superior thyroid artery was arising from common carotid artery bilaterally; ascending pharyngeal & lingual from common carotid artery unilaterally from left side.

The superior thyroid artery originates in 36% from external carotid artery, 18% from common carotid artery and 36% from bifurcation [10].

The variations in the origin of superior thyroid artery, ascending pharyngeal artery & lingual artery from common carotid artery has been reported in Table 2, 3 & 4 respectively.

**Table 2:** Origin of superior thyroid artery (STA) from common carotid artery (CCA) in various studies.

Author	STA FROM CCA
Banna-1990 [11]	10%
Lucev-2000 [12]	47.50%
Takkallapallianitha et al-2011[13]	21%
Abhijeeth joshi-2014[14]	1.51%
Shivaleela-2016 [15]	2.38%
Manjunath-2016[16]	16.66%
Sung you won [17]	70%

**Table 3:** Origin of ascending pharyngeal artery (APA) from common carotid artery (CCA) in various studies.

Author	APA ARISING FROM CCA
Czerwinski [18]	2%
Bergman [10]	7%
Surekha D Jadhav[19]	Case report
Ramesh Rao [3]	Case report

**Table 4:** Origin of lingual artery from common carotid artery (CCA) in various studies.

Author	Lingual artery from CCA
Surekha D Jadhav [19]	Case report
Ramesh Rao [3]	Case report

A thorough knowledge of the anatomy and the variations of the superior thyroid artery, lingual artery & ascending pharyngeal is an important prerequisite to avoid injuries during the thyroid gland surgeries, cricothyroidotomy, extraoral ligation of lingual artery, radical neck dissection, carotid catheterization, reconstruction of aneurysm & carotid endarterectomy [16,17].

**CONCLUSION**

The knowledge of variations in the position and branching pattern of external carotid artery is of importance in specific vascular diagnostic imaging techniques like contrast radiography, duplex ultrasonography and magnetic resonance imaging to avoid misinterpretation. The awareness of these vascular variations is important before planning any surgeries in the cervical region to prevent postoperative complications.

**Conflicts of Interests: None**

## REFERENCES

- [1]. Standring S. Gray's anatomy. The anatomical basis of clinical practice. 40th ed. London: Elsevier Churchill Livingstone;2008.415
- [2]. Navakalyani, Janaki.V, Sumalatha. Variant branching patterns of external carotid artery-pharyngo-occipital trunk and occipito-auricular trunk. Journal of Dental and Medical Sciences 2016; 15(8):44-47.
- [3]. Rao.T.R. Unusual branching pattern of external carotid artery in a cadaver. Chang Gung Med J2011; 34(Suppl 6):24-27.
- [4]. Hayashi N, Hori E, Ohtani Y, Ohtani O, Kuwayama N, Endo S.Surgical anatomy of cervical carotid artery for carotid endarterectomy. Neurol Med Chir (Tokyo).2005 ;45(1):25-9
- [5]. SujathaManupathi, RajuSuganasi, Indiradevi.B, SirishaB, Kanchanalatha.G. Variant anterolateral position of external carotid artery and its clinical significance. Indian journal of basic and applied medical research.2012-June; 1(3): 236-238.
- [6]. PrendensJL, Mc Kinney WM, Buonanno FS, Jones AM. Anatomic variations of the carotid bifurcation affecting the Doppler scan interpretation. J.Clin Ultrasound.1980;8:147-150.
- [7]. BussakaH, SatoN, OguniT, KorogiM, YamashitaY, TakahashiM. Lateral position of ECA.Rhinsho hoshasen.1990;35:1061-3.
- [8]. S.B.Roa,V.R.Vollala,M.Rao,V.P.Samuel,Deepthinath S.Nayak, N.Pamidi. Unusual position of external carotid artery:A case report.Indian journal of Plastic surgery.July –December-2015; 38(2):170
- [9]. Sudeshna Majumdar, Santanu Bhattacharya, PanchananKundu, Kalyan Bhattacharya. Unilateral variation in the position of internal and external carotid arteries. Italian journal of anatomy and embryology.2013; 118:177-183.
- [10]. BergmannBergman RA, Aûû AK, Miyauchi R Opus I: Cardiomuscular : Alpha-betical Listing of Cardiovascular: C, Common carotid artery. In: Bergman RA, Aûû AF, Miyauchi R, editors. Illustrated Encyclopedia of Human Anatomic Variation. Available from: URL: <http://www.anatomyatlases.org/AnatomicVariants/Cardiovascular/Text/Arteries/CarotidCommon.shtml>
- [11]. BannaM, LajauniasP.The Arteries of the Lingual thyroid; Angiographic findings and anatomic variations.AM J Neuro-radiol.1990;11:730-732.
- [12]. LucevN, Babinac D, MaricJ, Dresciki. Variations of the Great arteries in the Carotid triangle. Otolaryngol Head and neck surgery.2000;122:590-591
- [13].Takkallapalli Anitha, Dattatray Dombe, Krishnamurthy Asha, Sanjay Kalbande. Clinically relevant variations of the superior thyroid artery: An anatomic guide for neck surgeries Int J Pharm Biomed Sci 2011, 2(2), 51-54.
- [14]. Abhijeet Joshi, SumitGupta,V.H.Vaniya.Anatomical variation in the origin of superior thyroid artery and its relation with the external laryngeal nerve.National Journal of Medical Research.2014; 4 (2):138-141.
- [15]. Shivaleela C, Anupama. D, Lakshmi prabhasubhash R. Study of anatomical variations in the origin of superior thyroid artery.International journal of anatomy and research.2016;4(1):1765-68.
- [16]. Manjunath.C.S,Tejaswi Hiremarali Lokanathan. Anatomical variations in the origin of superior thyroid artery and its clinical signifance.International journal of anatomy and research.2016;4(3):2656-58.
- [17]. Sung Yoon Won.Anatomical considerations of superior thyroid artery:itsorigin,variations and position relative to hyoid bone and thyroid cartilage.Anat cell boil. 2016 june; 49(2):138-142
- [18]. Czerwinski F. Variability of the course of external carotid artery and its rami in man in the light of anatomical and radiological studies. Folia Morphol 1981;4:449– 454.
- [19]. Surekha. DJadhav. Manoj P Ambali, Raosaheb J.patil. Anatomical variation of the origin of the right lingual artery. International journal of anatomical variations.2011;4:75-76.

### How to cite this article:

Padmashree.B.R, Radhika P.M, Veena Vidyashankar, Shailaja Shetty. BILATERAL VARIATION IN THE CAROTID ARTERIAL SYSTEM: A CASE REPORT. Int J Anat Res 2017;5(3.3):4369-4372. DOI: 10.16965/ijar.2017.338