

Case Report

AN UNIQUE VARIATION OF RIGHT RENAL ARTERY

Hema Nagpal ^{*1}, Renu Chauhan ², Sunita Kalra ³.

^{*1}Senior Resident, Department of Anatomy, University College of Medical Sciences, Delhi, India.

² Professor and Head, Department of Anatomy, University College of Medical Sciences, Delhi, India.

³ Professor, Department of Anatomy, University College of Medical Sciences, Delhi, India.

ABSTRACT

With the advent of laparoscopic renal surgeries and donor nephrectomies, it becomes mandatory for the surgeons to understand the abnormality or variations in the renal vasculature. During routine dissection of the abdominal region for undergraduate medical teaching we observed an unusual variation in the vascular supply of the kidney on the right side of an elderly female cadaver. Main renal artery was arising from abdominal aorta at the level of lower border of L1 and immediately gave off a branch namely right inferior phrenic artery. Approximately 3-4 cm beyond giving this branch main renal artery gave another branch to superior pole of right kidney. The inferior pole of the right kidney was being supplied by another branch which was directly arising from aorta just distal to the first renal artery. No variations were observed in the branching pattern of the left renal artery. This case report discusses the variation of right renal artery observed, which has never been documented. Possible embryological explanation of the variation observed and its clinical implications have been discussed in this article.

KEY WORDS: Renal Artery, Inferior phrenic artery, Renal transplant.

Address for Correspondence: Dr. Hema Nagpal, Senior Resident, Department of Anatomy, University College of Medical Sciences, Delhi, India. Phone: 9999072711

E-Mail: hemanagpal30@gmail.com

Access this Article online

Quick Response code



DOI: 10.16965/ijar.2017.318

Web site: International Journal of Anatomy and Research
ISSN 2321-4287
www.ijmhr.org/ijar.htm

Received: 22 June 2017

Peer Review: 22 June 2017

Revised: None

Accepted: 03 Aug 2017

Published (O): 31 Aug 2017

Published (P): 31 Aug 2017

INTRODUCTION

The renal arteries arise from lateral aspect of the abdominal aorta below the level of superior mesenteric artery at the level of L1 vertebra. The right renal artery is longer in its course due to the location of the abdominal aorta more towards the left side of midline. It passes posterior to the inferior vena cava. Each renal artery divides into anterior and posterior divisions at or very close to the hilum of the kidney. Further each renal artery divides into segmental arteries to supply different renal segments. An accessory renal artery is the one

that is accessory to the main renal artery and enters the kidney through its hilum to supply it, while the aberrant artery supplies the kidney without entering its hilum [1]. Rarely, accessory renal artery arises from either the coeliac or superior mesenteric arteries, the aortic bifurcation or common iliac arteries [1,2]. According to Stephens use of words like accessory or aberrant or supernumerary are misnomer to call these additional arteries as they are not extra but essential tissue-sustaining arteries which corresponds to the segmental branch of a renal artery [3].

Inferior phrenic arteries are two small lateral aortic branches, which supply the diaphragm, but present much diversity in their origin along with presence of supplementary phrenic vessels [4,5]. They may arise either from the front of the aorta immediately above the celiac artery or from a common trunk with the celiac artery. In 8% of the cases, apart from the usual origin, other sources of origin of inferior phrenic arteries may be renal, supra renal, hepatic, left gastric or superior mesenteric arteries [5,6,7]. Because the inferior phrenic often supplies most or all of the blood to the suprarenal gland it must be identified and saved when surgery is performed on the renal pedicle to avoid complications.

Knowledge of these additional renal arteries is very essential so as to prevent any accidental damage to these vessels during surgical reconstruction of the abdominal aorta, renal transplantation, endovascular aneurysm repair, renovascular hypertension and in planning invasive vascular interventional procedures in the renal area.

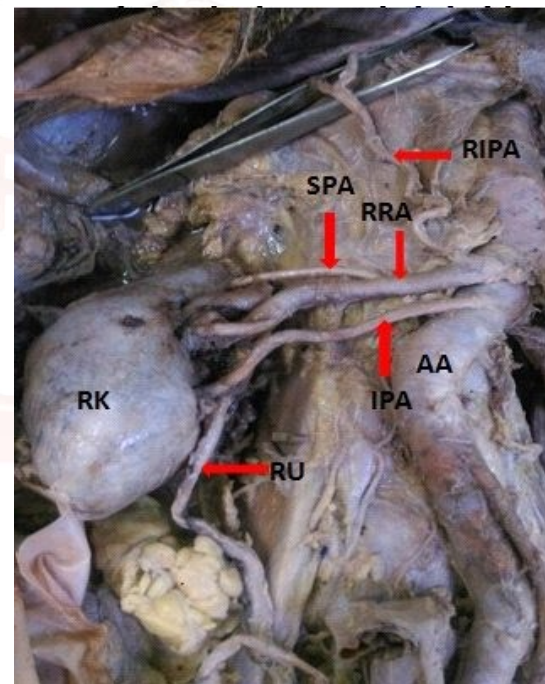
CASE REPORT

During routine dissection of an elderly female cadaver in department of Anatomy at UCMS Medical College, Delhi, additional renal arteries were observed. There were two additional renal arteries supplying the right kidney in addition to customary renal artery. A vertical incision on the anterior abdominal wall was given extending from xiphisternum to the pubic symphysis. The cutaneous and muscular flaps were reflected and the abdominal cavity was opened. After opening the abdominal cavity, both large and small intestines were removed and the structures close to posterior abdominal wall were dissected. All the paired and unpaired branches of the abdominal aorta were studied. In addition to usual branches of the abdominal aorta, it was observed that two additional renal arteries were supplying the right kidney. The right renal artery was seen to be arising from the abdominal aorta slightly below the origin of superior mesenteric artery. This was referred to as the main right renal artery. The trunk of the main right renal artery was resting posteriorly on the right crus of diaphragm, covered anteriorly by Inferior vena cava. It was coursing towards hilum and later it divided into anterior and posterior divisions. This main renal artery gave off right inferior phrenic artery at its origin. Approximately 3-4 cm beyond giving this branch it gave another branch to superior pole of right kidney. One more additional renal artery was present below main renal artery. It was arising from the lateral aspect of aorta, running parallel to main renal artery and entered the lower pole of the kidney. This artery on its way to kidney traversed behind the inferior vena cava and then right renal vein. The ureter was coursing posterior to these vessels (Fig1). The additional vessels were not seen on the left side.

only by Inferior vena cava. It was coursing towards hilum and later it divided into anterior and posterior divisions. This main renal artery gave off right inferior phrenic artery at its origin. Approximately 3-4 cm beyond giving this branch it gave another branch to superior pole of right kidney. One more additional renal artery was present below main renal artery. It was arising from the lateral aspect of aorta, running parallel to main renal artery and entered the lower pole of the kidney. This artery on its way to kidney traversed behind the inferior vena cava and then right renal vein. The ureter was coursing posterior to these vessels (Fig1). The additional vessels were not seen on the left side.

DISCUSSION

Fig. 1: Showing vascular supply of right kidney.



AA- abdominal aorta, RRA- Right renal artery, SPA- Superior polar artery, IPA- Inferior polar artery, RIPA- Right inferior phrenic artery, RK- Right kidney, RU- Right ureter

During a routine dissection, some abnormalities were seen in vascular supply of right kidney in elderly female cadaver. Vasbrinder et al reported that mostly abnormalities of renal artery are seen because of kidneys initially developing in pelvic cavity and then ascending to abdominal cavity in the lumbar region [8]. In pelvic cavity the kidneys are supplied by internal iliac artery or common iliac artery. Whereas when they ascend to the lumbar region, their arterial supply finally shifts to abdominal aorta [9].

In the present case, it was observed that the right kidney was receiving its blood supply from 2 additional renal arteries apart from it receiving its main supply from right renal artery. Additional artery to the superior pole i.e. superior polar artery arose from right renal artery approximately 3-4 cm beyond its origin from abdominal aorta at the level of L1 vertebra. Additional artery that supplied the lower pole of the kidney i.e. inferior polar artery originated directly from abdominal aorta just caudal to origin of right renal artery (Fig 1).

Out of 266 kidneys dissected, Sampaio found 53.3% of kidneys were supplied by single renal artery, 7.3% by 2 hilar arteries, and 1.9% by 3 hilar arteries, 6.8% by extra hilar superior polar artery and 5.3% by extra hilar inferior polar artery [10]. Satyapal studied 130 renal angiograms and vascular supply of kidneys in 32 cadavers. In 23.2% cases he found that 1 additional renal artery was supplying the kidneys. While in 4.5% cases 2 additional renal arteries were supplying the kidneys. From his study he inferred that additional renal arteries are more common on left side as compare to right (32%:23.3%) [11].

Digital subtraction angiogram was performed by Abolhassan et al on a renal transplant donor. Presence of accessory renal artery bilaterally was reported in the angiogram by the authors. Two renal arteries (normal hilar artery and lower polar artery) originated from aorta on the right side. While on the left side, they observed that one normal hilar artery and another accessory renal artery which divided into upper and lower polar arteries that supplied upper and lower poles of the left kidney [12].

Gupta et al compared the vascular supply of kidneys in 30 adult human cadavers with that of vascular supply of kidneys in 30 animals of specified vertebrate series to explain the basis of ontogeny and phylogeny. They found that, in frogs 5 to 6 pairs of renal arteries were supplying kidneys. In domestic fowls, they saw 3 pairs of renal arteries supplied the kidneys of which the cranial pair arose from abdominal aorta and the caudal ones from distal branches of aorta. In lizards, they observed 3 or more pairs of renal arteries. Accessory renal artery was seen to be supplying only 17 kidneys out of 60 studied by them. Only in 1 case it was reported that

of this type of variation was not seen in our study as well. It was also suggested that many conditions which are anomalous in human are normally seen in lower animals [13].

According to Rupert multiple renal arteries in human may be explained from the point of view of phylogeny [14].

As the kidneys ascend from pelvic to abdominal region during their development, they receive their blood supply from the vascular structures close to them. Older vessels degenerate and newer ones sprout. Persistence of the older vessels which were to degenerate may be a possible explanation for the variation observed in the present case.

Hemanth Kommuru studied the vascular supply of 182 kidneys. Out of these, 34 kidneys showed the presence of 1 additional artery, 18 kidneys showed the presence of 2 additional arteries. Both the kidneys were being supplied by additional artery in 20 cadavers. Additional artery was supplying kidney unilaterally in 6 cadavers only in their study [14]. When the additional vessels enter the upper or lower pole of kidney they are termed as "polar arteries [15]. According to Hemanth Kommuru, 23 kidneys showed presence of superior polar artery and 29 kidneys showed presence of inferior polar artery. The author was of the opinion that the additional renal arteries to any of the poles of the kidney could be considered as segmental vessels. However the nomenclature of these arteries is yet not clear as different authors describe them as additional, abnormal or accessory renal arteries [8]. The variation observed in the present case is not consistent with study of Hemanth Kommuru. He observed either superior polar or inferior polar artery supplying the kidney in any particular case whereas superior polar and inferior polar arteries were supplying right kidney at the same time in the present study. Apart from the variation in the origin of renal arteries observed in the present case, inferior phrenic artery origin was also seen to be anomalous. It was seen to be arising from right renal artery as soon as it arose from abdominal aorta. Topaz et al have described finding right and left inferior phrenic arteries originating from a common trunk which in turn originated from right re-nal artery [7].

In the present case it was observed that while the right inferior phrenic artery arose from the right renal artery, the left inferior phrenic artery was a direct branch of abdominal aorta.

The knowledge of embryology of renal vasculature and its development is essential in order to understand the possibilities of multiple anomalies and variations in renal arteries [8]. Keibel divided 9 pair of lateral mesonephric arteries in an 18 mm fetus into cranial, middle and caudal groups. Middle group constitutes 3rd, 4th and 5th pair. This middle group later on remains as renal arteries and that persistence of more than one artery from middle group leads to occurrence of accessory renal artery [16]. A capillary network known as "rete arteriosum urogenitale" has been described to give rise to all definitive renal arteries. Rete arteriosum urogenitale is derived from the segmental lateral splanchnic arteries which branch from aorta and form the proximal portion of this network. These arteries usually regress but their persistence or enlargement may give rise to variations in renal arteries [12,17].

The knowledge of such type of anomaly reported in the present study is important for surgical procedures related to posterior abdominal wall such as renal transplantation, abdominal aorta aneurysm, ureter surgery and angiographic interventions. Surgeons performing renal transplant need to have prior anatomical knowledge of normal renal vasculature and also accessory renal arteries in order to perform successful graft. It has been described that failure to restore circulation in accessory renal artery after surgery may cause unnecessary ischemia or necrosis of renal tissue [18]. Every multiple renal artery is likened to segmental artery so the risk of bleeding during urological surgery or renal transplantation, segmental ischemia and post operative hypertension increases, if the urologist is unaware of its existence [19].

Inferior polar artery in the present case passed superficial to ureter on right side and hence can lead to partial obstruction of ureter leading to hydronephrosis and other associated complications. Surgeons should exclude the possibility of presence of such additional renal arteries obstructing ureter prior to the surgical treatment of hydronephrosis. Although it is very rare,

fibromuscular dysplasia of accessory renal artery (additional renal artery in present case) can be responsible for renovascular hypertension. Selective renal angiography should be performed as gold standard test when renovascular hypertension is considered [20].

Finding multiple variations together in one cadaver as in the present case has not been reported earlier. The variation observed in the present report showed the presence of superior polar artery and right inferior phrenic artery arising from right renal artery and right inferior polar artery arising directly from abdominal aorta. Awareness of the existence of such a variation as seen in the present case is immensely important to renovascular surgeons so as to avoid catastrophic accidental mishaps while operating in renal area.

CONCLUSION

The present case highlighted presence of additional renal arteries entering and supplying the upper and lower pole of kidney. The awareness about the presence of such variation is imperative from the academic, surgical and radiological point of view.

Conflicts of Interests: None

REFERENCES

- [1]. Standring S. Kidney and ureter. In: Gray's Anatomy: The Anatomical Basis of Clinical Practice, 40th ed. edited by Standring S. Edinburgh: Churchill & Livingstone; 2008:1231-1233.
- [2]. Moore KL, Persaud TVN. The urogenital system. In: The Developing Human: Clinically Oriented Embryology, 8th ed. edited by Moore KL, Persaud TVN. Philadelphia, PA: Saunders; 2007; 243-84.
- [3]. Stephens FD. Ureterovascular hydronephrosis and the aberrant renal vessels. J Urol 1982;128(5):984-987.
- [4]. Standring S. Kidney and ureter. In: Gray's Anatomy: The Anatomical Basis of Clinical Practice, 40th ed. edited by Standring S. Edinburgh: Churchill & Livingstone; 2008:1198-1225.
- [5]. Bergman RA, Afifi AK, Miyachi R (2007). Celiac trunk arteries. Illustrated encyclopedia of human anatomic variation. Opus II: cardiovascular system: arteries: abdomen [http://www.Anatomyatlases.org/AnatomicVariants/Cardiovascular/Text/Arteries/CeliacTrunk.shtml].
- [6]. Soni S, Wadhwa A. Multiple variations in the paired arteries of abdominal aorta – clinical implications. J Clin Diagn Res 2010;4:2622- 25.

- [7]. Topaz O, Topaz A, Polkampally PR, Damiano T, King CA. Origin of a common trunk for the Inferior phrenic arteries from the right renal artery. A new anatomic vascular variant with clinical implications. *Cardiovasc Revasc Med* 2010;11:57-62.
- [8]. Vasbrinder GB, Nelemans PJ, Kessels AG, Karoon AA, Maki JH, Leiner T et al. Renal artery diagnostic imaging study in hypertension (RADISH), Study Group: Accuracy of CT, Angiography and MRI for diagnosing renal artery stenosis. *Ann Internal Medicine* 2004;141:624-682.
- [9]. Moore KL, Persaud TVN. The urogenital system. In: *The Developing Human: Clinically Oriented Embryology*, 7th ed. edited by Moore KL, Persaud TVN. Philadelphia, PA: Saunders; 2007; 290-305.
- [10]. Sampaio FJ, Passos MA. Renal arteries: anatomic study for surgical and radiological practice. *Surg Radiol Anat*. 1992;14(2):113-7.
- [11]. Satyapal KS, Haffejee AA, Singh B, Ramsaroop L, Robbs JV, Kalideen JM. Additional renal arteries: incidence and morphometry. *Surg Radiol Anat* 2001;23(1):33-8.
- [12]. Shakeri AB, Tubbs RS, Shoja MM, Pezeshk P, Farahani RM, Khaki AA, et al. Bipolar supernumerary renal artery. *Surg Radiol Anat* 2007;29(1):89-92.
- [13]. Gupta A, Gupta R, Singhla RK. The accessory renal arteries: A comparative study in vertebrates with its clinical implications. *J Clin Diagn Res* 2011;5(5):970-973.
- [14]. Rupert RR. Further study of irregular kidney vessels as found in one hundred eighteen cadavers. *Surg Gynae Obst* 1915; 21:471-480.
- [15]. Kommuru H, Sree Lekha D, Jothi SS, Rajeswararao N, Sujatha N. Presence of renal artery variations and its surgical correlation. *Int J Clin Med Res* 2012;3(5):176-179.
- [16]. Khamanarong K, Prachaney P, Utraravichien A, Tong-Un T, Shripaoraya LX. Anatomy of renal arterial supply. *Clin Anat* 2004;17(4):334-336.
- [17]. Kiebel F, Mall FP. *Manual of Human Embryology*. Philadelphia; Lippincott Crowell, 1912.
- [18]. Gesase AP. Rare origin of Supernumerary Renal vessels supplying the lower pole of the left kidney. *Am Anat* 2007;189(1):53-58.
- [19]. Beata P, Andrew B. Accessory right renal artery – a case report. *Int J Anat Variat* 2009;2:119-121.
- [20]. Zeina AR, Vladimir W, Barmeir E. Fibromuscular dysplasia in an accessory renal artery causing renovascular hypertension: a case report. *J Med Case Rep* 2007;1:58.

How to cite this article:

Hema Nagpal, Renu Chauhan, Sunita Kalra. AN UNIQUE VARIATION OF RIGHT RENAL ARTERY: A CASE REPORT. *Int J Anat Res* 2017;5(3.2):4303-4307. DOI: 10.16965/ijar.2017.318