

MORPHOMETRIC STUDY OF POSTERIOR INTEROSSEOUS NERVE TO DETERMINE ITS UTILITY IN NERVE GRAFTING

Aditya Krishna Das ^{*1}, Anand L Kulkarni ², Raviprasanna.K.H ³.

^{*1} Assistant Professor, Department of Anatomy, Sree Narayana Institute of Medical Sciences, North Kuthiathode, Chalakka, Ernakulam, Kerala, India.

² Professor and Head, Department of Anatomy, Sree Narayana Institute of Medical Sciences, North Kuthiathode, Chalakka, Ernakulam, Kerala, India.

³ Assistant Professor, Department of Anatomy, Sree Narayana Institute of Medical Sciences, North Kuthiathode, Chalakka, Ernakulam, Kerala, India.

ABSTRACT

Background: The posterior interosseous nerve (PIN) is considered an ideal nerve for nerve grafting to bridge digital nerve lesions as it has minimal morbidity due to sensory loss. This study was conducted to identify the length of the nerve available for grafting by measuring the PIN from its last muscular branch to the pseudoganglion and to the Lister's tubercle.

Materials and Methods: The length of the PIN was measured from its last muscular branch using Vernier's callipers in previously dissected upper limbs which were used for routine MBBS dissection teaching.

Results: The mean length of PIN available for grafting was 4.71 cm to the pseudoganglion and was found 6.13 cm above the Lister's tubercle.

Discussion: Since the PIN as a nerve graft shows less deficits post operatively, it is considered an ideal candidate for nerve grafting. In our study, we have found that the available length of grafting is about 4cm which is ideal for replacing digital nerves.

Conclusion: This study shows that a nerve length of 3-5 cm could be available for nerve grafting while using the PIN. The nerve can be usually located 5-7 cm above the Lister's tubercle. Hence, it is easily located and a good candidate for replacing digital nerves in the hand.

KEY WORDS: Posterior Interosseous nerve, Nerve Graft, Lister's tubercle, Radial nerve.

Address for Correspondence: Dr. Aditya Krishna Das, Assistant Professor, Department of Anatomy, Sree Narayana Institute of Medical Sciences, North Kuthiathode, Chalakka, Ernakulam, Kerala-683594, India. Phone no- +918589851223, **E-Mail:** adityakdas@gmail.com

Access this Article online

Quick Response code



DOI: 10.16965/ijar.2017.242

Web site: International Journal of Anatomy and Research
ISSN 2321-4287
www.ijmhr.org/ijar.htm

Received: 26 Apr 2017
Peer Review: 28 Apr 2017
Revised: None

Accepted: 06 Jun 2017
Published (O): 30 Jun 2017
Published (P): 30 Jun 2017

INTRODUCTION

Peripheral nerve injuries are commonly observed in the superior extremity, mainly due to traumatic causes. Autogenous nerve graft is a procedure of taking a nerve graft from the patients' body and using it in the same patient

in a functionally important area. The PIN has been found to be useful source of nerve graft for digital nerve grafts as the terminal part of the nerve has no cutaneous branches [1]. A study done by Reissis et al which measured the diameter and fascicle count of the PIN showed that

it is an ideal nerve to replace digital nerves [2]. PIN passes between the fibres of the supinator muscle to reach the posterior compartment of the forearm where it supplies all the muscles of deep group of extensor compartment of forearm. Segment of the nerve between its last muscular branch and the pseudoganglion can be used for nerve grafting. This study was conducted to determine the length of the nerve available for grafting and the proximal extent of the nerve from the Lister's tubercle.

MATERIALS AND METHODS

28 previously dissected upper limbs were used in this study. These limbs were subjected to routine dissection to educate medical undergraduate students at the Sree Narayana Institute of Medical Sciences, Chalakka. PIN was identified in the posterior compartment of the forearm. Last muscular branch from the PIN was identified. Starting of the last muscular branch from PIN was considered as point A. The proximal edge of the pseudoganglion was considered as point B. Tip of Lister's tubercle was considered as point C.

The length of the nerve was measured using Vernier callipers:

1. Length of the nerve from its last muscular branch to the tip of Lister's tubercle (point A to point C).
2. Length of the nerve from the last muscular branch to the upper margin of pseudoganglion (point A to point B).

Limbs with obvious deformities, damaged nerves and limbs with surgical scars were excluded.

Fig. 1: Points used for measuring the posterior interosseous nerve

A - Last Muscular branch
 B - Proximal margin of pseudoganglion
 C - Tip of Lister's tubercle

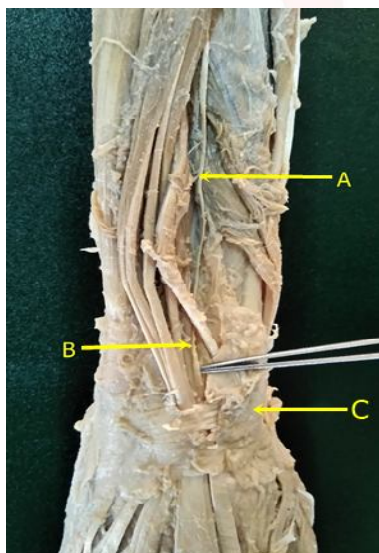


Table 1: Measurement from Point A to Point C.

Number of specimens	Mean	Standard Deviation	Range
28	4.72	1.43	3.29 – 6.15

Table 2: Measurement from Point B to Point C.

Number of specimens	Mean	Standard Deviation	Range
28	6.13	1.43	4.7 – 7.56

DISCUSSION

Mean length of the PIN from its last muscular branch to the pseudoganglion was found to be 4.71 +/- 1.43 cm (Table 1). Mean length of the PIN from its last muscular branch to the tip of Lister's tubercle was 6.13 +/- 1.43cm (Table 2). PIN is the deep terminal branch of the radial nerve. It supplies supinator and then passes between the two heads of the supinator muscle. As it emerges from supinator posteriorly, the nerve gives off three short branches to extensor digitorum, extensor digiti minimi and extensor carpi ulnaris and two longer branches; medial branch to extensor pollicis longus and extensor indicis and lateral branch that supplies abductor pollicis longus and extensor pollicis brevis. After giving out last muscular branch, PIN becomes slender and descends on posterior side of the interosseous membrane to the dorsum of the radius. Filaments arising from its flattened termination (pseudoganglion) supply the carpal ligaments and articulations [3]. Elgafy et al found that at a mean distance of 8.1 +/- 1.2 cm proximal to tip of Lister's tubercle the nerve gave off its last muscular branch to the extensor pollicis longus and becomes a pure sensory terminus. Their study showed that the mean length obtainable for harvesting is 6.2 +/- 0.7 cm [4]. In our study the last muscular branch was found to be 6.14 +/- 1.43 cm from the tip of Lister's tubercle. Jariwala et al found that the last motor branch was given off 4.69 +/- .84 cm from the most proximal part of the ulnar head [5]. We have used the tip of Lister's tubercle in our study as the anatomical landmark provides measurement in a straight vertical line. Reissis et al in their study found a mean obtainable length of 3.71 cm. In our study the length of the nerve available was found to be 4.71 +/- 1.43 cm when measured to the pseudoganglion. Hence 3 to 5 cm graft could be available for grafting.

The cross sectional area of PIN was similar to digital nerve and hence can be used for finger-tip grafts [6]. It is also easy to procure surgically with minimal morbidity [7]. Variations of PIN for example PIN giving branch to superficial branch of radial nerve should also be tested for before harvesting it [8]. No such variation was found in our study.

CONCLUSION

PIN is considered to be an ideal nerve for digital nerve grafting hence determining the available length for grafting and a suitable anatomic landmark to approach the nerve are important. In our study, we found that a 3 to 5 cm graft could be available for grafting and the last muscular branch of the nerve is commonly given 5 to 7 cm away from the tip of Lister's tubercle.

ABBREVIATIONS

PIN - Posterior Interosseous Nerve

ACKNOWLEDGEMENTS

We wish to thank the teaching and non-teaching staff from the Department of Anatomy, Sree Narayana Institute of Medical Sciences, Ernakulam for suggestions and advice that helped us to a great extent.

Conflicts of Interests: None

REFERENCES

- [1]. Waters PM, Schwartz JT; Posterior interosseous nerve: an anatomic study of potential nerve grafts. The Journal of Hand Surgery 1993;18(4):743-745.
- [2]. N. Reissis, A. Stirrat, S. Manek, M. Dunkerton; The terminal branch of posterior interosseous nerve: A useful donor for digital nerve grafting. The Journal of Hand Surgery 2014.
- [3]. Susan Standring. Elbow and forearm. In Gray's Anatomy. 41st edition. Chapter 49. Page 860.
- [4]. Elgafy H, Ebraheim NA, Yeasting RA; The anatomy of the posterior interosseous nerve as a graft. J Hand Surg Am. 2000;Sep;25(5):930-5.
- [5]. Jariwala A, Krishnan B, Soames R, Wigderowitz CA; Important anatomical relationships of the posterior interosseous nerve in the distal forearm for surgical planning: a cadaveric study. Journal of Wrist Surgery, 2014;3(1):60-63.
- [6]. Higgins JP, Fisher S, Serletti JM, Orlando GS. Assessment of nerve graft donor sites used for reconstruction of traumatic digital nerve defects. The Journal of Hand Surgery 2002;27(2):286-292.
- [7]. James Chang, Peter C. Meligan. Plastic surgery: Volume 6: hand and Upper limb.
- [8]. Rao T.R., Madhyastha S. Variation in the distribution of the posterior interosseous nerve – a case report. J Anat. Soc. India. 2001;50(1):46.

How to cite this article:

Aditya Krishna Das, Anand L Kulkarni, Raviprasanna.K.H. MORPHOMETRIC STUDY OF POSTERIOR INTEROSSEOUS NERVE TO DETERMINE ITS UTILITY IN NERVE GRAFTING. Int J Anat Res 2017;5(2.3):4012-4014. DOI: 10.16965/ijar.2017.242