

MORPHOMETRIC ANALYSIS OF BICIPITAL GROOVE OF UPPER END OF HUMERUS IN SOUTH INDIAN POPULATION

Ashwini. N.S ^{*1}, Venkateshu.K.V ².

^{*1} Assistant Professor, Department Of Anatomy, Sri Devaraj Urs Medical College, Tamaka, Kolar, Karnataka, India.

² Professor And Head, Department Of Anatomy, Sri Devaraj Urs Medical College, Tamaka, Kolar, Karnataka, India.

ABSTRACT

Introduction: The Bicipital Groove (BG) or intertubercular groove in the upper end of the humerus is a deep groove formed between the greater and lesser tubercles. This groove lodges the long tendon of the Biceps brachii and also transmits a branch of the anterior humeral circumflex artery. Its lips are called as the crests of the greater and lesser tubercles (bicipital ridges), and form the upper parts of the anterior and medial borders of the body of the bone.

Materials and Methods The study was carried out in 87 adult humeri (39 right and 48 left sides) from the Department of Anatomy, Sri Devaraj Urs Medical college, Tamaka, Kolar, Karnataka. Damaged or bones with deformities were excluded from the study. The length, width, depth were accurately measured using digital vernier callipers. The medial wall angle (MWA) and lateral wall angle (LWA) were measured using goniometer. The parameters were tabulated and statistically analysed.

Results and Discussion: The mean length of BG on right side was 89.94 ± 6.03 mm and 88.88 ± 8.11 mm on left side. The length of medial and lateral walls of BG on the right side was 81.72 ± 6.34 mm and 89.61 ± 6.03 mm respectively and 79.56 ± 7.64 mm and 89.15 ± 8.27 mm on left side. The mean width of BG on right side was 8.53 ± 1.56 and 7.96 ± 1.39 mm on left side. The mean depth of BG on right side was 6.48 ± 1.13 mm and 6.14 ± 1.04 mm on left side. The medial wall angle of BG on the right side was 66.15 ± 13.20 mm and 64.37 ± 18.81 mm on left side. The maximum length of humerus was 32.49 ± 1.83 cm on right side and 31.72 ± 2.03 cm on left side. Supratubercular ridge of Meyer was present in 87.17% of humeri from the right and 85% of those from the left. Medial wall spurs was present in 4.16% of left humeri and absent in right humeri. Bicipital groove spurs was present in 5.12% of right humeri. Type 2 variation of medial wall angle was the commonest and Type 6 was the rare variation similar to observation made by Hitchcock and Bechtol.

Conclusions: Bicipital groove can be used as a landmark for humeral head replacement in fractures of the upper end of the humerus. Osseous spurs and supratubercular ridge may predispose dislocation of tendon of biceps brachii. Therefore the study is important as the knowledge of its morphometry is essential for the selection of prosthetic design, size and position.

KEY WORDS: Bicipital groove, Supratubercular ridge, osseous spurs, groove spurs.

Address for Correspondence: Dr. Ashwini.N.S, Assistant Professor, Department of Anatomy, Sri Devaraj Urs Medical College, Tamaka, Kolar-563101, Karnataka, India.

E-Mail: drashwini2000@gmail.com

Access this Article online

Quick Response code



DOI: 10.16965/ijar.2017.209

Web site: International Journal of Anatomy and Research
ISSN 2321-4287
www.ijmhr.org/ijar.htm

Received: 31 Mar 2017
Peer Review: 01 Apr 2017
Revised: None

Accepted: 08 May 2017
Published (O): 31 May 2017
Published (P): 31 May 2017

INTRODUCTION

The Bicipital Groove (BG) or intertubercular groove in the upper end of the humerus is a deep groove formed between the greater and lesser tubercles. This groove lodges the long tendon of the Biceps brachii and also transmits a branch of the anterior humeral circumflex artery. Its lips are called as the crests of the greater and lesser tubercles (bicipital ridges), and form the upper parts of the anterior and medial borders of the body of the bone [1]. The depth and width of the BG are very important in the retention of tendon of biceps. Several authors reported greater incidence of subluxation and dislocation of tendon of biceps when the BG is shallow. The instability of biceps tendon may be attributed to the lengths of medial and lateral walls, medial wall angles depending on width and depth constituting shallowness of BG, presence of supratubercular ridge and osseous spurs.

Vettivel et al. observed a supratubercular ridge of Meyer in 88% of right and 57% of left humeri, and reported that this ridge is probably more necessary on the right side to prevent medial displacement of the long head of the biceps tendon from the BG [2]. Cone et al., defined the supratubercular ridge as a bony ridge extending proximally from the lesser tubercle more than one-half of the distance to the humeral head. However, in contrast to previous studies, Abboud et al. did not find any conspicuous anatomic findings of the bicipital groove in the shoulders effected by rotator cuff diseases on MRI such as a narrow groove, flat groove, or small medial groove [3]. Levinsohn and Santelli [5] reported that medial dislocation of the biceps tendon may be associated with flattened medial wall of BG [4].

According to Neviasser, supratubercular ridge displaces long head of biceps tendon forward thus favouring anterior displacement. Hence it could be the cause of all primary lesions of Long head of biceps tendon [5].

Variations of humerus is important in orthopedics while operating on a fracture and since there are ethnic variations in the upper end of humerus, the study could be useful in treating fractures suitable for different population groups [6].

AIM AND OBJECTIVES

The aims of the present study are: To determine the length, width, depth of bicipital groove, lateral lip, medial lip of upper end of humerus, length of bicipital groove of upper end of humerus, to determine the medial and lateral angle of bicipital groove, determine the length of humerus, transverse diameter, anteroposterior diameter of humerus at surgical neck of humerus, and also to determine the presence of supratubercular ridges, medial wall and bicipital groove spurs in humerus.

MATERIALS AND METHODS

The study was carried out in 87 adult humeri (39 right and 48 left) from the Department of Anatomy, Sri Devaraj Urs Medical college, Tamaka, Kolar, Karnataka. Damaged or bones with deformities were excluded from the study. The length, width, depth of bicipital groove were accurately measured using digital vernier callipers. The parameters were tabulated and statistically analysed.

The length of the BG was measured from the point between the greater and lesser tubercles to the end of the medial lip of the BG. The depth of the BG was measured between the greater and lesser tubercles. The width of the BG was measured between the medial and lateral lips of bicipital groove. The length of the medial and lateral lips was measured from the tubercles to the respective lips of the BG. The length, transverse diameter and anteroposterior diameter of the humerus were measured. Supratubercular ridge, a bony prominence extending from the lesser tubercle were noted. The presence of medial wall spurs and bicipital grooves were also observed. The data collected were statistically analysed in Mean \pm SD.

Fig.1: Showing measurements of bicipital groove

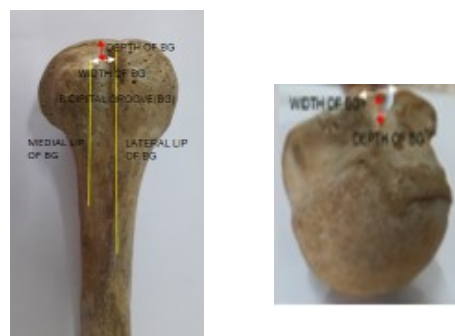


Fig. 2: Showing Medial wall angle(MWA)=abc, Lateral wall angle(LWA)=dbc




Fig.3: Showing Variations of medial wall angle(MWA)




Fig.4: Showing wide bicipital groove.

Fig.5: Showing narrow bicipital groove.

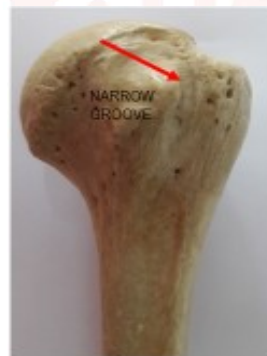
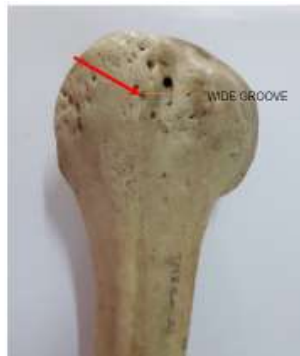
Fig.6: Showing complete supratubercular ridge of Meyer.

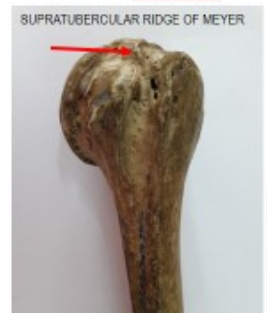

Fig.7: Showing medial wall spur

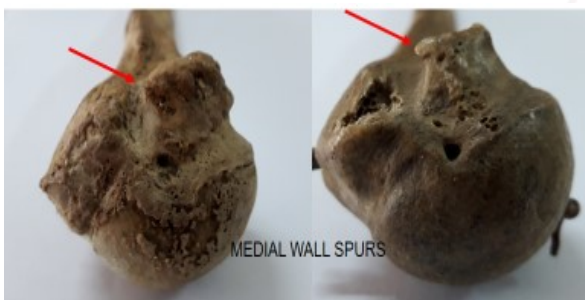
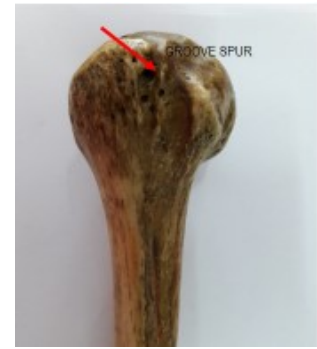

Fig. 8: Showing groove spur



RESULTS

The mean length, medial wall length, lateral wall length, width, depth of bicipital groove, medial wall angle, lateral wall angle of BG are given in Table 1. The medial wall angle of BG on the right side was 66.15 ± 13.20 mm and 64.37 ± 18.81 mm on left side. Supratubercular ridge of Meyer was present in 87.17 % of humeri from the right and 85 % of those from the left. Medial wall spurs was present in 4.16% of left humeri and absent in right humeri. Bicipital groove spurs as present in 5.12% of right humeri. The maximum length of humerus was 32.49 ± 1.83 cm on right side and 31.72 ± 2.03 cm on left side. The length, transverse diameter and anteroposterior diameter of the humerus is more in the right humeri than the left humeri (Table 2). The measurements of the humerus correlated with the morphometric measurements of bicipital groove. The incidence of variations of the angle of the medial wall of the bicipital groove has been studied. Type 2 variation was the commonest and Type 6 was the rare variation similar to observation made by Hitchcock and Bechtol (Table 4).

Table.1: Morphometric measurements of bicipital groove (BG).

	Right humerus (N=39) (MEAN \pm SD)	Left Humerus (N=48) (MEAN \pm SD)
Length of lateral lip (Mm)	89.61 \pm 6.03	89.15 \pm 8.27
Length of medial lip (Mm)	81.72 \pm 6.34	79.56042 \pm 7.64
Length of BG (Mm)	89.94 \pm 6.35	88.88 \pm 8.11
Width of BG (Mm)	8.53 \pm 1.56	7.96 \pm 1.39
Depth of BG (Mm)	6.48 \pm 1.13	6.14 \pm 1.04
Medial Wall Angle (MWA) (Degrees)	66.15 \pm 13.20	64.37 \pm 18.81
Lateral wall angle (LWA) (Degrees)	113.46 \pm 13.23	114.37 \pm 17.40

Table 2: Morphometric measurements of humerus.

	Right humerus (N=39) (MEAN ± SD)	Left Humerus (N=48) (MEAN ± SD)
Length of humerus (cm)	32.49±1.83	31.72±2.03
Transverse diameter of humerus at surgical neck of humerus(mm)	26.74±3.17	26.45±2.54
Anteroposterior diameter of humerus at surgical neck of humerus(mm)	24.55±3.48	23.85±2.46

Table 4: Incidence of variations of the angle of the medial wall of the bicipital groove.

TYPES	Degrees	Right(%) n=39	Left(%) n=48	Incidence according to hitchcock and bechtol 1948 [23]
TYPE 1	90	2.56%	12.5	23.90%
TYPE 2	75	58.97%	39.58%	27.09%
TYPE 3	60	15.38%	25%	21.70%
TYPE 4	45	23.07%	10.41%	17.39%
TYPE 5	30	-	10.41%	7.30%
TYPE 6	15	-	2.08%	2.10%

Table 3: Comparison of length,width,medial wall angle of bicipital groove with previous studies.

	Wafae et al 2010 [18]	Cone et al 1983 [13]	Abboud et al 2010 [11]	Rajani S et al 2013 [3]		Yamini S Rajan et al 2016 [1]		Present Study	
				Right	Left	Right	Left	Right	Left
Length of lateral LIP (mm)	-	-	-	31 ± 6	31 ± 5			89.6 ± 6.03	89.15 ± 8.27
Length of medial lip (mm)	-	-	-	22 ± 4	23 ± 5			81.72 ± 6.34	79.56 ± 7.64
Length of BG (mm)	81			85 ± 09	83±10.1	84.79 ± 5.84	87.33 ± 6.40	89.94 ± 6.31	88.8 ± 8.11
Width of BG (mm)	10.1	8.8		9.0 ± 2.1	8.9 ± 1.1	6.84 ± 1.01	7.74 ± 1.96	8.53 ± 1.56	7.96 ± 1.39
Depth of BG (mm)	4	4.3	5.1	5.0 ± 1.0	6 ± 1.0	4.21 ± 0.58	4.21 ± 0.58	6.48 ± 1.13	6.14 ± 1.04
MWA (degrees)	-	-	-	47.34 ± 9.61	50.85 ± 10.93	-	-	66.15 ± 3.20	64.37 ± 18.81

DISCUSSION

The Bicipital groove prevents the Long head of biceps tendon [LBT] from dislocating during movement of the arm. The spectrum of abnormalities includes tenosynovitis, pulley lesions, biceps dislocations, and proximal tears. [7]. Vettivel et al reported that the length of the humerus correlated with the width and the depth of the bicipital groove. A more acute angle of the medial wall as seen more often in bicipital groove on the right could permit a greater medial displacement of the long head tendon. Such a medial displacement is prevented by the supratubercular ridge of Meyer [8,9]. Pfahler et al [10] revealed great variation in the medial wall angle of the groove in radiographs, whereas width, depth, and humeral head diameter showed sex-related differences. In our study medial wall angle of the bicipital groove on right and left humerus were 66.15mm and 64.37 mm respectively and is more than that reported by Rajani et al The medial and lateral wall length in the present study does not match with the earlier reports and shows huge difference (Table 3).

Abboud et al.[11] hypothesized that there would be a correlation between bicipital groove morphology and the intraoperative finding of biceps pathology. Assessment of the intra-articular and intertubercular regions of the long tendon of the biceps forms an important aspect of routine glenohumeral arthroscopic examination. A new technique of direct visualization of the bicipital groove and tendon by positioning the arthroscope in linear alignment with the bicipital groove was described by Bhatia et al[12]. Cone et al[13] noted bony excrescences forming on medial wall of bicipital groove as medial wall spurs and bony excrescences forming within the inferior one half of intertubercular sulcus were recorded as groove spurs.

Farin et al.[14] compared ultrasonography (US) and plain radiography in the evaluation of the bicipital groove of the humerus and determined the accuracy of US in measurement of the width and depth of the groove compared to plain radiography. The dimensions and morphology of a critical zone of the intertubercular sulcus (ITS) of the humerus were observed by Ueberham et al[15].The critical zone extended from the first

perceptible proximal depression to the distal extremity of the lesser tubercle[15].

Vettivel S et al. [16] studied intertubercular sulcus of the humerus as an indicator of handedness and humeral length. . Previous studies of BG shape variation primarily involved taking 2-dimensional (2D) measurements from a single axial cross section of the humerus[17].

Wafae et al[18] reported the average length of the groove as 8.1 cm which corresponded to 25.2% of the length of the humerus. The width at the midpoint of the groove was 10.1 mm and corresponded to 49.7% to 54.5% of the width of the humerus. The depth was 4.0 mm and corresponded to 18.8% of the depth of the humerus. The mean angle formed by the groove lips was 106 degrees . In the present study ,the mean width of the groove was 8.53mm and 7.96 mm on right and left side and corresponded to 31.89% and 30.09 % of the width of humerus at surgical neck. The length of the bicipital groove corresponded to 27.6 % (right) and 27.9%(left) of the length of humerus.The length of bicipital groove, length of medial lip and lateral lip of bicipital groove was more in the right humeri than the left humeri. The mean width of the bicipital groove was greater in the right humeri compared to the left humeri. The mean depth of the bicipital groove in right-sided humeri was slightly more than on the left .

The mean angle of the medial wall was more in right-sided humeri .The mean angle of the lateral wall was slightly more in left-sided humeri. With use of computerized tomographic data and three-dimensional computer modeling, Robertson et al. studied both extramedullary and intramedullary humeral morphology, including canal shape, and related these findings to the design of proximal humeral prostheses[19]. The shape of the groove has often been implicated in the pathogenesis of biceps tendon ruptures. A shallow, flattened groove is commonly associated with subluxation or dislocation of the biceps tendon, and a narrow groove with a sharp medial wall and an osteophyte at the aperture is often associated with biceps tendinitis and rupture. Spurs on the floor of the groove can erode the tendon [20].

Hitchcock and Bechtol defined six variations of

the angle of the medial wall of the bicipital groove [21].

Type 1 grooves had an angle off 90 degrees.

Type 2 grooves had an angle of 75 degrees.

Type 3 grooves had an angle of 60 degrees.

Type 4 grooves had an angle of 45 degrees.

Type 5 grooves had an angle of 30 degrees.

Type 6 grooves had an angle of 15 degrees.

Anudeep Singh et al.[22] reported the height of humerus as 306.41 ± 25.8 mm on the right bone and 304.43 ± 23.4 mm on the left bone. In the upper third the mean circumference of the shaft was 60.6 ± 6.6 mm and 58.85 ± 6.0 mm whereas the mean transverse diameter was 18.6 ± 2.1 mm and 18.2 ± 2 mm on right and left sides respectively.

CONCLUSION

Bicipital groove is present in the shoulder region where wide range of movements occurs. It can also be a used as a landmark for humeral head replacement in fractures of the upper end of the humerus.The present study adds more information on the morphometry of bicipital groove, variations of medial wall angle and supratubercular ridge. Osseous spurs and supratubercular ridge may predispose dislocation of tendon of biceps brachii. Therefore the study is important as the knowledge of its morphometry is essential for the selection of prosthetic design, size and position.

Conflicts of Interests: None

REFERENCES

- [1]. Yamini Soundararajan, Senthil Kumar Sampath Kumar. Morphometric Study on Bicipital Groove among South Indian Population. Journal of Clinical and Diagnostic Research. 2016;10(7):AC01-AC03.
- [2]. B V Murlimanju, Latha V. Prabhu, Mangala M Pai et al. Anthropometric Study of the Bicipital Groove in Indians and its Clinical Implications. Chang Gung Med J. 2012;35(2):155-159.
- [3]. Singh Rajani, Singh Man. Review of Bicipital Groove Morphology and Its Analysis in North Indian Population. Hindawi Publishing Corporation ISRN Anatomy. 2013.
- [4]. Phalguni Srimani , Ritaban Saha , Biplab Goswami et al. Morphometric Analysis of Bicipital Groove of Humerus with its clinical implications: A study in West Bengal. Int J Anat Res.2016;4(4):3009-15.

- [5]. Arunkumar K R, Manoranjitham R , Delhi Raj U et al. Morphometric Study of Bicipital Groove In South Indian population and its clinical implications. *Int J Anat Res.* 2016; 4(2):2187-91.
- [6]. Priya Ranganath, Balasubramanyam V et al. Variations in measurements of Upper and Lower Ends of Humerus. *South Asian Anthropologist.* 2011;11(2): 181-183.
- [7]. Maninder Kaur, Rimpi Gupta. Morphometric & morphological study of Bicipital Groove in North Indian Population. *International Journal of Basic and Applied Medical Sciences .* 2015;5(3):48-53.
- [8]. Selvakumar Vettivel, Indrasingh G. Chandi S. M. Chandi. Variations in the intertubercular sulcus of the humerus related to handedness. *J. Anat.*1992;180:321-326.
- [9]. Susan standing, *Grays Anatomy: the anatomical basis of clinical practice, 40th edition, Edinburgh: Elsevier Churchill Livingstone: 2008.*796-798.
- [10]. Pfahler M, Branner S, Refior HJ. The role of the bicipital groove in tendinopathy of the long biceps tendon. *J Shoulder Elbow Surg.* 1999;8:419-24.
- [11]. Abboud JA, Bartolozzi AR, Widmer BJ, DeMola PM. Bicipital groove morphology on MRI has no correlation to intra-articular biceps tendon pathology. *J Shoulder Elbow Surg.* 2010 ;19(6):790-4.
- [12]. Bhatia DN, Van Rooyen KS, De Beer JF. Direct arthroscopy of the bicipital groove: a new approach to evaluation and treatment of bicipital groove and biceps tendon pathology. *Arthroscopy.* 2008;24(3):368.
- [13]. Cone RO, Danzig L, Resnick D, Goldman AB. The bicipital groove: radiographic, anatomic and pathologic study. *AJR Am J Roentgenol.* 1983;141:781-88.
- [14]. Farin PU, Jaroma H. The bicipital groove of the humerus: sonographic and radiographic correlation. *Skeletal Radiol.* 1996;25(3):215-9.
- [15]. Ueberham K, Le Floch-Prigent P. Intertubercular sulcus of the humerus: biometry and morphology of 100 dry bones. *Surg Radiol Anat.* 1998;20(5):351-4.
- [16]. Vettivel S, Selvaraj KG, Chandi SM, Indrasingh I, Chandi G. Intertubercular sulcus of the humerus as an indicator of handedness and humeral length. *Clin Anat.* 1995;8(1):44-50.
- [17]. Aaron D. Ward, Ghassan Hamarneh, Mark E. Schweitzer. 3D Bicipital Groove Shape Analysis and Relationship to Tendopathy. *J Digit Imaging.* 2008 ;21(2):219-34.
- [18]. Wafae N, Atencio Santamaria LE, Vitor L, Pereira LA, Ruiz CR, Wafae GC. Morphometry of the human bicipital groove (sulcus intertubercularis). *J Shoulder Elbow Surg.* 2010;19(1):65-8.
- [19]. Robertson DD, Yuan J, Bigliani LU, Flatow EL, Yamaguchi K. Three-dimensional analysis of the proximal part of the humerus: Relevance to arthroplasty. *Journal of Bone and Joint Surgery.* 2000; 82(11):1594–602.
- [20]. Wayne Z. Burkhead, Jr., MD, Peter Habermeyer, MD, Gilles Walch, MD, Kenneth Lin, MD. *Musculoskeletal key. The Biceps Tendon. Chapter 26.*
- [21]. Wayne Z. Burkhead, Jr., MD, Peter Habermeyer, MD, Gilles Walch, MD, Kenneth Lin, MD. *Musculoskeletal key. Gross Anatomy of the Shoulder. Chapter 2.*
- [22]. Anudeep Singh, Mahindra Nagar, and Anil Kumar. *An Anthropometric Study of the Humerus in Adults. Research & Reviews: Journal of Medical and Health Sciences.*2014.
- [23]. Hitchcock H H, Bechtol C O. Painful shoulder. Observations on the role of the tendon of the long head of the biceps brachii in its causation. *J Bone Joint Surg (Am)* 1948;30:263-73.

How to cite this article:

Ashwini. N.S, Venkateshu.K.V. MORPHOMETRIC ANALYSIS OF BICIPITAL GROOVE OF UPPER END OF HUMERUS IN SOUTH INDIAN POPULATION. *Int J Anat Res* 2017;5(2.2):3870-3875. **DOI:** 10.16965/ijar.2017.209