

MORPHOLOGICAL STUDY OF ACCESSORY FORAMEN TRANSVERSARIUM IN DRIED CERVICAL VERTEBRAE IN HUMAN BEING

Sudarshan Gupta ^{*1}, Zarna Patel ², Rupal S. Gautam ³.

^{*1} Associate Professor, Department of Anatomy, GMERS Medical College, Gandhinagar, Gujarat, India.

² Assistant Professor, Department of Anatomy, GMERS Medical College, Gandhinagar, Gujarat, India.

³ Associate Professor, Department of Anatomy, B.J. Medical College, Ahmedabad, Gujarat, India.

ABSTRACT

Introduction: The cervical vertebra has a characteristic feature that is presence of foramen in transverse process. Out of seven cervical vertebrae third, fourth, fifth and sixth typical cervical vertebrae and first, second and seventh atypical cervical vertebrae. In all except the seventh cervical vertebra, the foramen transversarium normally transmits the vertebral artery and vein and a branch from the cervicothoracic ganglion. Variation in foramina transversarium had been observed by various researchers in the form of its number (Accessory foramina transversarium /AcFT), size and shape.

Materials and Methods: In this study total 248 cervical vertebrae were observed macroscopically for the presence of AcFT. Out of 248 cervical vertebrae 139 typical and 109 atypical (37 – C1, 37 – C2 and 35 were C7).

Results: Accessory foramina transversarium observed in 49(19.76%) cervical vertebrae (21 bilateral and 28 unilateral AcFT).

Conclusion: Knowledge of variation in foramina transversarium is clinically important for neurosurgeons, radiologist for interpretation of CT Scan and MRI.

Key Words: Cervical Vertebrae, Foramina Transversarium, Accessory Foramina Transversarium, Vertebral Artery, Vertebral Vein.

Address for Correspondence: Dr. Sudarshan Gupta, Associate Professor, Department of Anatomy, GMERS Medical College, Gandhinagar, Gujarat, India. Contact No.: 08980038090 / 09426372356
E-Mail: drsudarshangupta@yahoo.com

Access this Article online

Quick Response code



DOI: 10.16965/ijar.2017.180

Web site: International Journal of Anatomy and Research
ISSN 2321-4287
www.ijmhr.org/ijar.htm

Received: 09 Mar 2017

Peer Review: 10 Mar 2017

Revised: None

Accepted: 15 Apr 2017

Published (O): 31 May 2017

Published (P): 31 May 2017

INTRODUCTION

In human being vertebral column made up of approximately 33 vertebrae, which are subdivided into five groups based on morphology and location. These are 7 cervical vertebrae, 12 thoracic vertebrae, 5 lumbar vertebrae, 5 sacral vertebrae (fused into one single bone called the sacrum) and usually four coccygeal vertebrae

(fuse into a single small triangular bone called the coccyx). A typical vertebra has a vertebral body and a posterior vertebral (neural) arch. The vertebral arch of each vertebra consists of pedicles and laminae and processes (transverse, spinous, superior and inferior articular processes) [1].

The cervical vertebra has a characteristic feature that is presence of foramen in transverse process. Out of seven cervical vertebrae third, fourth, fifth and sixth have almost identical features considered as typical cervical vertebrae and first, second and seventh have special features considered as atypical cervical vertebrae.

A typical cervical vertebra has small, relatively broad vertebral body and short and bifid spinous process ('spine'). The transverse process has the foramen transversarium and its dorsal and ventral bars terminate laterally as anterior and posterior tubercles. These tubercles are connected by the costal (or intertubercular) lamella that forms lateral boundary foramen transversarium. Three elements of transverse process represent morphologically the capitellum, tubercle and neck of a cervical costal element. The morphological transverse process represented by attachment of the dorsal bar to the pediculolaminar junction. In all except the seventh cervical vertebra, the foramen transversarium normally transmits the vertebral artery and vein and a branch from the cervicothoracic ganglion (vertebral nerve).

First cervical vertebra also called as Atlas supports the head. Its characteristic features are two lateral mass connected by two arches (anterior and posterior) and absence of body. Its transverse processes are longer than those of other cervical vertebrae except the seventh.

The Second Cervical Vertebra also called as Axis vertebra characterised by presence of dens a conical projection on superior surface of body of vertebra and presence of large ovoid articular facet on either side of dens at the junction of body and neural arch.

The seventh cervical vertebra has a long Spinous process. It ends in a prominent tubercle for the attachment of the Ligamentum nuchae, Foramina transversarium transmit vertebral veins, but not the vertebral artery, and each is often divided by a bony spicule [2].

Each vertebra developed from Centrum (Vertebral body) and bilateral neural arches. Close to the Centrum each neural arch gives rise to costal element which extends laterally through the segmental myotomes [3].

The vertebral artery arises from first part of the subclavian artery. Second part of it passes through the foramina transversarium of all of the cervical vertebrae except the seventh. It enters in cervical vertebral column via 6th cervical vertebra. But occasionally it may enter via the foramina transversarium of fourth, fifth or seventh cervical vertebra. In transverse foramina second part of vertebral artery accompanied by a branch from the inferior cervical ganglion and a plexus of veins which form the vertebral vein low in the neck. It lies anterior to the ventral rami of the cervical spinal nerves (C2–C6) [2].

Presence of AcFT (Accessory foramen transversarium) may affect the course of vertebral artery that may leads to its compression. Vertebral vascular insufficiency may results in headache, migraine and fainting attacks [4].

For spinal surgeons it is very important to know the possible variation in the course of vertebral vessels while performing cervical spinal surgeries because a minor lesion in the vertebral vessels may leads to serious hemorrhage [5].

Knowledge of such kind of variations are also useful for the radiologist while interpretation of computed tomography and magnetic resonance imaging.

MATERIALS AND METHODS

This study was conducted on 259 dried adult human cervical vertebrae of unknown sex were obtained for this study from Department of Anatomy, GMERS Medical College Gandhinagar in 2016. Cervical vertebrae with damaged transverse process were not considered for this study. After exclusion, total 248 vertebrae were selected for study. All these cervical vertebrae were separated as typical (139 vertebrae) and atypical (1st, 2nd and 7th - total 109 vertebrae) cervical vertebrae. Presence or absence, complete or incomplete AcFT and number of AcFT were carefully observed at transverse process of cervical vertebrae.

RESULTS

Out of 248 Cervical vertebrae (CV) 37 atlas (1st cervical), 37 axis (2nd cervical), 139 typical and 35 7th cervical vertebrae were considered for study (139 typical and 109 atypical). Foramina transeversarium were present in all these

cervical vertebrae. Out of 248 cervical vertebrae having AcFT found in 49 CV (38 typical and 11 atypical CV). Among atypical vertebrae AcFT absent in 1st and 2nd CV and only 7th CV found with presence of AcFT.

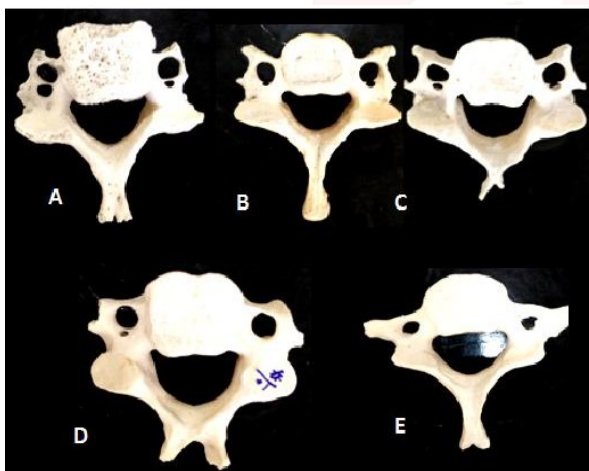
Bilateral AcFT observed in 21 CV (8.47 %) (19 typical and 2 atypical CV).

Unilateral Ac FT observed in 28 CV (10.89 %) (19 typical and 9 atypical CV).

Table 1: Classification of CV with AcFT.

Category		Typical C. V.		Atypical	
		3 rd , 4 th , 5 th and 6 th C. V. (139)	1 st C. V. (37)	2 nd C. V. (37)	7 th C. V. (35)
Bilateral	Complete	5	0	0	0
	One side complete and other side incomplete	7	0	0	2
	Incomplete	7	0	0	0
	Multiple	0	0	0	0
Unilateral	Complete	9	0	0	5
	Incomplete	10	0	0	4
	Multiple	0	0	0	0

Fig. 1: Classification of CV with AcFT.



A. Bilateral Complete, B. Bilateral Incomplete, C. Bilateral one side complete and other side incomplete, D. Unilateral complete E. Unilateral incomplete

Table 2: Presence of Ac FT right and left side of CV.

Type of AcFT	Typical C.V.		Atypical C.V.		Total
	Right	Left	Right	Left	
Complete AcFT	17	9	5	2	33
Incomplete AcFT	10	21	4	2	37
Total	27	30	9	4	70

Out of 496 Foramen transversarium 70 (14.11 %) were having Ac FT.

DISCUSSION

Various researchers have reported anatomical variations in the foramina transversarium in its number double or multiple, absence or variation in the size of FT.

In present study we found that out of 248 cervical vertebrae 19.76 % having AcFT. In previous studies done by various researchers Gujar et al [6] 150 CV, Murlimanuj et al[7] 363 CV, Chaudhari et al[8] 210 CV, Das et al[9] 132 CV, Taitz et al[10] 480 CV, Sharma et al[11] 200 CV, Kaya et al [12] 262 CV, Rathnakar et al[13] 140 CV, Shah S. et al[14] 210 CV, Patra A et al[15] 150 CV, Akhtar et al[16] 174 CV, Patil et al[17] 175 CV and Mishra et al[18] conducted study on 220 CV and found incidence of presence of AcFT was 27.33%, 1.6%, 23.15%, 1.5%, 7%, 8%, 22.7%, 5.7%, 16.19 %, 22%, 14.36%, 5.71 % and 14.09% respectively.

In present study we found that in atypical Cervical vertebrae incidence of presence of unilateral AcFT(9 CV) are more common than bilateral AcFTs (2 CV) but in typical cervical vertebrae it is same out of 139 typical Cervical vertebrae 19 having bilateral and 19 having unilateral AcFT.

Table 3: Incidence of presence of bilateral and unilateral AcFT has been compared with previous researchers.

Researchers	No. of CV studies	Unilateral AcFT	Bilateral AcFT
Sharma et al 2010 [11]	200	3.50%	4.50%
Patra A et al 2015 [15]	150	10.67%	11.33%
Mishra et al 2015 [18]	220	4.54%	9.54%
Gujar et al 2015 [6]	150	18%	9.33%
Murlimanju et al 2011 [7]	363	1.30%	0.30%
Chaudhari et al 2013 [8]	133	14.73%	8.42%
Kaya et al 2011 [12]	262	13.63%	9.09%
Rathnakar et al 2013 [13]	140	3.60%	1.42%
Shah S. et al 2014 [14]	210	9.52%	6.67%
Akhtar et al 2015 [16]	174	11.49%	2.87%
Patil et al 2014 [17]	175	3.42%	2.28%
Present study	248	10.89%	8.47%

Our study results are similar with the results of most of the researcher that incidence of unilateral AcFT was more common than bilateral. In contrast the results of study conducted by Sharma et al, Patra et al and Mishra et al in which bilateral AcFT were more than unilateral AcFT.

One of the study conducted by Rekha B.S. et al. on 153 dried human 1st cervical vertebrae and she observed double foramina transversarium in 10 atlas vertebrae (7 unilateral and 3 bilaterally) [19]. In present study we have not observed AcFT in atlas vertebrae.

In present study multiple AcFT were not observed but such type of variation had been observed by Rathnakar P et al. during the study on 140 cervical vertebrae she observed that one vertebra having bilateral AcFT right side incomplete and left side multiple foramen were present [13].

First part of vertebral artery extending from subclavian artery to the FT of sixth CV is developed from the dorsal ramus of the seventh cervical intersegmental artery. Second part of it (from FT of sixth CV to first CV) is developed from the enlargement of the longitudinal post costal anastomosis between dorsal rami of upper six cervical intersegmental arteries and consequent regression of stem of upper six intersegmental arteries [3].

A study conducted by Satti S. R. et al in that it was found that duplication of Right vertebral from its origin to the C3 level and it reconstituted at the level of C3. The left vertebral artery was normal. In another case it was observed that anomalous origin of left vertebral artery from aortic arch with an associated duplication of it. Left subclavian artery given origin to second limb and at the level of C7 both the limb unites to form single vertebral artery. Right vertebral artery was normal [20].

It can be supposed that variant FT may be due to variation in the presence and passage of the vertebral vessels [21].

Epstein in their study also observed that in double foramen transversarium, one of the foramen may be occupied by the artery and other by vein or it may be occupied by branches of both vessels [22].

Venous plexus around the second and third part vertebral artery is formed by the numerous small tributaries from internal vertebral plexuses and small veins from deep muscles in the suboccipital triangle. The thin walls of these veins are adhering with the periosteum of the posterior arch of the atlas and the foramina transversarium. From this plexus two vertebral veins usually formed, one vertebral vein that emerge from the sixth with vertebral artery and one accessory vertebral vein through the foramen in the transverse process of C7 vertebra, and join with brachiocephalic vein at the root of the neck [23].

Earlier formation of vertebral vein in foramina transversarium may be responsible for formation of AcFT.

Limitation of study: Variation in the male and female had not been studied.

CONCLUSION

In our study 19.76 % cervical vertebrae having AcFT more common on lower cervical vertebrae. So the knowledge of morphological variation in foramina transversarium is clinically important because presence of the AcFT may distort the course of the vertebral artery. The compression of vertebral artery or its other pathology may lead to neurological symptoms and knowledge of such type of variation is important for the neurosurgeon during posterior cervical surgery, radiologist during interpretation of CT and MRI scan and head and neck and vascular surgeons.

ABBREVIATION

CV - Cervical vertebra

AcFT - Accessory Foramina Transversarium

FT - Foramen Transversarium

Conflicts of Interests: None

REFERENCES

- [1]. Richard L Darke, A. Wayne Vogl, Adam W. M. Mitchell; Gray's Anatomy for students, 3rd Edition, page No. 64-69.
- [2]. Susan, Standring; Gray's Anatomy, The Anatomical basis of clinical Practice; 40th Edition;
- [3]. Datta A K; Essentials of Human embryology; Edition 5th ; Current book international;p-291.
- [4]. Laxami Chandra Vaidya, Shailesh Patel, Jatin Goda. Double foramen transversarium in cervical vertebra morphology and clinical importance. Int.J Res Med.2013;2(1):103-105. ISSN-2320-274
- [5]. An HS, Gordin R, Renner K: Anatomic considerations for plate screw fixation of the cervical spine. Spine 1991;16:548-551.
- [6]. Gujar SM, Oza SG, Shekhawat JP. A Study Of Accessory Foramen Transversarium In Dry Cervical Vertebrae And Its Clinical Implications. National Journal of Integrated Research in Medicine. 2015 Nov 1;6(6):27-3.
- [7]. Murlimanju BV, Prabhu LV, Shilpa K et al. Accessory transverse foramina in the cervical spine: incidence, embryological basis, morphology and surgical importance. Turk Neurosurg. 2011;21(3):384-7.
- [8]. Chaudhari ML, Maheria PB, Bachuwar SP. Double foramen transversarium in cervical vertebra. morphology and clinical importance. Indian J Basic Appl Med Res. 2013;8(2):1084-8.

- [9]. Das S, Suri R, Kapur V. Double foramen transversaria: an osteological study with clinical implications. *Int Med J.* 2005;12:311-3.
- [10]. Taitz C, Nathan H, Arensburg B. Anatomical observations of the foramina transversaria. *J Neurol Neurosurg Psychiatry* 1978;41:170-176.
- [11]. Sharma A, Singh K, Gupta V et al. Double foramen transversarium in cervical vertebra an osteological study. *J Anat Soc India.* 2010;59(2):229-31.
- [12]. Kaya S, Yilmaz ND, Pusat S et al. Double foramen transversarium variation in ancient byzantine cervical vertebrae: preliminary report of an anthropological study. *Turk Neurosurg.* 2011;21:534-8.
- [13]. Rathnakar P, Remya K, Swathi B. Study of accessory foramen transversaria in cervical vertebrae. *Nitte Univ J Health Sci (NUJHS).* 2013;3(4):97-9.
- [14]. Shital T. Shah, Kiran Arora, Kanan P. Shah. Study of Accessory Foramen Transversarium in Cervical Vertebrae. *GCSMC J Med Sci.* 2014;3(2).
- [15]. Patra A, Kaur H, Chhabra U et al. Double foramen transversarium in dried cervical vertebra: An osteological study with its clinical implications. *Indian J Oral Sci.* 2015;6:7-9.
- [16]. Akhtar MJ, Madhukar PK, Rahman S et al. A morphometric study of foramen transversarium of dried cervical vertebrae. *Int J Res Med Sci.* 2015;3:912-6.
- [17]. Patil NP, Dhapate SS, Porwal S et al. The study of incidence of accessory foramen transversaria in the cervical vertebra. *J Dent Med Sci.* 2014;13(7):85-7.
- [18]. Mishra GP, Kumari S, Bhatnagar S, Singh B. Sixth cervical vertebra with bilateral double foramen transversarium and non-bifid spine: a rare case. *Int J Res Med Sci.* 2015;3(1):352-3.
- [19]. Rekha B.S., Dhanlaxmi D. Naginhal; Variations in foramen transversarium of atlas vertebra: An osteological study in South Indians; *International Journal of Research in Health Sciences.* 2014;2(1).224-228.
- [20]. Satti S.R., C.A. Cerniglia, R.A. Koenigsberg; Cervical vertebral artery variations: an anatomic study; *Am J Neuroradiol* 2007;28:976-80.
- [21]. El Shaarawy EAA, Sabry SM, El Gammaroy T, Nasr LE. Morphology and morphometry of the foramina transversaria of cervical vertebrae: A correlation with the position of the vertebral artery. *Aini Medical Journal.* 2010.
- [22]. Epstein B.S. *The spine A radiological of text and atlas third edition.* 1969;24-25.
- [23]. Sinnatamby Chummy S.; *Last's anatomy regional and applied.* 2006;11:447-448.

How to cite this article:

Sudarshan Gupta, Zarna Patel, Rupal S. Gautam. MORPHOLOGICAL STUDY OF ACCESSORY FORAMEN TRANSVERSARIUM IN DRIED CERVICAL VERTEBRAE IN HUMAN BEING. *Int J Anat Res* 2017;5(2.2):3791-3795. DOI: 10.16965/ijar.2017.180