

ANTHROPOMETRIC MEASUREMENTS OF HUMAN EAR LOBULE IN ADULT STUDENT POPULATION

Sangeetha. S ^{*1}, Anisha. B ².

^{*1}Assistant Professor, Department of Anatomy, TOMCH & RC, Bangalore, Karnataka, India.

² Assistant Professor. Department of Anatomy, Sapthagiri Medical College Hospital and Research Center, Bangalore. Karnataka, India.

ABSTRACT

Background: The ear is an important component of the facial complex. Its size, shape and spatial location on the face are important from an aesthetic point of view. The ear lobule morphometry gives information on age and sex and plays a valuable role in forensic investigation. Ear lobule parameters are studied for the surgical treatment of congenital or acquired deformities, reconstruction and in otomorphology for identification.

Aim: To study the morphometric measurements of ear lobules among student population.

Materials and Methods: Measurements were taken from 392 healthy medical students aged 17 – 20 years, from JSS Medical college Mysore, using a standard vernier callipers. The parameters measured were ,lobule height and lobule width of both ears.

Results: In our study we found that lobule width is more in males than females on both sides whereas no such difference was seen in lobule height . Males have a wider lobule than females and the right lobule is wider than the left in both and this difference is statistically significant

Discussion: Knowledge of normal ear dimensions is important in the diagnosis of congenital malformations and acquired deformities, and in planning of treatment. The data presented in this study would help the clinician to produce an anatomically correct ear during its reconstruction.

KEY WORDS: Morphometry, Ear lobule, Vernier calipers.

Address for Correspondence: Dr Sangeetha S, No 21, Flat No 104, Comfort Residency 2, 16th A Main Road, Jayanagar 3rd Block East, Bangalore – 11, Karnataka, India. Mobile-9632470171

E-Mail: sangeethavenkat33@gmail.com

Access this Article online

Quick Response code



DOI: 10.16965/ijar.2017.175

Web site: International Journal of Anatomy and Research
ISSN 2321-4287
www.ijmhr.org/ijar.htm

Received: 07 Mar 2017

Peer Review: 08 Mar 2017

Revised: None

Accepted: 15 Apr 2017

Published (O): 31 May 2017

Published (P): 31 May 2017

INTRODUCTION

Human ear is the defining feature of the face which gives an impression of its bearer's age, sex and ethnicity. Its size ,shape and spatial location on the face are important from an esthetic point of view [1].

Earlobe occupies an unique position among the structures of the face and is a very important region in esthetic composition of the ear [2].

Earlobe is the soft fleshy lower part found at the base of external ear. It is the only part of the auricle not supported by cartilage. It is composed of tough areola and adipose connective tissues lacking the firmness and elasticity of the rest of the pinna [3].

Earlobe is considered to be an important attribute of beauty in many societies due to the secular tradition of use of ornaments and jewel-

lery on this site. The practice of piercing the earlobule dates from ancient times and depending on the culture may have occurred even as a social obligation. The lobes were adorned with large and heavy earrings, causing an increase in the size of the hole and stretching of the lobe [4]. An acquired deformity that develops with aging may include elongation or ptosis of the ear lobe. This condition has been attributed to the loss of elastic fibres and gravitational forces [5].

The height of the lobe covers approximately 25% of the length of the ear and varies between 1.5 – 2 cm. Age alters the shape, width and length of the lobe due to sagging tissue and this is at odds ratio with other esthetic elements of the ear, requiring correction [6].

Knowledge of normal earlobe dimensions may be useful as a guideline for plastic surgeon rectifying defects such as congenital malformations, syndromes and acquired defects. The dimensions vary in different ethnic groups, which necessitate them to base their observations on the data specific to the ethnic group. Initiating a step in this direction, the current study attempts to furnish data for the student population from the Indian subcontinent.

The study is intended to describe the anatomical height and width of the earlobule among medical students aged 17 – 20 years. With the appropriate normative data it is hoped that better and objective reference materials would be provided to the esthetic plastic surgeon engaged in ear rejuvenation in the country. Cosmetic surgery and facial rejuvenation have become quite popular not only in the West, but also in many developing countries including India. For rectifying such abnormalities, a plastic surgeon requires information about normal dimensions of the ear lobe, but these auricular data vary in different ethnic groups. So the morphometric measurements given in the Western literature are less likely to be of much use in the Indian population. Thus knowledge concerning the anatomy of the normal ear in the Indian population is important to the plastic surgeon working here for planning treatment of ear deformities.

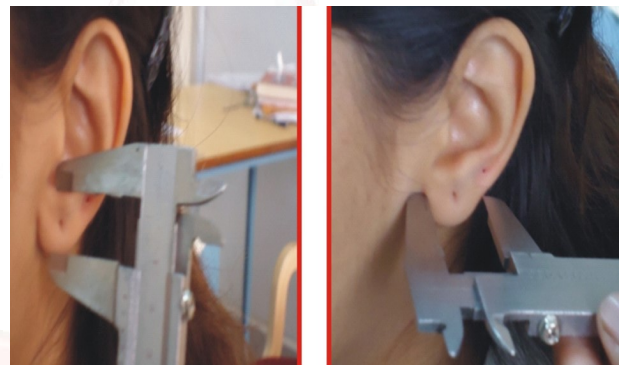
MATERIALS AND METHODS

The study was carried out on 384 students of

age group 17 – 20 years of JSS medical college, Mysore with no evidence of congenital ear anomalies or previous ear surgeries. The purpose of the study was explained to them and informed consent was taken. Clearance of institutional ethical committee was obtained before starting the work.

Standardized measurements of the ear lobule were taken according to landmark points defined by De Carlo et al [7-10]. The parameters measured were Total Lobule Height (LH) and Total Lobule Width (LW). The LH was taken as the distance from the inferior end of the lobule to the base of tragal notch. The LW was taken as the transverse or horizontal width of the lobule at the midpoint of lobular height as shown in Fig 1.

Fig. 1: Measurement of the ear lobule using vernier callipers.



All the measurements were taken by a single investigator using standard vernier callipers capable of measuring to the nearest 0.1 mm. For each volunteer the measurements were carried out twice to ascertain accuracy.

The numerical data were analyzed using EPI- INFO package version 3. 5. 3

RESULTS

The measurements and comparison of results for the right and left ears are shown In Table 1. All parameter values are more in right ears than left ears and statistically significant. The lobular height and lobular width is more in right than left ear and is statistically significant.

Table 1: Right and left ear measurements and comparison of results. . Numbers represent the distances in centimetres.

Parameter	Right	Left	p value
L H (cm)	1.7	1.67	0.05
L W	1.6	1.55	0.01

According to Table 2 all parameter values are more in males than females. The mean LW is more in males than females and is statistically significant. No significant difference was found in the mean LH of males and females.

Table 2: The mean values of R and L ears in relation to gender. . Numbers represent the distances in centimetre.

Side	Parameter	males	Females	p value
right	L H	1.69	1.71	0.39
	L W	1.69	1.55	0
Left	L H	1.69	1.68	0.2
	L W	1.59	1.52	0.01

In Table 3 we observed the mean LH in males and females is 1.69 cm respectively which contradict other studies. The mean LW in males is more than females which concur with other studies.

Table 3: The mean LH and LW in various studies. Numbers represent the distances in centimetres.

Study	Population	LH				LW			
		Males		Females		Males		Females	
		Right	Left	Right	Left	Right	Left	Right	Left
Deopa D et al. 2013 [1]	Indian subcontinent	1.67	1.69	1.66	1.68	1.96	1.96	1.92	1.95
MG Bozkir et al. 2006 [2]	Turkish Caucasians	1.84	1.83	1.79	1.75	1.98	1.94	1.89	1.85
Present study	Indian subcontinent	1.69	1.69	1.71	1.68	1.69	1.59	1.55	1.52

DISCUSSION

The earlobe occupies a unique position among the structures of the face and is an important region in aesthetic composition of the ear which transmits information about age and gender of an individual [11,12]. Any auricular defect in the form of disproportionate size, abnormal elongation of the auricular lobe, or a missing part is corrected by surgery [13]. For rectifying such abnormalities, a plastic surgeon requires information about normal auricular dimensions, the auricle’s bilateral position on the face, and general conformation.

Sexual dimorphism is seen in the auricular linear dimensions with higher values in males. Brucker et al [5] observed an average LH to be 1.88cm and according to a study done by Bozkir et al [2] LH was 1.8 cm in young men and 1.7 cm in young women. Mc Kinney et al [15] obtained data from 100 volunteers and found a mean LH of 1.8 cm. In a study done by Deopa [1] the LH was 1.69cm in males and 1.68 cm in females. In our study the mean LH in males is 1.69cm and in females 1.69cm. No difference in LH was seen

between males and females.

Deopa et al reported mean Right LH of 1.67cm and Left LH of 1.68 cm. the measurement found in the study of Bozkir et al was 1.82 cm in Right ear and 1.79 in Left ear. The Right LH in our study is 1.70cm and Left LH is 1.67cm. In our study the mean LH is more in R ear than L ear and is statistically significant. Brucker et al reported the LW to be 1.95cm in males and 1.97cm in females. The results of Bozkir et al showed 1.94cm in males and 1.85 cm in females whereas in a study by Deopa et al the measurements were 1.96 cm and 1.93 cm. In our study the mean LW in males is 1.64cm and in females 1.53 cm. Males have a statistically significant wider lobule than females.

Our study showed the right LW as 1.62 cm and left LW as 1.56cm which supported the study done by Ferrario [16]. Hence in our study, a statistically significant difference is found in the mean width of right and left ear lobes and it is higher in right ear.

The present study shows existence of sexual dimorphism in the ear lobe dimensions on both sides, significant differences were observed in right and left sides respectively.

CONCLUSION

The data presented in this study have yielded parameters for ear morphology that would prove useful in correcting ear anomalies. There is still need for future studies comparing populations with different social and ethnic background to interpret common knowledge about the size of the ear. With the Knowledge about the normal ear dimensions is important in the diagnosis of congenital malformations and acquired deformities, as well as in the planning of treatment. This study provides the mean values of different morphometric measurements of left and right ear lobes in the student population of India.

Conflicts of Interests: None

REFERENCES

[1]. Deopa D, H K Thakkar, Chandra Prakash, R Niranjana, M P Barua. Anthropometric measurements of external ear of medical students in Uttarakhand region. Journal of anatomical society of India 2013;62:79-83.

- [2]. M G Bozkir, P Karakas and M Yavuz et al. Morphometry of the external ear in our adult population. *Aesthetic Plast Surg* 2006;30:81-85.
- [3]. C S Forza, G Grandi and M Binelli et al. Age and sex related changes in the normal human ear, *Forensic Sci Int.* 2009;187:110-117.
- [4]. Standring S, Barley N R, Collins P, et al. external ear. *Gray's Anatomy.* 40th edn, London: Churchill Livingstone, 2008:618.
- [5]. Azaria R et al. Morphometry of adult human ear lobe: a study of 547 subjects and clinical application. *Plast Reconstr Surg.* 2003;111:2398-402.
- [6]. M J Brucker, J Patel and P K Sullivan. A morphometric study of the external ear: age and sex related differences, *Plastic Reconstr Surg.* 2003;112:647-52.
- [7]. Constant E. Reduction of hypertrophic ear lobe. *Plast Reconstr Surg.* 1979;64:264.
- [8]. Mowlavi A, Meldrum G, Wilhelmi BJ, Zook EG. The esthetic ear lobe: classification of ear lobule ptosis on the basis of a survey of North American caucasians. *Plast Reconst Surg.* 2003;112:226-272.
- [9]. Mowlavi A, Meldrum G, Wilhelmi BJ, Zook EG. Incidence of earlobe ptosis and pseudoptosis in patients seeking facial rejuvenation surgery and effects of aging. *Plast Reconst Surg.* 2004;113:712-717.
- [10]. Colombo LR Q da. Ear lobe rejuvenation: technical description and indications. *Brazilian Journal of Plastic Surgery* 2013;28(2):289-93.
- [11]. De Carlo D, Metaxas D, Stone M. An Anthropometric face model using variational techniques. *Proceedings of the 25th annual conference of computer graphics and interactive techniques* New York: ACM, 19-24 July 1998:67-74.
- [12]. A U Ekanem, S H Garba, T S Musa, N D Dare. Anthropometric study of the pinna among adult nigerians resident in Maiduguri metropolis. *J. Med. Sci,* 2010;10(6):176-180.
- [13]. Alexander.KS, Stott. DJ. A morphometric study of human ear. *Journal of plastic, Reconstructive & Aesthetic surgery* 64(1) 2011:41-47.
- [14]. Ruma P, Singh P. Anthropometry of the normal human auricle: A study of adult Indian men. *Journal of aesth plast surg* 2007;31:372-379.
- [15]. McKinney P, Giese S, Placik O. Management of the ear in rhytidectomy. *Plast Reconstr Surg* 1993;92:858-66.
- [16]. Ferrario VF, Sforza C, Ciusa V, et al. Morphometry of the normal human ear: a cross sectional study from adolescence to mid- adulthood, *J Craniofac Dev Biol* 1999;19:226-33.

How to cite this article:

Sangeetha. S, Anisha. B. ANTHROPOMETRIC MEASUREMENTS OF HUMAN EAR LOBULE IN ADULT STUDENT POPULATION. *Int J Anat Res* 2017;5(2.2):3784-3787. DOI: 10.16965/ijar.2017.175