

A MORPHOMETRIC STUDY OF SUPRASCAPULAR NOTCH AND ITS SAFE ZONE

Shalom Elsy Philip ^{*1}, Dakshayani K.R ².

^{*1} Postgraduate, Department of Anatomy, Mysore medical college, Mysore, Karnataka, India.

Professor and Head², Department of Anatomy, Mysore medical college, Mysore, Karnataka, India.

ABSTRACT

Background: Suprascapular notch (SSN), situated on the superior border of scapula, is bridged by transverse scapular ligament converting into foramen which transmits suprascapular nerve. The SSN is the main site of suprascapular nerve compression, resulting in suprascapular nerve entrapment syndrome, also landmark of the suprascapular nerve during arthroscopic shoulder surgeries.

Aim: To study morphometry and morphological variations of the suprascapular notch and to determine safe zone in the South Indian population.

Materials and Methods: 100 dry scapulae of unknown sex and age were studied in the department of anatomy, Mysore medical college. Variations in suprascapular notch was noted and dimensions were measured with the digital Vernier calipers.

Results: Suprascapular notch was present in all the scapula. U shaped notch was common. Based on Rengachary classification, most prevalent was Type III(36%) and least common was Type VI(3%). 3% and 21% of scapula fell short of safe zone distances from suprascapular notch to supraglenoid tubercle, distance between posterior rim of glenoid cavity and spinoglenoid notch respectively. It was commonly noted in Type II followed by Type IV.

Conclusion: Knowledge of morphology of suprascapular notch is useful in determining the notch type, which leads to suprascapular nerve entrapment. Safe zone distance is of surgical importance in avoiding iatrogenic suprascapular nerve injuries especially in Type II and type IV during shoulder procedures.

KEY WORDS: Suprascapular Notch, Suprascapular Nerve Entrapment, Safe Zone.

Address for Correspondence: Dr. Shalom Elsy Philip, Postgraduate, Department of Anatomy, Mysore Medical College and Research Institute, Irwin road, Yadavagiri, Mysuru, Karnataka- 570001, India. **E-Mail:** tfshalom@gmail.com

Access this Article online

Quick Response code



DOI: 10.16965/ijar.2017.172

Web site: International Journal of Anatomy and Research
ISSN 2321-4287
www.ijmhr.org/ijar.htm

Received: 06 Mar 2017

Peer Review: 07 Mar 2017

Revised: None

Accepted: 03 Apr 2017

Published (O): 30 Apr 2017

Published (P): 30 Apr 2017

INTRODUCTION

The suprascapular notch (SSN) is situated in the lateral part of the superior border of the scapula just adjacent to the base of the coracoid process. It serves as a passage for the suprascapular vessels and is converted into foramen by the superior transverse scapular ligament [1]. The suprascapular nerve and vein traverse the upper border of the scapula under the superior

transverse scapular ligament (STSL) [2]. The notch may be converted to bony foramen by the ossification of this ligament. The ossified superior transverse scapular ligament can be a risky factor at surgical explorations during a suprascapular nerve decompression [3]. The suprascapular notch serves as an important landmark during arthroscopic procedures [4]. The shape and size of the SSN is the most important

factor in the etiopathogenesis of suprascapular nerve entrapment syndrome [5]. The present study was done as very literature was available on south indian population and this study will help to have better understanding of pathogenesis of suprascapular nerve entrapment and safe zone distance for shoulder arthroscopic surgeries.

MATERIALS AND METHODS

The present study was carried out in 100 dry scapulae of unknown sex and age in the Department of Anatomy, Mysore medical college, India and they were grossly examined irrespective of age, sex, left or right sidedness. Morphological variations in shape of suprascapular notch was noted and were classified based on the description of Rengachary et.al[6]. The following dimensions were measured with the digital Vernier calipers. FIG -1

Fig. 1: Showing the procedure to Measure the Superior transverse diameter, Middle transverse diameter, Maximum depth.

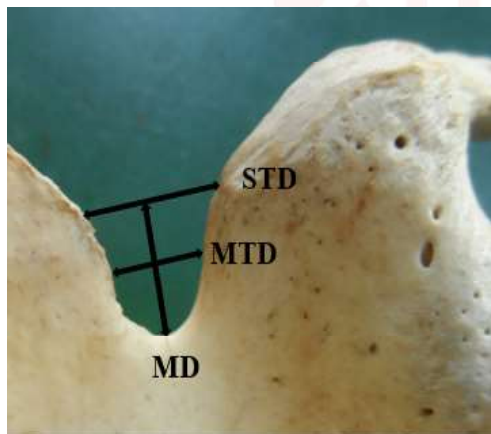
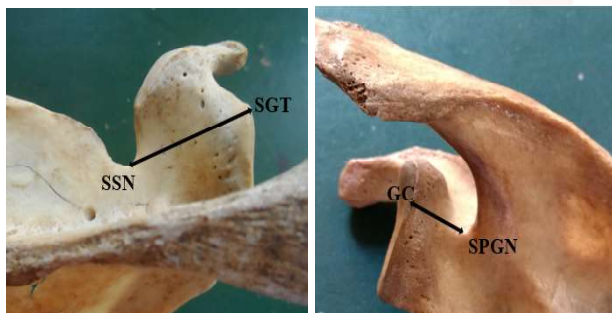


Fig. 2A & 2B: Measurement of SSN and SGT, GC and SPGN.



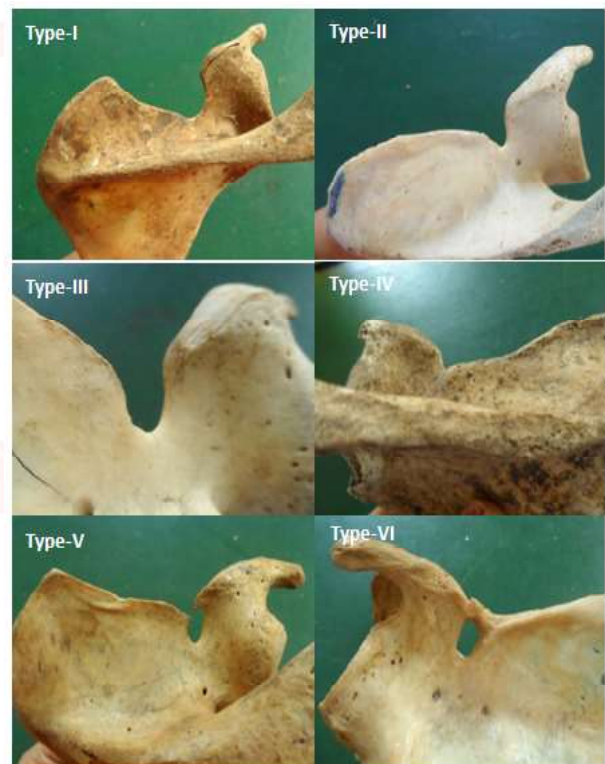
Maximum depth (MD): The distance between the superior corners of the notch to the deepest point of the suprascapular notch.

Superior transverse diameter (STD): It is the horizontal distance between superior corners of the SSN on the superior border of the scapula.

Middle transverse diameter (MTD): It is the horizontal distance between the opposite walls of the SSN at a mid- point of the MD and perpendicular to it.

To assess the safe zone, the distance between the deepest point of the suprascapular notch and the supra glenoid tubercle, also the distance between the medial wall of the spinoglenoid notch at the base of scapular spine and the posterior rim of the glenoid cavity were measured (FIG-2A & 2B). Defective and broken scapulae were excluded from the study. The scapulae with indentation and partial ossification of ligament were excluded from the measurement. The data was analyzed statistically.

Fig. 3: Showing the Classification of Scapular notches.



RESULTS AND DISCUSSION

In this study, all the scapulae presented with suprascapular notch. The incidence of various types of suprascapular notch was classified into six types based on Rengachary classification (Table 1) Type I- 9%, Type II-36%, Type III-38%, Type IV-8%, Type V- 6% Type VI-3%. U shaped notches were commonly observed followed by V-shaped notch. Complete ossification of the ligament was observed in 3%.

The mean distance between the SSN and the supraglenoid tubercle was 28.10 ± 3.4 mm. The

distance varied with the types of notch, with type 1 and type II notches displaying the greatest mean distance and type IV and type VI the least.

Table 1: Incidence of various shapes of notch.

Sl. no	shape	Total (%)
1	Type I	9%
2	Type II	36%
3	Type III	38%
4	Type IV	8%
5	Type V	6%
6	Type VI	3%

The distance between the posterior rim of the glenoid cavity and the medial wall of the spinoglenoid notch(SGN) at the base of the scapula spine was observed to be 16.37 ± 2.7 mm. with type I, Type II, Type III giving the maximum distance and type IV the least. (Table 2)

Table 2: Distance between suprascapular notch and supraglenoid tubercle and distance between medial wall of spinoglenoid notch and posterior margin of glenoid cavity respectively.

SL.No	Type of notch	Mean \pm SD(mm)	Mean \pm SD(mm)
1	Type I	30.2 \pm 6.0	17.0 \pm 4.1
2	Type II	30.2 \pm 2.9	16.8 \pm 2.9
3	Type III	28.3 \pm 2.9	16.3 \pm 2.0
4	Type IV	27.6 \pm 4.1	14.5 \pm 1.9
5	Type V	28.8 \pm 2.0	15.9 \pm 1.9
6	Type VI	25.6 \pm 0.8	15.5 \pm 1.5

The dimensions of various types of suprascapular notches showed that in 13% of the scapulae, STD was less than MD and in 75% STD was greater than MD. None of the scapulae showed dimensions of STD equal to MD. (Table 3)

Table 3: Dimensions of various types of notch

SL.No	Type of notch	STD	MTD	MD
		Mean \pm SD(mm)	Mean \pm SD(mm)	Mean \pm SD(mm)
1	Type I	-	-	-
2	Type II	13.03 \pm 2.6	9.32 \pm 2.3	6.66 \pm 2.3
3	Type III	10.12 \pm 2.4	7.76 \pm 2.2	8.42 \pm 1.4
4	Type IV	7.67 \pm 2.5	4.63 \pm 2.0	5.0 \pm 2.0
5	Type V	8.64 \pm 4.5	7.29 \pm 2.5	8.89 \pm 2.0
6	Type VI	-	-	-

The first description of suprascapular nerve entrapment syndrome at the site of the suprascapular notch was made by Kopell and Thompson [7]. Many etiological factors have been related to this syndrome involving iatrogenic lesions during open or arthroscopic surgical procedures [6], anterior shoulder dislocation [8],

injury from direct trauma [8], ganglion cysts [9], synovial and Ewing’s sarcomas [9], and chondrosarcoma and lipoma [10].

Therefore various studies have been done on suprascapular notch variations in different populations. Rengachary et al., [6] Ticker et al., [11], Bayramoglu et al., [12] Natsis et al., [13] Sinkeet [14] Wang [15] and Polguy [16]. Depending on the shape of suprascapular notch and the degree of ossification, Rengachary et al., [6] classified SSN into six types. FIG-3 shows Type I- Wide depression in the superior border of the scapula Type II- Wide blunted V shape, Type III- Symmetric U shape Type IV- Very small V shape, often with a shallow groove for the suprascapular nerve Type V- Partial ossified medial portion of the suprascapular ligament Type VI- Completely ossified suprascapular ligament forming foramen. In the present study, Type III was more common which was similar to the observation of other studies, followed by type II which was similar to the findings of Rengachary et al., [6] and Natsis et al [13]. It differed from the studies of Sinkeet et al [14] and Sangam et al [17] which showed type I as most prevalent (Table 4). This differences in the population could possibly be explained due to ossification of the coracoid process and epiphysis influencing the shape of the SSN. Odita et al [18] reported that this ossification appeared earlier in Nigerian infants than in Caucasians. The least common was type VI which favoured with that of Rengachary et al [6], Sinkeet et al [14] and Sangam et al [17]. The literature showed that incidence of suprascapular foramen was different in different populations.

Table 4: Comparison of types of notch with other studies.

Author	Type of notch					
	Type I	Type II	Type III	Type IV	Type V	Type VI
Rengachary et al 1976 [6]	6%	24%	40%	13%	11%	6%
Natsis et al 2007 [13]	8%	31%	48%	3%	6%	4%
Sinkeet et.al 2010 [14]	22%	21%	29%	5%	18%	4%
Sangam M et al 2013 [17]	21%	8%	59%	2%	5%	1%
Present study	9%	36%	38%	8%	6%	3%

In the present study, the dimensions of various types of suprascapular notches showed that in 13% of the scapulae, STD was less than MD which is comparatively less that of other studies and in 75% of scapulae, STD was greater than

MD where the findings were of a greater value than that of Rengachary et al [6] and Natsis et al [13]. Dunkelgrun et al [19] stated that type III notches had a larger area than Type IV notches, leading to the conclusion that a V-shaped notch would be more likely associated with nerve entrapment. But no direct correlation between notch type and suprascapular nerve entrapment has been shown clinically [20].

De Mulder et.al [21] and Warner et.al [21] described that the distance between the SSN and the margin of the glenoid cavity is critical during open surgical procedures requiring dissection of the posterior shoulder joint. A safe zone has been described to avoid injuries during surgical procedures, based on the critical distance within which they can be done safely [4]. It has been reported that 2.3 cm from the glenoid rim at the level of the superior rim of the glenoid and 1.4 cm from the posterior rim of the glenoid at the level of the base of the scapular spine are safe[21]. In this study the mean distances were 2.9 and 1.6 cm respectively and in few scapulae corresponding distances were less than the mentioned safe zones. Nevertheless 3% and 21% of scapula fell short of respective safe zone distances which implies that in significant number of cases, the mentioned safe zone is inadequate to avoid injuries while performing shoulder procedures. It was commonly noted in type II followed by type IV. Thus, it calls for an extra caution in carrying out shoulder procedures in mentioned types of suprascapular notch.

CONCLUSION

The knowledge of anatomical variations of notch is helpful in understanding the etiology of suprascapular nerve entrapment. In a significant number of cases the defined safe zone is inadequate to eliminate the risk of nerve injury during arthroscopic shoulder procedures, even more so with type II and type IV notches.

ABBREVIATIONS

SSN - Suprascapular notch

STSL - Superior transverse scapular ligament

MD - Maximum depth

STD - Superior transverse diameter

MTD - Middle transverse diameter

Conflicts of Interests: None

REFERENCES

- [1]. Williams PL, Bannister LH, Berry MM, Collins P, et al. Gray's anatomy. 38th edition. Churchill Livingstone 2004;615-619.
- [2]. Moore KL, Dalley AF, Agur AM Clinical oriented anatomy 6th edition. Philadelphia: Lippincott Williams & Wilkins (2010) pp 88–92.
- [3]. Khadija Iqbal and Rameez Iqbal S. Classification of Suprascapular Notch According to Anatomical Measurements in Human Scapulae. Journal of the College of Physicians and Surgeons Pakistan 2011;21(3):169-170.
- [4]. Biglani LU, Dalsey RM, McCann PD, April EW. An anatomical study of suprascapular nerve. Arthroscopy 1990;6:301-305.
- [5]. Dunkelgrun M, Iesaka K, Park SS, Kummer FJ, Zuckerman JD. Inter observer reliability and intra observer reproducibility in suprascapular notch typing. Bull Hosp Joint Dis. 2003;61:118-22.
- [6]. Rengachary SS, Neff JP, Singer PA, Brackett CF Suprascapular entrapment neuropathy. A clinical, anatomical and comparative study, Part I. Neurosurgery 1979;4:441-446.
- [7]. Kopell HP, Thompson WA: Pain and the frozen shoulder. Surg Gynecol Obstet 1959;109:92-96.
- [8]. Antoniou J, Tae SK, Williams GR, Bird S, Ramsey ML, Iannotti JP: Suprascapular neuropathy. Variability in the diagnosis, treatment and outcome. Clin Orthop 2001;386:131-138.
- [9]. Piatt BE, Hawkins RJ, Fritz RC, Ho CP, Wolf E, Schickendantz M: Clinical evaluation and treatment of spinoglenoid notch ganglion cysts. J Shoulder Elbow Surg 2002;11:600–604.
- [10]. Hazrati Y, Miller S, Moore S, Hausman M, Flatow E: Suprascapular nerve entrapment secondary to a lipoma. Clin Orthop 2003;411:124-128.
- [11]. Ticker JB, Djurasovic M, Strauch RJ, April EW, Pollock RG, Flatow EL, Biglani LU. The incidence of ganglion cysts and other variations in anatomy along the course of the suprascapular nerve. J Shoulder Elbow Surg 1998;7:472-478.
- [12]. Bayramoglu A, Demiryurek D, Tuccar E, Erbil M, Aldur MM, Tetik O, Doral MN. Variations in anatomy at the suprascapular notch possibly causing suprascapular nerve entrapment: an anatomical study. Knee Surg Sport Trum Arthros. 2003;11:393-398.
- [13]. Natsis K, Totlis T, Tsikaras P, Appell HJ, Skandalakis P, Koebke [5] J. Proposal for classification of the suprascapular notch: a study on 423 dried scapulas. Clin Anat. 2007;20:135-39.
- [14]. Sinkeet SR, Awori KO, Odula PO, Ogeng JA, Mwachaka PM. The suprascapular notch: its morphology and distance from the glenoid cavity in a Kenyan population. Folia Morphol. 2010;69(4):241-45.
- [15]. Wang HJ, Chen C, Wu LP, Pan CQ, Zhang WJ, Li YK. Variable morphology of suprascapular notch: an investigation and quantitative measurements in Chinese population. Clin Anat. 2011;24:47-55.

- [16]. Polgaj M, Jedrzejewski KS, Podgorski M, Topol M. Correlation between morphometry of the suprascapular notch and anthropometric measurements of the scapula. *Folia Morphol.* 2011;70(2):109-15.
- [17]. Sangam M, Sri Sarada devi S, Krupadanam K, Anasuya K. A Study on the Morphology of the Suprascapular Notch and Its Distance from the Glenoid Cavity. *Journal of Clinical and Diagnostic Research.* 2013;7(2):189-192.
- [18]. Odita JC, Ugbodaga CI, Omene JA, Okolo AA Humeral head and coracoid ossification in Nigerian newborn infants. *Pediatric Radiol.* 1983;13:276-278.
- [19]. Dunkelgrun M, Iesaka K, Park SS, Kummer FJ, Zuckerman JD: Interobserver reliability and intraobserver reproducibility in suprascapular notch typing. *Bull Hosp Joint Dis* 2003;61:118-122.
- [20]. Alon M, Weiss S, Fischel B, and Dekel S. Bilateral suprascapular nerve entrapment syndrome due to anomalous transverse scapula ligament. *Clinical Orthopaedics*, 1998;234:31-3.
- [21]. De Mulder K, Marynissen H, Van Laere C Arthroscopic transglenoid suture of Bankart lesions. *Acta Orthop Belg.* 1998;64:160-166.
- [22]. Warner JJP, Krushell RJ, Masquelet A, Gerber C Anatomy and relationships of the suprascapular nerve: anatomical constraints to mobilization of the supraspinatus and infraspinatus muscles in the management of massive rotatorcuff tears. *J Bone Joint Surg Am.* 1992;74:36-45.
- [23]. Shishido H, Kikuchi S Injury to the suprascapular nerve during shoulder joint surgery: an anatomical study. *J Shoulder Elbow Surg.* 2001;10:372-376.

How to cite this article:

Shalom Elsy Philip, Dakshayani K.R. A MORPHOMETRIC STUDY OF SUPRASCAPULAR NOTCH AND ITS SAFE ZONE. *Int J Anat Res* 2017;5(2.1):3766-3770. DOI: 10.16965/ijar.2017.172