

ANATOMICAL VARIATIONS OF ACCESSORY MAXILLARY SINUS OSTIUM: AN ENDOSCOPIC STUDY

Anukaran Mahajan ¹, Anupama Mahajan ^{*2}, Karunesh Gupta ³, Pankaj Verma ⁴,
Monika Lalit ⁵.

¹ Junior Resident, Department of ENT, VMMC & Safderjung Hospital, New Delhi, India.

^{*2} Professor, Department of Anatomy, SGRDIMS&R, Amritsar, Punjab, India.

³ ENT Consultant, Chikitsa Hospital, Amritsar, Punjab, India.

⁴ ENT Consultant, Chikitsa Hospital, Amritsar, Punjab, India.

⁵ Assistant Prof, Dept. of Anatomy, SGRDIMS&R, Amritsar, Punjab, India.

ABSTRACT

Introduction: There has been a significant shift from external and headlight sinus surgery to functional endoscopic sinus surgery (FESS) in the past quarter century. Therefore understanding of anatomical variations of Accessory Maxillary Ostium (AMO) becomes essential for an endoscopic sinus surgeon to differentiate it from the natural ostium for safe and efficacious surgery in this region.

AIM: To note the presence and anatomical variations of AMO that predisposes to recurrent sinusitis and headache.

Materials and Methods: Material for the present study consisted of 100 adult patients (58 males & 42 females) in the age group of 22 to 72 years old, selected from OPD of Chikitsa ENT hospital, Amritsar. Systematic nasal endoscopy was done and the shape, size, location, number and laterality of AMO was noted.

Results: Among 100 subjects (200 half sides) AMO was found in 42 (21%) halves, 33 (78.57%) were found in anterior nasal fontanelle (ANF), 7 (16.66%) in posterior nasal fontanelle (PNF) and 2 (4.76%) in hiatus semilunaris (HS). These ostia were circular in 34 (80.95%) halves and oval in 8 (19.04%) halves. Regarding position, those situated in ANF and HS were placed in horizontally while those lying in PNF were vertically. Out of 42 (21%) halves, unilateral AMO was present in 36 (85.71%) halves, bilateral in 6 (14.28%) halves and double in 14 (33.33%) whereas single in 28 (66.66%) halves.

Conclusions: Each sinus cavity has a specific drainage point/ostium through which normal mucociliary clearance is channeled. The endoscopic sinus surgeons must have a detailed knowledge of anatomical variations of AMO in any interventional maxillary sinus surgery to gain maximum result (restoring normal function) with minimal trauma and morbidity.

KEY WORDS: Paranasal sinuses, Accessory Maxillary ostium, Fontanelle, Sinusitis.

Address for Correspondence: Dr Anupama Mahajan, Professor & Head, Department of Anatomy, Sri Guru Ram Das Institute of Medical Sciences & Research, Amritsar (Punjab), India.

Mobile no. 9815733321 **E-Mail:** anupamasrd@yahoo.com

Access this Article online

Quick Response code



DOI: 10.16965/ijar.2016.504

Web site: International Journal of Anatomy and Research
ISSN 2321-4287
www.ijmhr.org/ijar.htm

Received: 09 Dec 2016

Peer Review: 13 Dec 2016

Revised: None

Accepted: 06 Feb 2017

Published (O): 28 Feb 2017

Published (P): 28 Feb 2017

INTRODUCTION

The sinuses are the spaces in the bones of the

face above and to either side of the nose and in the forehead and cheeks [1]. They are like rooms

that connect to one another and open or drain into the nose [2]. Infection or blockage in the sinuses can block the nose producing infected mucus down the back of the nose into the throat [3]. Knowledge of normal Anatomy is mandatory for accurate diagnosis of sinonasal pathology [4]. The most frequent anatomical variants should be identified to decrease the risks of surgery. The anatomical variations of surgical landmarks represent a significant challenge even to the most experienced surgeon [5].

The "osteomeatal complex" term is used for a group of anatomical structures that contribute to the final common drainage pathway of maxillary, anterior ethmoidal and frontal sinuses [6]. Recognition of the maxillary ostia is tedious while performing endoscopic procedures which accounts for a high rate of orbital complications for a novice performing surgery in this region [7]. In the live patient the maxillary sinus opening is small and not easily seen. This is because the large opening is closed by the descending process of lacrimal bone anteriorly, the uncinat process of the ethmoid bone anteroinferiorly, the maxillary process of the inferior turbinate inferiorly and the perpendicular plate of palatine bone posteriorly [8]. AMO is one of the anatomical variations that play a role in the development of Chronic maxillary sinusitis. It is not clear whether these ostia are congenital or acquired [9]. A possible mechanism of formation of accessory ostium is obstruction of the main ostium by maxillary sinusitis or due to anatomic and pathologic factors in the middle meatus resulting in the rupture of membranous areas known as fontanelle [10].

The fontanelle are certain regions in the middle meatus located below the uncinat process and above the inferior turbinate, covered by nasal mucous membrane medially and mucosa of maxillary sinus laterally with connective tissue sandwiched between the two. These according to their location in relation to uncinat process are anterior nasal fontanella (ANF) and Posterior nasal fontanelle (PNF) [11]. Maxillary sinus ostium is on the highest part of medial wall of sinus and it doesn't open directly into nasal cavity but into narrow ethmoidal infundibulum, inflammation of which can further interfere with drainage[12].

Accessory maxillary ostium is located 5-10 mm superior to the attachment of inferior concha and opens to the lateral nasal wall. Two fold increase in the incidence of maxillary sinusitis is observed due to presence of accessory maxillary ostia[13]. While performing endoscopic sinus surgery in middle meatus, it is important to differentiate primary maxillary ostium from accessory maxillary ostium to avoid orbital injuries and to achieve adequate results.

MATERIALS AND METHODS

Material for the present study consisted of 100 adult patients (58 males and 42 females) in the age group of 22 to 72 years old were selected from OPD of Chikitsa ENT hospital, Amritsar who visited the hospital in the period of Jan 2016 to July 2016. Systematic nasal endoscopy was done in the operation theatre after taking written consent from the patient. Before taking the consent, procedure was fully explained to the patients. We noted the shape, size, location, number and laterality (present unilaterally or bilaterally) of accessory maxillary ostium.

Endoscopic Technique: For this study we used Karl Storz rigid endoscopes with deflection angles of 0 and 300. The endoscope was 18 cms long with glass rod lenses (Hopkins system) with an outer diameter of 4 mm. Endoscopic pictures were taken by coupling the endoscope with a Stryker High Definition camera and cold light source. No premedication was required.

Patient was asked to lie in supine position in the operation theatre. The nose was packed with gauge pack soaked with 4% xylocaine with Adrenaline for topical anaesthesia and decongestant effect. After ten minutes nasal packs were removed and telescope was passed gently along the floor of the nasal cavity between the inferior turbinate and septum without touching either structure. The 2nd pass of the scope along the roof of the posterior choana and the anterior surface of the sphenoid was practiced gently without touching any of the turbinates. In the 3rd pass the contents of the middle meatus were examined by gently retracting the middle turbinate medially with the Freer' elevator. In an anterior to posterior direction first examined was the most anterior one third attachment of the middle turbinate to the

cribriform plate. Within the meatus most anteriorly was the curved boomerang shaped uncinete process.

The bulge of bulla was seen behind the uncinete process. Between the two was observed hiatus semilunaris. As the scope was passed further posteriorly the third or horizontal attachment of middle turbinate was seen. It forms the roof of the middle meatus. Accessory ostium when seen were in the region of anterior fontanelle i.e. anteroinferior to the anterior end of the uncinete process and in the posterior fontanelle i.e. above and behind the posterior end of the uncinete process. Accessory ostia were mostly circular and were easily seen unlike the normal ostium which is elliptical or tunnel like and is well hidden by the uncinete process. We noted the shape, size, location, number and laterality (present unilaterally or bilaterally) of accessory maxillary ostia.

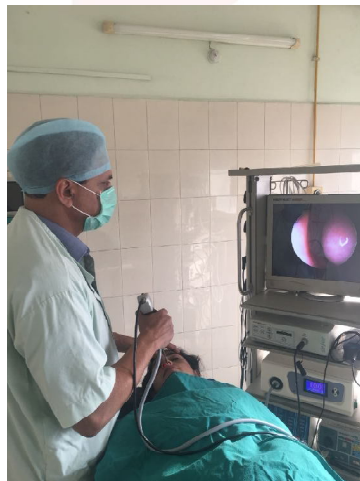

Fig. 1: Showing set up for nasal endoscopic examination.

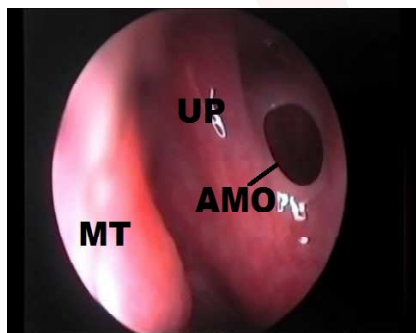


Fig. 2: Showing amo in anterior fontanelle(left side).

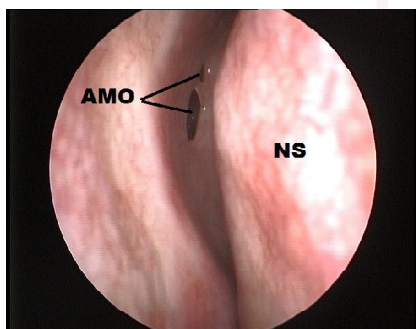
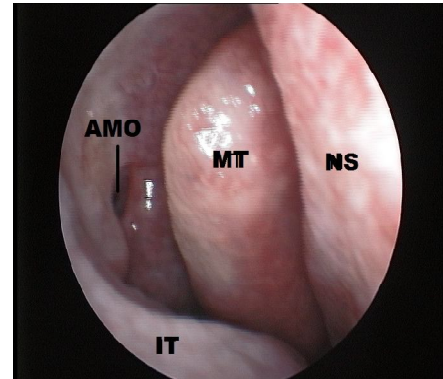


Fig. 3: Showing double accessory ostia.

Fig.4: Showing accessory maxillary ostium in posterior fontanelle (right side).



RESULTS

Table 1: Location, side and number of accessory maxillary ostium in 42 halves.

S. no.	Location N= 42 (21%)	Right side N=29 (69.04%)	Left side N=13 (30.90%)	Singleostium N=28 (66.66%)	Doubleostium N=14 (33.33%)
1	Anterior nasal fontanelle (ANF) N=33 (78.57%)	N=25 (86.20%)	N=11 (84.61%)	N=18 (64.28%)	N=8(Rt.) (57.14%)
2	Posterior nasal fontanelle (PNF) N=7 (16.66%)	N=4 (13.79%)	-----	N=10 (35.71%)	N=4(Rt.) (28.57%)
3	Hiatus semilunaris (HS) N=2 (4.76%)	-----	N=2 (15.38%)	-----	N=2(Lt.) (14.28%)

Table 2: Incidence and location of accessory maxillary ostia.

Sr no	Author' name	Year	Incidence	Location	Study material
1	Yenguin et al [13]	2016	19.10%	ANF or PNF or HS	General population
2	Sindel et al [7]	2014	13.80%	Rear middle or rear front or rear	Cadavers
3	Singhal and Singhal [6]	2013	18.50%	ANF or PNF	Cadavers
4	Lang and sakals [8]	1982	9.50%	PNF	Cadavers
5	Van Alyea [15]	1936	23%	Not specified	Cadavers
6	Neivert [29]	1930	25%	Not specified	Cadavers
7	Schaeffer [14]	1920	43%	ANF or PNF	Cadavers
8	May et al [22]	1990	0%	PNF	Cadavers
9	Kennedy and Zeinrich [30]	1991	15%	Not specified	Endoscopic
10	Lang and Wuzburg [28]	1991	28%	Not specified	Cadavers
11	Myerson [2]	1932	31%	Not specified	Cadavers
12	Stammerger and Kennedy [27]	1995	4.50%	ANF or PNF	General population
13	Zuckerkindl [11]	1893	9.50%	ANF or PNF	Cadavers
14	Kumar et al [21]	2001	30%	ANF or PNF or HS	Cadavers
15	Present study	2016	21%	ANF or PNF or HS	General population

Among 100 subjects (200 half sides) accessory Maxillary sinus ostium (AMO) was found in 42(21%) halves, 33(78.57%) were found in anterior nasal fontanelle(ANF), 7(16.66%) in posterior nasal fontanelle (PNF)and 2 (4.76%) in hiatus semilunaris(HS), varied in size from 0.5mm to 5mm. Regarding shape, in 34(80.95%) halves accessory Maxillary sinus ostia were circular while in 8 (19.04%) halves these were oval in shape. Out of 42(21%) halves, in 29(69.04%) halves accessory Maxillary sinus ostia were present on right side while in 13(30.95%) halves these were present on left

side, unilateral in 36(85.71%) and bilateral in 6 (14.28%), double in 14(33.33%) and single in 28(66.66%) halves. Out of 14(33.33%) halves having double AMO, in 8(57.14%) these were present in ANF on right side, 4(28.57%) in PNF on right side and in 2 (14.28%) in hiatus semilunaris on left side. Out of 28(66.66%) halves, single AMO was present in ANF on both right and left sides in 18(64.28%) and in 10 (35.71%) halves it was present in PNF.

DISCUSSION

The Endoscopic sinus surgeons must have a detailed knowledge of Anatomical variations of Maxillary sinus opening in any interventional maxillary sinus surgeries as it relates to the orbital floor, ethmoid infundibulum and nasolacrimal duct. In the adult the maxillary sinus can be described as triangular in shape, measuring 25 mm along the anterior limb of its base, 34 mm in depth and 33mm in height [14,15]. The sinus can be partially compartmentalized by either complete or incomplete septa. Knowledge of the incidence and morphology of maxillary sinus septa has clinical implications especially in sinus lift operations performed preparatory to the placement of dental implants [16].

Presence of separate cavities in posterior part of the sinus can be a source of persistent infection [17]. The primary or natural ostium of this sinus is located in the superior aspect of medial wall of the sinus and drains via its infundibulum into the ethmoidal infundibulum and thus the hiatus semilunaris [18]. Regarding position the ostium is seen in the region of the posterior half of the infundibulum or posterior to the midpoint of the bulla ethmoidalis [2,14,15]. Lang and Papke found that the ostium is located 1.3 to 11.5 mm average 4mm from the nasolacrimal duct and this proximity of the duct to the natural ostium makes it vulnerable to injury during middle meatus antrostomy [19].

The natural ostium differentiates from accessory ostium in the fact that it tends to be elliptical measuring from 1 to 20mm in length, located more anteriorly than accessory ostium and has an angle to the vertical plane. The accessory ostium is located 5-10 mm superior to the attachment point of inferior concha and it opens to lateral nasal wall or infundibulum [20].

It is round, parallel to vertical plane and may be seen during direct nasal examination. The incidence of presence and location of accessory maxillary sinus ostium varies according to different workers in studies conducted on cadavers and endoscopic examination of live subjects [Table 2]. The incidence ranges from 0% -43%. In the present study accessory maxillary sinus ostium was observed in 42(21%) out of 200 half heads that is in accordance with the study of Van Alyea [15] and Singal [6] who reported the incidence of accessory maxillary ostia in 23% and 22.5% of the specimens respectively. Though most of the authors have not specified the location of the accessory maxillary sinus ostium with reference to the fontanelle, (the membranous region of medial sinus wall) Kumar et al [21] in their dissections on thirty half heads from fifteen adult Indian cadavers reported that accessory maxillary ostium was present in 9(30%) half heads being located in ANF in 6(66.7%), in PNF in 2 (22.2%) and at HS 1(11.1%) in accordance with the present study i.e. out of 42(21%) accessory maxillary sinus ostium was located in ANF in (78.57%), in PNF (16.66%) and at HS (4.76%). However May et al [22] reported that location of accessory maxillary sinus ostium was restricted to the posterior nasal fontanelle, posteroinferior to natural ostium. The present study observed that besides the fontanelle, the accessory maxillary sinus ostium can be sited in HS (4.76%) a finding similar to that of Frank et al [23].

The present study stated that out of 42(21%), double accessory maxillary sinus ostium was present in 14(33.33%) that includes 8(57.14%) in ANF on right side, 4(28.57%) in PNF on right side, 2(14.28%) in HS on left side and a single accessory ostium in 28(66.66%) that includes 18(64.28%) in ANF on both right and left side, 10(35.71%) in PNF in line with the study of Kumar et al [21]. However Schaeffer [14] recorded double Primary maxillary ostium and does not favour calling one of these accessory to the main. But Rice and Schaeffer [24] termed all extra openings other than a single primary maxillary ostium as accessory maxillary ostium irrespective of their location. Prasanna [25] in his study on forty cadavers head & neck specimens cut sagittally through the nose reported accessory

maxillary ostium in membranous fontanelle of lateral wall in 9 (22.5%) of specimens which opened into the membranous meatus inferior to uncinat process in 3/4 th cases. Sindel et al[7] examined 29 formaldehyde fixed adultcadavers with endoscope and observed natural maxillary ostium in posterior 1/3 of HS in 51.7%, septal deviations in 34.4%, accessory maxillary ostia in 8(13.8%). These findings were in line with current literature.

Presence of accessory maxillary ostia disturbs the mucociliary clearance of maxillary sinus .On endoscopy the mucociliary flow of secretions is frequently found moving through the accessory maxillary sinus ostium into the maxillary sinus and then leaving through primary maxillary ostium. This may be the reason for chronic maxillary sinusitis [26].

So detailed knowledge of anatomic variations in paranasal sinus region is essential for ENTsurgeons to increase the success rate of FESS(Functional Endoscopic Sinus Surgery).

CONCLUSION

The accessory maxillary sinus ostium is one of the anatomical variations that plays a very important role in the development of chronic maxillary sinusitis.Presence of accessory maxillary ostium causes mucus to recirculate from sinus to the nasal cavity through the natural ostium and back to the sinus through accessory ostium. Therefore the endoscopic sinus surgeons must have a detailed knowledge of inconsistent situation of accessory maxillary sinus ostium as it is extremely beneficial for surgical intervention of the functional endoscopic sinus surgery (FESS) by joining the separate openings into one larger antrostomy to restore normal sinus ventilation and mucociliary function.

Conflicts of Interests: None

REFERENCES

- [1]. Rosenbeger HC. Clinical availability of ostium maxillary: clinical and cadaveric study. *Ann Otol Rhinol Laryngol* 1938; 47:176-82.
- [2]. Myerson MC. The natural orifice of the maxillary sinus-anatomic study. *Arch Otolaryngol Head Neck Surg* 1932;15:80-91.
- [3]. McDonnell D, Esposito M, Todd ME. A teaching model to illustrate the variation in size and shape of the maxillary sinus. *J Anat* 1992;181:377-80.
- [4]. Champsaur P, Pascal T, Vidal V et al. Radioanatomy of the paranasal sinuses. *J Radiol* 2003;84:885-900.
- [5]. Anon JB, Klimek L, Mosges R, Zinreich SJ. Computer-assisted endoscopic sinus surgery: an international review. *Otol Clin North Am* 1997;30:389-401.
- [6]. Singhal M and Singhal D. Maxillary sinus ostium - Morphology and its clinical relevance. *Cibtech J of Surg* 2013;2(3):26-29.
- [7]. Sindel A, Turhan M, Ogut E, Akdag M, Bostanci A, Sindel M. An endoscopic cadaveric study: Accessory maxillary ostia. *Dicle Med J* 2014;41(2):262-67.
- [8]. Lang J, Sakals E. Über die Höhe der Cavitasnasi, die Längeihres Bodens und Maßesowie Anordnung der Conchae nasales. *Anat Anz* 1981;149:297-318.
- [9]. Genc S, O.M., Titiz A, Unal A. Development of maxillary accessory ostium following sinusitis in rabbits. *Rhinology* 2008;46:121-24.
- [10]. Levine HL, Mark M, Rontal M, Rontal E. Complex anatomy of lateral nasal wall simplified for endoscopic sinus surgery. New York: Thieme Medical Publishers ;1993.pp1-28.
- [11]. Zuckerkandl E. Die Siebbeinmuscheln des Menschen. *Anat Anz* 1892;7:13-25.
- [12]. Matthews BL, Burke AJ. Recirculation of mucus via accessory ostia causing chronic maxillary sinus disease. *Otolaryngol Head Neck Surg* 1997;117:422-23.
- [13]. Yenigun A, Fazliogullari Z, Gun C, Uysal II, Nayman A, Karabulut AK. The effect of the presence of the accessory maxillary ostium on the maxillary sinus. *Eur Arch Otorhinolaryngol* 2016;273:4315.
- [14]. Schaeffer JP. The Nose, Paranasal Sinuses, Nasolacrimal passageways and olfactory organ in man. Philadelphia: P. Blakiston's Son; 1920.
- [15]. Van Alyea OE. The Ostium Maxillare anatomic study of its surgical accessibility. *Arch Otolaryngol* 1936; 24:553-69.
- [16]. Krennmair G, Ulm C, Lugmayr H. Maxillary sinus septa: incidence, morphology and clinical implications. *J Craniomaxillofac Surg*. 1997 ;25(5):261-5.
- [17]. Som PM. CT of the Paranasal Sinuses. *Neuroradiology* 1985; 27: 189-201.
- [18]. Porter GT, Quinn FB. Paranasal Sinuses: Anatomy and Function. The University of Texas Medical Branch (UTMB), Department of Otolaryngology, Galveston TX January Grand Rounds presentation. 2002;1:1-3.
- [19]. Lang J, Papke J. Clinical anatomy of the inferior wall of the orbit and its neighboring structures]. *Gegenbaurs Morphol Jahrb*. 1984;130(1):1-47.
- [20]. Salman SD. Complications of endoscopic sinus surgery. *Am J Otolaryngol* 1991;12:326-28.
- [21]. Kumar H, Chaudhary R, Kaker S. Accessory maxillary ostia: topography and clinical application. *J Anatsoc India*. 2001;50(1):3-5.
- [22]. May M, Sobol SM, Korzec K. The location of the maxillary os and (its importance to the endoscopic sinus surgeon. *Laryngoscope* 1990; 100:1037-1042.
- [23]. Frank DO, Zanation AM, Dhandha VH, McKinney KA, Fleishchman GM, Ebert CS Jr, Senior BA, Kimbell JS.

- Quantification of airflow into the maxillary sinuses before and after functional endoscopic sinus surgery. *Int Forum Allergy Rhinol.* 2013; 3(10):834-40.
- [24]. Rice HD, Schaeffer SD . Endoscopic paranasal sinus surgery. New York:Raven Press ;1993. pp 3-46.
- [25]. Prasanna LC. The location of maxillary sinus ostium and its clinical application. *Indian J Otolaryngol Head Neck Surg* 2010;62:335-37.
- [26]. Kane KJ. Recirculation of mucus as a cause of persistent sinusitis. *Am J Rhinol* 1997;11:361-69.
- [27]. Stammberger HR, Kennedy DW et al. Paranasal Sinuses: anatomic terminology and nomenclature. *Ann Otol Rhinol Laryngol* 1995;104:S7-16.
- [28]. Lang J, Wurzburg. Paranasalsinuses: anatomical considerations, springer verlag; 1991:3-17.
- [29]. Naivete H. Symposium on maxillary sinus: Surgical anatomy of the maxillary sinus. *The Laryngoscope* 1930;40:1-4.
- [30]. Kennedy DW, Zinreich SJ, Rosenbaum AE, Johns ME. Functional endoscopic sinus surgery: theory and diagnostic evaluation. *Arch Otolaryngol* 1985;111:576-82.

How to cite this article:

Anukaran Mahajan, Anupama Mahajan, Karunesh Gupta, Pankaj Verma, Monika Lalit. ANATOMICAL VARIATIONS OF ACCESSORY MAXILLARY SINUS OSTIUM: AN ENDOSCOPIC STUDY. *Int J Anat Res* 2017;5(1):3485-3490. **DOI:** 10.16965/ijar.2016.504