

## STUDY OF VERTICAL DIAMETER OF HEAD OF FEMUR IN SOUTH INDIAN CADAVERS

Ashish Kamdi <sup>\*1</sup>, Ashita Kaore <sup>2</sup>, S. Saritha <sup>3</sup>.

<sup>\*1</sup> Assistant Professor, Department of Anatomy, Chandulal Chandrakar Memorial Medical College, Durg, Chattisgarh, India.

<sup>2</sup> Assistant Professor, Department of Anatomy, Government Medical College, Nagpur, Maharashtra, India.

<sup>3</sup> Professor & Head, Department of Anatomy, Kamineni Academy of Medical Sciences, Hyderabad.

### ABSTRACT

**Introduction:** The hip joint which was originally referred to as a ball and socket joint. The articular surface on the femoral head is a spheroidal or slightly ovoid. The present study was undertaken to note the average diameter of the femoral head in South Indian cadaveric hip joints. This study is done with soft tissues in situ.

**Material and Methods:** The present study was carried out on 50 cadavers, 40 male and 10 female in the age group 30-70 years human cadavers from the department of Anatomy. With the soft tissue in situ and using Vernier calipers of 1/50 mm accuracy, vertical diameter of head of femur was taken.

**Results:** In the present study the average vertical diameter of head of femur was found to be 45.32mm in males and 42.32 mm in females.

**Conclusion:** There is small difference in the vertical diameter of femoral heads of two sides in the same individual, but this is statistically insignificant. The average vertical diameter of head of femur was found to be greater in males than in females. Availability of such data can help in constructing best possible prostheses for patients of total hip replacement.

**KEY WORDS:** Hip joint, Head of Femur, Vernier caliper.

**Address for Correspondence:** Dr. Ashish Kamdi, Assistant Professor, Department of Anatomy, Chandulal Chandrakar Memorial Medical College, Durg, Chattisgarh, India.

Mobile no.: +919522582194 **E-Mail:** drashishkamdi@gmail.com

### Access this Article online

#### Quick Response code



DOI: 10.16965/ijar.2016.318

**Web site:** International Journal of Anatomy and Research  
ISSN 2321-4287  
[www.ijmhr.org/ijar.htm](http://www.ijmhr.org/ijar.htm)

Received: 16 Jul 2016      Accepted: 16 Aug 2016  
Peer Review: 16 Jul 2016    Published (O): 31 Aug 2016  
Revised: None                Published (P): 31 Aug 2016

### INTRODUCTION

The hip joint which was originally referred to as a ball and socket joint is now being described theoretically as a rotational conchoids [1,2]. The closed packed position of hip joint is one of full extension, with slight abduction and medial rotation [3]. The articular surface on the femoral head is a spheroidal or slightly ovoid. The present study was undertaken to note the

average diameter of the femoral head in South Indian cadaveric hip joints. This study is done with soft tissues in situ. This gives the average values to near normal situations as would be encountered in the patients at operation table. Availability of such data can help in constructing best possible prostheses for patients of total hip replacement. Any deviations of these dimensions from normal have strong correlation with development of

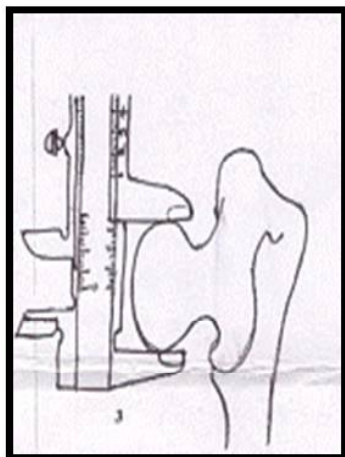
various kinds of pathologies of hip joint [4]. Knowledge of the anatomical parameters of the bony components of hip joint is very essential as it will open new horizons into better understanding of etiopathogenesis of diseases like primary osteoarthritis of hip joint. An incongruous joint is more prone to develop degenerative changes than a joint having normal anatomy [5].

## MATERIALS AND METHODS

The present study was carried out on 50 cadavers, 40 male and 10 female in the age group 30-70 years human cadavers from the department of Anatomy in, Kamineni Institute of Medical Sciences, Narketpally, Deccan Medical College, Hyderabad, Osmania Medical College, Hyderabad, Gandhi Medical College, Hyderabad and the statistical analysis was done in the department of Anatomy, Kamineni Institute of Medical Sciences, Narketpally, Hyderabad, India, After opening of joint cavity during routine dissection, vertical diameters of head of femur were taken using Vernier calipers. Mean values of parameters were recorded and compared between male and females. Mean values of parameters were compared between right and left for both sexes. With the soft tissue in situ and using Vernier calipers of 1/50 mm accuracy, vertical diameter of head of femur was calculated as follows:

**Vertical diameter of femoral head:** This was measured at right angle to the long axis of neck of femur, which means the straight distance between the most superior and the most inferior point on head of femur. **[Fig No. 1]**

**Fig. 1:** Showing vertical diameter of head of femur.



All observations were taken by the same person to avoid interobserver error.

Data collected was entered in MS excel sheet and analysis was carried out by using SPSS software (10.01 versions). Appropriate statistical test was applied wherever required.

Articular surfaces showing any pathological changes, dried, rough and osteoarthritic changes were excluded from study.

## OBSERVATIONS AND RESULTS

Mean of the values for vertical diameter of head of femur of 80 male and 20 female hip joints were taken. The mean vertical diameter of head of femur for 40 right and 40 left side hip joints in male and 10 right and 10 left side hip joints in females were taken. The mean values for both the parameters were calculated for 80 male hip joints and 20 female hip joints, which included hip joints of both sides. These values are given in Table 1.

In males the mean values of right side were compared with corresponding left side values [Table 2]. In females the mean values of right side were compared with corresponding left side values [Table 3].

Mean values of right side in males were compared with corresponding values on right side in females [Table 4].

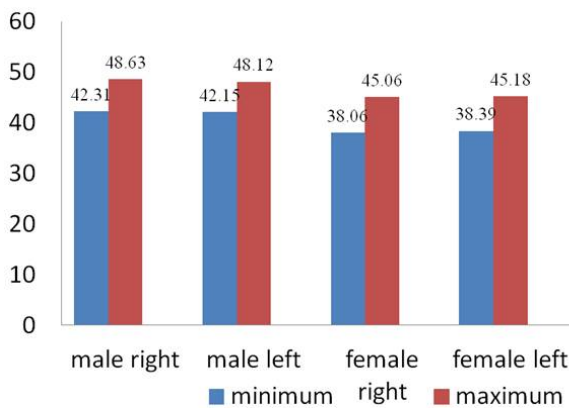
Mean values of left side in males were compared with corresponding values on left side in females [Table 5].

From the observations it was noted that the mean of all the parameters were more on left side than on right side. But there was no statistically significant difference.

In females the mean values of the parameters

was more on left side than on the right. But there was no statistically significant difference between right side and left side measurements. A comparison was done between measurements of male and female. It was noted that the mean of all the parameters were more for males than females, both on right and left side. The difference was statistically significant.

**Fig. 2:** Vertical diameter of head of femur (in mm).



**Table 1:** Vertical diameter of head of femur (in mm).

	Male (n=40)		Female(n=10)	
	Right(40)	Left (40)	Right (10)	Left (10)
Minimum Value	42.31	42.15	38.06	38.39
Maximum Value	48.63	48.12	45.06	45.18
Mean	45.23	45.4	42.17	42.46
Standard deviation	1.66	1.64	2.41	2.366

**Table 2:** Comparison of left side parameters with right side in males (in mm).

Parameter	Left			Right			P value
	n	Mean	S.D	n	Mean	S.D	
Vertical diameter of head of femur	40	45.4	1.64	40	45.23	1.66	N.S (P>0.05)

**Table 3:** Comparison of left side parameters with right side in females (in mm).

Parameter	Left			Right			P-VALUE
	n	Mean	S.D	n	Mean	S.D	
Vertical diameter of head of femur	10	42.46	2.36	10	42.17	2.41	N.S (P>0.05)

**Table 4:** Comparison of Parameters between Males and Females (In mm).

	Males				Females			
	side	N	Mean	S.D	n	Mean	S.D	P value
Vertical diameter of head of femur	Left	40	45.4	1.64	10	42.46	2.36	P<0.05 (significant)
	Right	40	45.23	1.66	10	42.17	2.41	P<0.05 (significant)

**Table 5:** Comparative study of vertical diameter of head of femur (in mm).

Present study	45.32	42.32
Thomas Dwight (1905)	49.68	43.84
Rajendra Prasad et al (1996) [12]	43	39.1
Asala (2001) [9]	48.40 (whites) 44.51(blacks)	42.32(whites) 39.81(blacks)
Ruma Purkait & Heeresh (2002) [10]	44.28	38.39
Chauhan Paul & Dhaon (2002) [4]	45.64	44.27
Varma (2010)	44.54	39.58

## DISCUSSION

In the present study the average vertical diameter of head of femur was found to be 45.32mm in males and 42.32 mm in females. Javadekar (1961) measured the vertical diameter of head of femur in cadavers. He found the mean vertical diameter of head of femur to be 45.26 mm in males and 40.37 mm in females [6]. Gita Mall et al in 2000 studied femoral dimensions in German population, they found vertical diameter of head of femur in males to be 4.9± 0.3 cm and 4.4± 0.3 cm in females[7]. P.S. Igbigli and B. C. Sasmati in 2000 studied x- ray films of 496 pelvis of adult black patients found the vertical diameter of head of femur in males 48.30 mm, where as in females the vertical diameter of head of femur was found to be 47.48mm [8]. Asala (2001) studied on femora in Africa showed the average vertical diameter of head of femur to be 48.40 mm in white males and 42.32 mm in white females. The same for blacks of African origin was 44.51 in males and 39.81 in females [9]. Ruma Purkait and Heeresh Chandra (2002) in their study on dry femora found the average vertical diameter of head of femur to be 44.28 mm in males and 38.29 mm in females [10]. Chauhan, Paul and Dhaon (2002) found that the average vertical diameter of head of femur was 45.64 mm in males and 44.27 mm in females on cadavers[4]. Varma and J.P.Nalini (2010) studied the south Indian cadavers and found the average vertical diameter of head of femur to be 44.54 mm in males and 39.58 mm in females [11]. Studies by Rajendra Prasad et al. (1996), Asala (2001), and Ruma Purkait and Heeresh Chandra (2002), Varma and J.P.Nalini (2010) show statistically significant difference in vertical diameter of



head of femur between males and females [13,10-12].

According to Chauhan, Paul and Dhaon (2002) the difference between male and female vertical diameter of head of femur was not statistically significant[4]. According to Ruma Purkait and Heeresh Chandra (2002) this sex difference in vertical diameter of head of femur is based on the fact that the male skeleton is more longer and more robust than the average female, although the magnitude of difference varies from population to population[11]. The present study showed statistically significant difference in vertical diameter of head of femur between males and females. These finding correlated with that of Rajendra Prasad et al. (1996), Asala (2001), and Ruma Purkait and Heeresh Chandra (2002), Varma and J.P.Nalini (2010)[13,10-12]. It does not correlate with the work by Chauhan, Paul and Dhaon (2002) which showed no statistically significant difference between male and female vertical diameter of head of femur [4]. Comparison of findings of various workers given in Table no 5.

In the present study the mean vertical diameter of head of femur was greater on left side in both males and females but this is not statistically significant. According to Chauhan, Paul and Dhaon the mean vertical diameter of head of femur is greater on left side in both males and females[4]. Our study correlates with the findings of Rajendra Prasad et al. (1996), Asala (2001), Varma and J.P. nalini (2010), but it does not correlate with findings of Chauhan, Paul and Dhaon (2002)[13,10,12,4].

## CONCLUSION

The vertical diameter of head of femur has been measured in 50 cadavers (40 male and 10 female) in the present study. The average vertical diameter of head of femur was found to be 45.32 mm in males and 42.32 mm in females. There is small difference in the vertical diameter of femoral heads of two sides in the

same individual, but this is statistically insignificant. The average vertical diameter of head of femur was found to be greater in males than in females. The vertical diameter of head of femur is of advantage when the complete bone is not available for use in sex determination.

**Conflicts of Interests: None**

## REFERENCES

- [1]. Menschik A. Biometric, Springer, Berlin, Heidelberg, New York 1987.
- [2]. Menschik, F. The shape and Kinematics of the hip joint. *Journal of Bone and Joint Surgery (British)*. 1993;75(2):111.
- [3]. Peter Williams L. *et al.* Gray's Anatomy, 40<sup>th</sup> edition, pp 1387 - 1392, Churchill Livingstone
- [4]. Chauhan R, Paul S and Dhaon BK. Anatomical Parameters of North Indian Hip joints- Cadaveric study. *Journal of Anatomical Society of India* 2002;51(1):39-42.
- [5]. Murray RO. Aetiology of primary osteoarthritis of the hip. *British Journal of Radiology* 1965;38:810-824.
- [6]. Javadekar BS. A study of measurements of femur with special reference to sex. *Journal of Anatomical Society of India* 1961;10:25-27.
- [7]. Gita Mall, Matthias Graw, Kristina-D. Gehring, Michael Hubig. Determination of sex from femora. *Forensic*, September 2000; 113(1-3):315-321.
- [8]. P.S. Igbigbi, and B.C. Msamati. Sex determination from femoral head diameters in black malawians. *East African Medical Journal*. 2000;7(3):147-151.
- [9]. Asala SA, Mbojiorgu FE and Papandro BA. A comparative study of femoral head diameters and sex differentiation in Nigerians. *Acta Anatomica* 1998;162:232-237.
- [10]. Ruma Purkait and Heeresh Chandra. Sexual dimorphism in femora – An Indian study. *Forensic Science Communication* 2002;4(3).
- [11]. C Lavanya Varma and J.P.Nalini. Anatomical parameters of hip joint – Human cadaveric study. *Anatomica Karnataka* 2010;4(2):23-27.
- [12]. Rajendra Prasad, Selvakumar Vettival, Jayaseelan L, Isaac B and Chandi G. Reconstruction of femur length from the makers of its proximal end. *Clinical Anatomy* 1996;9:28-33.

### How to cite this article:

Ashish Kamdi, Ashita Kaore, S. Saritha. STUDY OF VERTICAL DIAMETER OF HEAD OF FEMUR IN SOUTH INDIAN CADAVERS. *Int J Anat Res* 2016;4(3):2730-2733. DOI: 10.16965/ijar.2016.318