

A STUDY OF ANATOMICAL VARIATIONS IN THE BRANCHING PATTERN OF ARCH OF AORTA

Anupama D *¹, Vinay Kumar K ¹, R Lakshmi Prabha Subhash ².

¹ Associate Professor, Department of Anatomy, Sri Siddhartha Medical College, Tumkur, Karnataka, India.

² Professor and Head, Department of Anatomy, Sri Siddhartha Medical College, Tumkur, Karnataka, India.

ABSTRACT

Background: To study the anatomical variations in the branching pattern of Arch of Aorta in Indian subjects and to discuss their surgical anatomy on embryological basis.

Materials and Methods: In our study, branching pattern of the arch of aorta was studied in 30 cadaveric hearts of both sexes of Indian origin. The specimens were studied by gross anatomical dissection which was carried out in the Department of Anatomy at Sri Siddhartha Medical college, Tumkur and the variations in the branches of aorta were Observed.

Results: The usual three-branching pattern of Arch of Aorta were found in 27 cadavers (90%); Variations were found in 3 cadavers (10%); 2 of them (6.67%) presented common origin of the Brachiocephalic trunk and left Common carotid arteries (Common Brachio Cephalic Trunk, CBCT); One cadaver (3.33%) presented anomalous origin of left vertebral artery directly from the Arch of Aorta. All 3 cadavers with anomalous aortic arch branching pattern were males.

Conclusion: Anomalies of the aortic root vessels may present in adults and are common incidental findings during standard vascular imaging. Knowledge of their presentation and management is important for surgeons dealing with vascular pathology within these anomalous vessels & of value for a safe attempt in suitable position for catheterization & other surgical procedures.

KEY WORDS: Arch of Aorta, Brachio cephalic trunk, Common Carotid artery, Vertebral artery, Variations.

Address for Correspondence: Dr. Anupama D. MBBS., MD, Associate Professor, Department of Anatomy, Sri Siddhartha Medical College, Tumkur, 572107, Karnataka, India. Mob: +919449217373
E-Mail: dranupama7373@gmail.com.

Access this Article online

Quick Response code



DOI: 10.16965/ijar.2016.315

Web site: International Journal of Anatomy and Research
ISSN 2321-4287
www.ijmhr.org/ijar.htm

Received: 15 Jul 2016 Accepted: 16 Aug 2016
Peer Review: 15 Jul 2016 Published (O): 31 Aug 2016
Revised: None Published (P): 31 Aug 2016

INTRODUCTION

Anatomical variations of Arch of Aorta and supra aortic arteries have been well documented in anatomical as well as post mortem studies. Most of the variations encountered are as a result of variations in the disappearance or persistence of parts of primitive aortic arches [1]. As described in some standard anatomical text

books the most common pattern of origin of branches from Arch of Aorta is where the Brachio cephalic trunk is the first and largest vessel on to the right, followed by the left Common carotid artery and then the left Subclavian artery [2,3]. The Brachiocephalic artery, the largest and most anterior of all the branches arises from the midline which ascends to the

right and then divides to give Right Common Carotid and Right Subclavian Arteries, the Left Common Carotid artery. The left Common Carotid and left Subclavian arteries arise independently from the aortic arch in close succession beyond the brachiocephalic artery. The carotid and the subclavian arteries ascend more or less vertically along the left side of the Trachea. Near their origin all the 3 vessels are crossed anteriorly by the left brachiocephalic vein. The 3 major branches do not give off any branches in the thorax. Adachi has reported that in 64-65% of the cases, the 3 branching pattern of origin [4]. In 11% of the cases there are only two branches arising from the arch in which the Brachiocephalic trunk and left common carotid artery have a common trunk and the other being left Subclavian artery. The third common variant is the origin of vertebral artery directly from arch of aorta. In less than 1% of the cases other uncommon variations like two Brachiocephalic trunks, origin of Coronary artery from the arch and origin of left Subclavian artery from the descending thoracic aorta have been reported [5]. The knowledge of these variations is very important in carrying out various surgical procedures in the region.

OBSERVATIONS

We report observations of rare anatomical variations in the branching pattern of Arch of Aorta. During routine dissection for the undergraduate students in the Department of Anatomy, SSMC, Tumkur, less common variations were noticed in which the Brachiocephalic trunk and the left Common carotid artery were incorporated in a common trunk originating from the upper convex surface of the proximal end of left sided arch of aorta and the left Subclavian artery arising independently from the same surface more posteriorly distal to the origin of common trunk in 2 specimens (as shown in Fig 1). The Common Brachiocephalic trunk measured 1.8 cms in length and 1.6cms in 1 specimen and 1.2cms in length and 1.4 cms diameter in another specimen which were directed to the right and further divided in to Brachiocephalic trunk and left Common carotid artery. It was related to left brachiocephalic vein anteriorly in its course. The Brachiocephalic

trunk had normal measurements and course further and showed the usual branching pattern. The left Common carotid arteries arose anterior to trachea to the left. The left Subclavian artery arose more posteriorly from the arch in both the cases, but had a usual course. In another specimen left Vertebral artery arose directly from Arch of Aorta (as shown in Fig 2) distal to the origin of Brachiocephalic trunk & Left Common Carotid artery and was seen coursing in front of the Trachea.

Fig. 1: Origin of Common brachiocephalic trunk from arch of aorta.

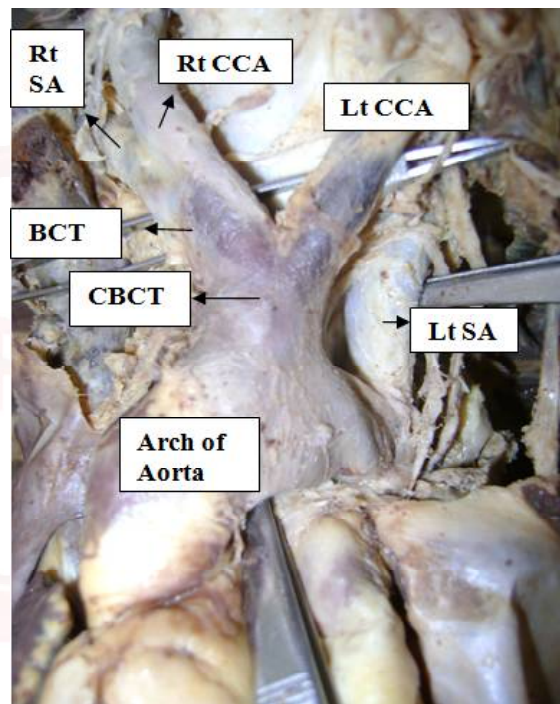



Fig. 2: Origin of Left vertebral artery directly from arch of aorta.



DISCUSSION

There are many studies about the variations in the branching pattern of arch of aorta. The one described in this case report has an embryological basis [6]. The left horn of aortic sac normally forms part of the arch that intervenes between the origin of brachio cephalic trunk and left common carotid artery. If the aortic sac fails to bifurcate, then the left common carotid artery gets connected to the aortic sac directly. This results in the common origin of carotid arteries and right subclavian artery. Anomalies of the aortic root vessels may be classified on their presence or absence, their anomalous size or course, or their atypical origin, bifurcation or subsequent branching pattern. The reports from clinical cases say that the anomalous arteries are more prone to atherosclerotic changes and aneurysms. 98% of the cases with common brachio cephalic trunk said to have associated congenital cardio vascular anomalies like hypoplasia of the arch and coarctation of aorta. An occlusion of common brachio cephalic trunk may bring about significant changes in the cerebro vascular hemodynamics as majority of the vessels supplying the brain are arising from it [Right & Left common carotid and Right vertebral arteries] [7].

CONCLUSION

These variations should be kept in mind during mediastinal surgeries to avoid many complications. Knowing the variations in the origin of supra aortic arteries is of great importance to thoracic as well as head & neck surgeons and radiologists to perform diagnostic procedures. Knowledge of aortic arch and root vessel anomalies is important for any clinician dealing with cardiothoracic, head and neck, or intracranial pathology. Vascular surgeons may encounter these anomalies during routine practice and may need to deal with their clinical sequelae.

Conflicts of Interests: None

REFERENCES

- [1]. Soubhagya. R. Nayak; Mangala M Pai; Latha V Prabhu; Sujatha D'Costa; Prakash shetty, Journal Vascular Brasiiiro.vol.5 no.2 Porto alegre, June 2006
- [2]. Williams PL,Warwick R'Dyson M'Bannister LH. Gray's Anatomy, 37th ed. Edinburgh. 1989. pp733-734.
- [3]. McMinn R. Last's Anatomy, Regional and Applied.8th ed. Edinburgh; Churchill Living stone; 1990. pp. 257-259.
- [4]. Ozen Karabulut, Kenan Il timur,M Cudi Tuncer. Coexisting of aortic arch variation of the left common carotid artery arising from the brachio cephalic trunk and absence of main branches of right subclavian artery: a review of the literature. Romanian Journal of morphology & Embryology 2010;51(3):569-72.
- [5]. 5.Variations in the aortic arch branches : Two main trunks originating from the aortic arch Fatih YAZAR.MD, Bilient YALCIN, M.D Gazi Medical Journal 2003; 14:181-184.
- [6]. Moore KL'Persaud TV. The Developing Human 'Clinically Oriented Embryology'.5th ed.Philadelphia:WB Saunders Co;1993.pp.338-340
- [7]. A three brnches aotrtic arch variant with a bicarotid trunk and a retro esophageal right subclavian artery Mligiliche NL, Isaac ND International Journal of Anatomical Variations 2009;2:11-14.

How to cite this article:

Anupama D, Vinay Kumar K, R Lakshmi Prabha Subhash. A STUDY OF ANATOMICAL VARIATIONS IN THE BRANCHING PATTERN OF ARCH OF AORTA. Int J Anat Res 2016;4(3):2717-2719. DOI: 10.16965/ijar.2016.315