

Case Report

UNILATERAL ATYPICAL VARIATION IN THE BRANCHING PATTERN OF PROFUNDA FEMORIS ARTERY AND ITS CIRCUMFLEX BRANCHES: CLINICO-EMBRYOLOGICAL ANNOTATION

Shilpi Garg ^{*1}, Shilpi Agarwal ¹, Babita Pangtey ².

^{*1} Senior resident, Department of Anatomy, Maulana Azad Medical College, New Delhi, India.

² Assistant Professor, Department of Anatomy, Maulana Azad Medical College, New Delhi, India.

ABSTRACT

Background: Femoral artery is frequently accessed by radiologists and surgeons. Anatomical knowledge of the variations of femoral artery and its branches including profunda femoris, medial and lateral femoral circumflex arteries is required to minimize complications during clinical procedures in the femoral region and hip joint replacement.

Case Report: We report a unilateral variation in the branching pattern of profunda femoris artery and its circumflex branches in the femoral triangle of left side in middle aged old male formalin preserved cadaver. The variations were noted, measured and appropriately photographed.

Observations: The profunda femoris artery was arising from the posterior-medial aspect of femoral artery approximately 4-5 cm below the inguinal ligament and medial & lateral circumflex arteries was arising from femoral artery along with profunda femoris artery. The embryological and clinical implications of the observed variations are discussed.

Conclusion: Knowledge of such variations in the branching pattern of femoral artery should be considered before planning different diagnostic and therapeutic interventions.

KEY WORDS: Femoral artery, Lateral circumflex femoral artery, Medial circumflex femoral artery, Profunda femoris artery, VEGF, Vascular Endothelial Growth Factor.

Address for Correspondence: Dr. Shilpi Garg, Senior resident, Department of Anatomy, Maulana Azad Medical College, New Delhi, India. **E-Mail:** mdshilpi@gmail.com

Access this Article online

Quick Response code



DOI: 10.16965/ijar.2016.255

Web site: International Journal of Anatomy and Research
ISSN 2321-4287
www.ijmhr.org/ijar.htm

Received: 05 June 2016 Accepted: 14 June 2016
Peer Review: 05 June 2016 Published (O): 30 June 2016
Revised: None Published (P): 30 June 2016

INTRODUCTION

The femoral artery is easily accessible to catheterization. The profunda femoris artery is used for arteriography, ultrasound and Doppler imaging, digital subtraction angiography and magnetic resonance imaging. In the recent era, profunda femoris is being used for hemodialysis other than femoral artery and also the branches of profunda femoris are used in

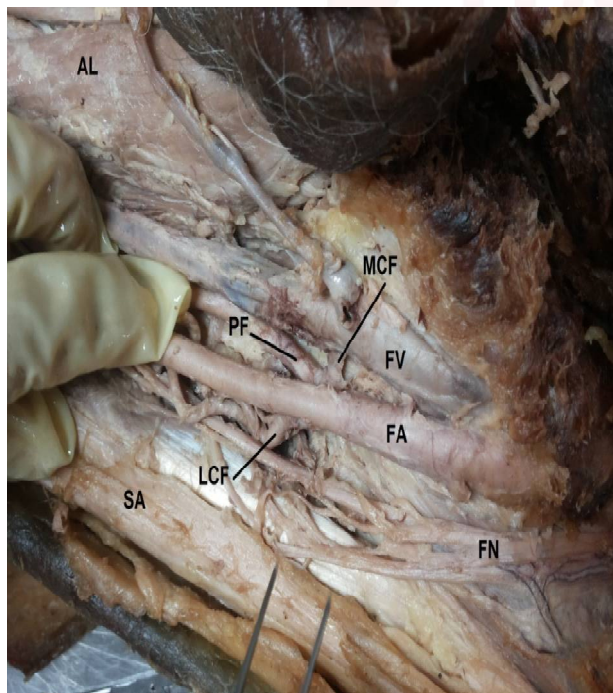
anterolateral perforator thigh flap as long vascular pedicle during breast reconstruction after mastectomy in cases of carcinoma of breast [1].

The profunda femoris artery emerges from the posterolateral aspect of the femoral artery in the femoral triangle approximately 4-5 cm below the inguinal ligament [2]. The origin of the profunda femoris is sometimes medial or rarely posterior on the femoral artery. This is the

main artery which supplies the adductor, extensor and flexor muscles of the thigh. The branches of profunda femoris artery are medial and lateral circumflex femoral arteries and four perforating arteries. The lateral circumflex artery is the lateral running branch given off near the root of the profunda, it passes between the division of the femoral nerve posterior to Sartorius and rectus femoris and divides into ascending transverse and descending branches. Medial circumflex artery arises from the posterior medial aspect of profunda femoris artery but often arises from the femoral artery [3]. Therefore the knowledge of anatomy of level of origin of profunda femoris artery and its branches is important to minimize complications associated with Transfemoral angiographic procedures and various surgeries.

CASE REPORT

Fig. 1: Showing the Branching pattern of the femoral artery.



FA- femoral artery, FV- femoral vein, FN- femoral nerve, PF- profunda femoris artery, MCF- medial circumflex femoral, LCF- lateral circumflex femoral, SA- Sartorius muscle, AL- Adductor longus muscle.

During routine dissection of middle aged old male cadaver for the teaching of undergraduate medical students in the Department of Anatomy at Maulana Azad Medical College, New Delhi, a variant branching pattern of profunda femoris and its circumflex branches was

observed in the left lower limb. At the base of femoral triangle the femoral vein, femoral artery and femoral nerve were placed as usual from medial to lateral side. In the middle of the femoral triangle 4-5 cm below the mid inguinal point, (Figure 1) the profunda femoris artery was arising from the posteromedial aspect of femoral artery. The medial circumflex femoral artery was arising from the femoral artery just superior to the origin of profunda femoris artery as a common stem with lateral circumflex femoral artery. Lateral circumflex artery was giving the ascending, transverse and descending branches and was running between the divisions of femoral nerve posterior to the Sartorius and rectus femoris muscle. The tributaries of femoral vein and femoral nerve had normal course and distribution. No muscular variation was observed. The other side was unremarkable.

DISCUSSION

The present study is an attempt to report unusual disposition of the branching pattern of profunda femoris artery and its circumflex branches in the femoral triangle for the benefit of the radiologists and reconstructive surgeons. The presence of variations in the relationship of branching pattern of femoral vessels can be explained on the basis of the embryologic development of the arterial network of lower limb.

Blood vessels forms in two ways; vasculogenesis and angiogenesis. The first blood island appears in mesoderm at 3 weeks of development induced to form haemangioblast a common precursor for vessel and blood cell formation. FGF2(Fibroblast Growth Factor) induces mesodermal cells to form haemangioblasts .VEGF(Vascular endothelial growth factor) differentiates the haemangioblast to form blood cells/vessels .Once the process of vasculogenesis establishes a primary vascular bed, additional vasculature is added by angiogenesis ;sprouting of new blood vessels .Both these process are regulated by VEGF until adult pattern is established [4].

Embryologically, the dorsal sciatic artery forms the main blood supply of the lower limb when the embryo is 10 mm long The femoral artery

becomes the main vessel to the lower limb during the 14 mm embryo stage as a continuation of the external iliac artery. Profunda femoris artery is derived from arterial plexus which envelops the femur as early as the stage of 14 mm, the proximal end of artery. The circumflex lateralis arises from the femoral trunk shortly before the stage of 14 mm. although this artery is commonly regarded as branch of profunda artery, its original connections with femoral artery is frequently retained in the adults. The circumflex medialis is not present at the stage of 22 mm. this explain the basis of more incidence of medial circumflex artery arising from femoral artery as compared to lateral circumflex artery. Vessel outgrowth is patterned, not random and appears to involve guidance factors. Any disturbances in this mechanism give rise to altered pattern of blood vessels. Developmental arrest at different stages may lead to anatomical variations related to the division of the femoral artery and its branches [5].

The most common site for origin of profunda femoris artery is posterolateral aspect of femoral artery [3,6]. But in our study profunda femoris artery was arising from the posteromedial aspect of femoral artery, which is comparable to the study done by Dixit et al. (2001) where in (39%) cases the profunda femoris artery was arising from the medial or posterior aspect of femoral artery [7].

In our study medial and lateral circumflex arteries were arising from the femoral artery as a common stem with profunda femoris artery. Baptist et al (2007) reported the origin of lateral circumflex femoral artery from the femoral artery [8]. Tanyeli E et al. (2006) reported the origin of medial circumflex femoral artery from the femoral artery in 21% cases [9]. Gautier et al. (2000) also reported prevalence of origin of medial circumflex femoral artery from femoral artery in 16.7% cases [10]. Uzel. M et al. studied 110 inguinal regions and found lateral circumflex femoral artery arising from profunda femoris artery in 77.3% cases and from femoral artery including common stem in 22.7% cases [11]. Fukuda H et al in [2005] reported 78.6% cases where lateral circumflex femoral artery was

originated from the profunda femoris artery and 21.4% cases wherein it originated from femoral artery including common stem [12]. According to Siddharth et al. [1985] medial circumflex femoral artery usually arises from the posteromedial aspect of profunda femoris artery but may originate from the femoral artery or as a common trunk with the lateral circumflex artery. These findings are similar and comparable to our findings. Awareness of such variations in the vascular anatomy of femoral triangle certainly deserves documentation in the scientific literature and will be extremely helpful to the surgeons for the diagnosis as well as to avoid unexpected complications while planning surgery of this region.

CONCLUSION

A meticulous understanding of the branching pattern of the profunda femoris artery and its circumflex branches is important prior to attempting any diagnostic or therapeutic intervention in this region. The anatomical variations related to the branching pattern of profunda femoris artery is due to the development arrest at different stages.

Conflicts of Interests: None

REFERENCES

- [1]. Kaplan JL, Allen RJ. A cost based comparison between perforator flaps and TRAM flaps. *Plast Reconstr Surg* 2000;105(3):943-948.
- [2]. Hollinshead HW. *Buttock, Hip joint and thigh, Profunda femoris artery.* In: *Anatomy for surgeons: Vol. 3. The back and limbs.* 2nd ed. Hoeber Medical Division, Happer & Row Publishers, New York, Evanston and London, 1969;2(3): 725-730.
- [3]. Standing S. *Pelvic girdle, Gluteal region and hip joint, Profunda femoris artery.* In: *Gray's Anatomy, The anatomical basis of clinical practice.* 40th ed. Elsevier Churchill Livingstone, 2008:1379-1380.
- [4]. Sadler. T. W: *Langman's Medical Embryology*, 12th edition. Lippincott Williams &Wilkins: Philadelphia; 2012:75-77.
- [5]. Senior HD. *The development of the arteries of the human lower extremity.* *Am.J Anat* 1919;23:55-95.
- [6]. Mc Minn R.M.H. (1994) *Last's Anatomy*, 9th ed., London, Churchill Livingstone, 155-6
- [7]. Dixit D., Kubavat D., Rathod S., Patel M., Singel T. (2011) *Int. J. Biol. Med. Res.*(1994);2(4):1084-1089.
- [8]. Baptist M, Sultana F, Hussain T. *Anatomical variation of the origin of profunda femoris artery, its branches and diameter of the femoral artery.* *Professional Med J* 2007;14(3):523-527.

- [9]. Tanyeli E, Yildirim M, Uzel M, Ural F. Deep femoral artery with 4 variations – a case report. *Surg Radiol Anat* 2006; 28(2): 211-213.
- [10]. Gautier E, Ganz K, Krügel N, Gill T, Ganz R, Anatomy of the medial femoral circumflex artery and its surgical implications, *J Bone Joint Surg Br*, 2000, 82(5):679-683.
- [11]. Uzel M, Tanyeli E, Yildirim M. Anatomical study of the origin of lateral circumflex femoral artery in Turkish population. *Folia Morphol (Warsz)* 2008;67(4):226-230.
- [12]. Fukuda H, Ashida M, Ishii R, Abe S, Ibukuro K. Anatomical variants of the lateral femoral circumflex artery: an angiographic study. *Surg Radiol Anat* 2005;27(3): 260-264.
- [13]. Siddharth P, Smith NL, Mason RA, Giron F. Variational anatomy of the deep femoral artery. *Anat Rec* 1985;212(2):206-209.

How to cite this article:

Shilpi Garg , Shilpi Agarwal, Babita Pangtey. UNILATERAL ATYPICAL VARIATION IN THE BRANCHING PATTERN OF PROFUNDA FEMORIS ARTERY AND ITS CIRCUMFLEX BRANCHES: CLINICO-EMBYOLOGICAL ANNOTATION. *Int J Anat Res* 2016;4(2):2508-2511. **DOI:** 10.16965/ijar.2016.255