

## Case Report

# MULTIPLE VARIATIONS IN A SINGLE CADAVER: ITS CLINICAL IMPLICATIONS

Ambica Wadhwa \*<sup>1</sup>, Sandeep Soni <sup>2</sup>.

<sup>1</sup>Department of Anatomy, Punjab Institute of Medical Sciences, Jalandhar, Punjab, India.

<sup>2</sup>Department of Chest & TB, Punjab Institute of Medical Sciences, Jalandhar, Punjab, India.

## ABSTRACT

Anomalous blood vessels are always interesting from a purely scientific point of view, especially as they so often shed light on obscure problems of phylogeny and ontogeny. Variations in the vascular supply is of clinical importance to the general and vascular surgeons and to those who specialize in either urology or gynecology. During routine dissection multiple variations in the abdominal aorta and its branches were observed. Variations of origin and course of arteries of different organs are not only of anatomical and embryological interest but also of practical and clinical importance when these variations can be the agents of pathological conditions, or in surgery when knowledge of them can result in more accurate treatment. With the development of techniques of arteriography, the knowledge of arteries and of their variations has acquired a special importance for correct interpretation of the different, and sometimes very complicated roentgenographic pictures.

**KEY WORDS:** Coeliac trunk, Abdominal aorta, Renal artery, Tortuous.

**Address for Correspondence:** Dr. Ambica Wadhwa, Professor & Head, Department of Anatomy, Punjab Institute of Medical Sciences . Garha road, Jalandhar, Punjab, India.

**E-Mail:** [ambicasoni02@yahoo.com](mailto:ambicasoni02@yahoo.com)

## Access this Article online

### Quick Response code



DOI: 10.16965/ijar.2016.250

**Web site:** International Journal of Anatomy and Research  
ISSN 2321-4287  
[www.ijmhr.org/ijar.htm](http://www.ijmhr.org/ijar.htm)

Received: 26 May 2016	Accepted: 14 June 2016
Peer Review: 28 May 2016	Published (O): 30 June 2016
Revised: None	Published (P): 30 June 2016

## INTRODUCTION

The renal arteries vary on the two sides and in different individuals, in terms of calibre, level of origin and precise topographic relationships [1]. Variations in the renal arterial pattern in main consist predominantly of multiple independent vessels [2]. Impairment of the renal arterial supply caused either by disease process or by surgical manipulation, may result in the production of pressure substances by the involved kidney and subsequent development of systemic hypertension. Therefore in plastic procedures involving the renal pelvis or ureter or even in procedures involving simple ligation and severance of an accessory renal artery,

familiarity with the variations in the vascular supply is mandatory [3].

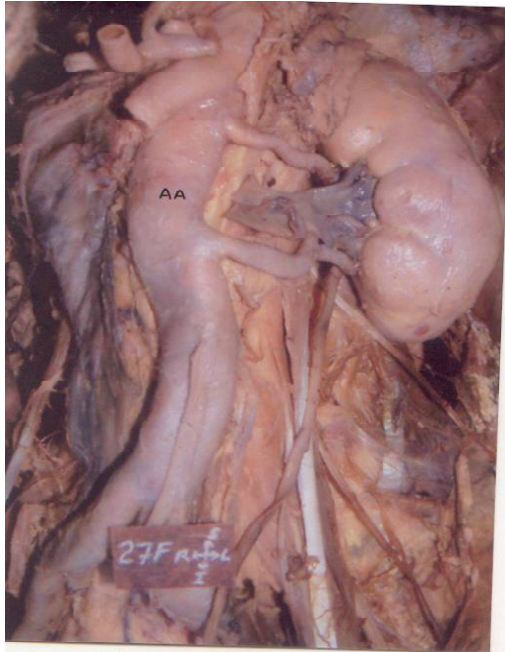
Anatomical variations involving the visceral arteries are common. However though variations in coeliac trunk are usually asymptomatic, they may become important in patients undergoing diagnostic angiography for gastrointestinal bleeding or prior to an operative procedure [4].

Vessel curvature or tortuosity has usually been ignored in haemodynamic studies of the vasculature, vessels are commonly assumed to be straight and axisymmetric. This assumption is generally not valid and even for those vessels which are relatively straight in early life, such as abdominal aorta there is a tendency to

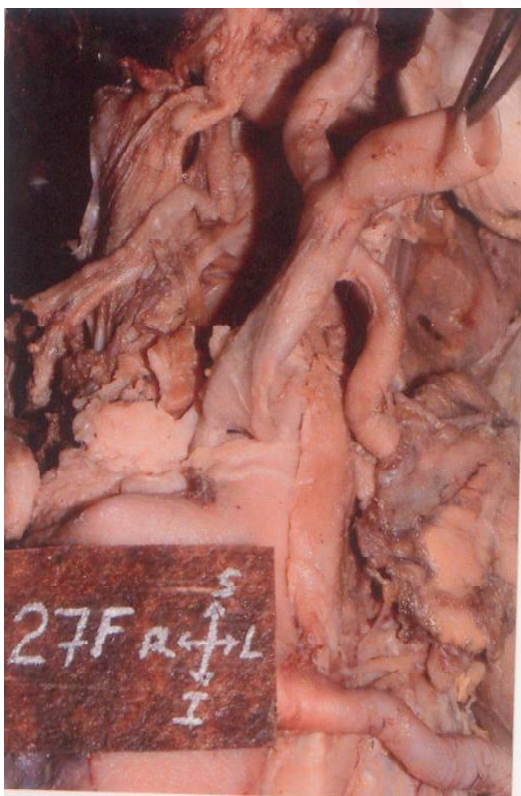develop tortuosity. The arterial tortuosity syndrome is a rare congenital connective tissue disorder characterised by elongation and generalised tortuosity of the major arteries including the aorta. It is also associated with hypextensible skin and hypermobility of joints.

### CASE REPORT

**Fig. 1:** Tortuous course of abdominal aorta with double renal arteries on the left side.



**Fig. 2:** Showing a long Coeliac trunk of length 21mm.



During routine dissection of a male cadaver, multiple variations in the abdominal aorta and its branches were observed. The variations encountered were:

1. Double renal arteries on the left side with a distance of 3cms between the two arteries. Both the arteries entered the hilum of the kidney where they divided into segmental branches. The caliber of inferior renal artery was more than the superior renal artery. On the right side, there was a single renal artery.
2. Length of coeliac trunk was more than normal i.e., 21mm.
3. Abdominal aorta had a tortuous course with deviation to the right against vertebrae L2 and L3 and deviation to the left against L3 and L4.

### DISCUSSION

The unusual embryological development of the ventral splanchnic arteries can lead to considerable variations in the origin of coeliac trunk. Cavdar et al [5] reported that a long coeliac trunk is always associated with a varied origin of left gastric artery from aorta, hepatic or splenic artery. However, they also reported one case in which a long coeliac trunk (43mm), the longest reported in literature gave origin to left gastric artery.

The interpretation of multiple renal arteries and the great variations found in their branching may be explained from the standpoint of embryology in that the permanent kidney of mammals must be considered as the posterior portion of the primitive excretory organ. From ontogenetic and phylogenetic point of view much variation in renal blood vessels of man is to be expected [6]. Multiple branches which enter the extremities of the kidney constitute a danger in nephrotomy and in partial resection of the kidney [7].

The supernumerary or accessory renal arteries are of common occurrence and are more likely to be present than absent and may constitute a danger in nephrotomy and in partial resection of the kidney [8]. There is no established criterion for accessory renal artery as varied descriptions of these vessels have been found in literature. An accessory renal artery is an additional artery in the

renal pedicle, or a vessel entering the kidney at either pole, whether derived from the main renal artery, from the aorta or from a branch of the aorta [9].

Tortuous abdominal aorta is also one of the causes causing compression of inferior vena cava. This may result in centrilobular congestion and necrosis ultimately leading to fibrosis and cirrhosis of liver. Feller and Woodburne [10], documented the lateral deviation of abdominal aorta to be of clinical significance since it may be mistaken for an aneurysm when palpated through the abdominal wall as a pulsatile mass.

**Conflicts of Interests: None**

## REFERENCES

- [1]. Williams PL, Bannister LH, Berry MM, Collins P, Dyson M, Dussek JE et al. Cardiovascular system. In Gray's Anatomy 38<sup>th</sup> Ed. Churchill Livingstone Edinburg 1995:1547.
- [2]. Reis RH and Esenther G. Variations in the pattern of renal vessels and their relation to the type of posterior vena cava in man. *Am J Anat* 1959;104:295-318.
- [3]. Anson BJ and Daseler EH. Common variations in renal anatomy, affecting blood supply, form and topography. *Surg Gynae Obst* 1961;112:439-449.
- [4]. Ray CE, Gupta AK, Shenoy SS. Left gastric artery arising from the superior mesenteric artery. *Angiology*, 1998;49:1017-1021.
- [5]. Cavdar S, Sehirli U, Pekin B. Celiacomesenteric trunk. *Clinical Anatomy* 1997;10:231-234.
- [6]. Rupert RR. Further study of irregular kidney vessels as found in one hundred eighteen cadavers. *Surg Gynae Obst* 1915;21:471-80.
- [7]. Anson BJ, Richardson GA, Minear WL. Variations in the number and arrangement of the renal vessels: a study of the blood supply of four hundred kidneys. *J Urol* 1936;36:211-19.
- [8]. Anson BJ, Cauldwell EW, Pick JW, Beaton LE. The blood supply of the kidney, suprarenal gland and associated structures. *Surg Gynae Obst* 1947;84:313-320.
- [9]. Graves FT. The aberrant renal artery. *J Anat* 1956;90:553-558.
- [10]. Feller I and Woodburne RT. Surgical anatomy of the abdominal aorta. *Ann Surg* 1961;154:239-52.

### How to cite this article:

Ambica Wadhwa, Sandeep Soni. MULTIPLE VARIATIONS IN A SINGLE CADAVER: ITS CLINICAL IMPLICATIONS. *Int J Anat Res* 2016;4(2):2490-2492. DOI: 10.16965/ijar.2016.250