

AN ADAPTATIONAL CHANGE OF EVOLUTIONARY SIGNIFICANCE IN PERONEAL TENDONS: AN ANOMALOUS PERONEUS QUARTUS AND A PROXIMALLY MIGRATED PERONEUS BREVIS TENDON

Sheela Grace ¹, Preethi Ramya T ², Anjana TSR ^{*3}.

¹ Professor and Head, Department of Anatomy, Karpagam Institute of Medical Sciences and Research, Coimbatore, Tamilnadu, India.

² Associate Professor, Department of Anatomy, Govt. Kilpauk Medical College, Kilpauk, Chennai, Tamilnadu, India.

^{*3} Assistant Professor, Department of Anatomy, Govt. Kilpauk Medical College, Kilpauk, Chennai, Tamilnadu, India.

ABSTRACT

Background: Peroneus quartus is an accessory peroneal muscle, which can be a cause of chronic lateral ankle pain in people subjected to long term high plantar flexion. An anomalous peroneus quartus can be mistaken for split tear of the peroneal tendons.

Materials and methods: The following study was conducted in 64 lower limb specimens at the Department of Anatomy. The fibular compartment muscles were analysed for an accessory peroneal muscle.

Results: Out of 64 lowerlimb specimens, there was a variation found in the fibular compartment of one male cadaver. The peroneus brevis ended shortly at the peroneal tubercle. There was an accessory peroneus quartus muscle which had an unusual course and insertion.

Conclusion: The variation observed underlies an evolutionary adaptational change in peroneus brevis and peroneus quartus muscle. The orthopedic surgeons should bear in mind the presence of peroneus quartus and its anomalous course in patients presenting with chronic lateral ankle pain.

KEY WORDS: Peroneus Quartus, Peroneus Brevis, Anomalous, Accessory, Evolution.

Address for Correspondence: Dr. Anjana TSR, Assistant Professor, Department of Anatomy, Govt Kilpauk Medical College, Kilpauk, Chennai-600010, Tamilnadu, India. **E-Mail:** tsranjana@gmail.com

Access this Article online

Quick Response code



DOI: 10.16965/ijar.2016.237

Web site: International Journal of Anatomy and Research
ISSN 2321-4287
www.ijmhr.org/ijar.htm

Received: 11 May 2016 Accepted: 07 June 2016
Peer Review: 12 May 2016 Published (O): 30 June 2016
Revised: None Published (P): 30 June 2016

INTRODUCTION

A sound knowledge of the muscles of the lateral aspect of the leg has its use in many reconstructive surgeries in the ankle. Peroneus quartus (fibularis quartus) [1] is one of the accessory peroneal muscles in the leg commonly called as peroneus accessorius. The first description of the muscle was made by Otto [2] and later a detailed study was made by Hecker

[3]. The authors found that this muscle can present as a normal variant in the lateral compartment of the leg. The incidence of the muscle was reported by Hecker to be 13%. The presence of this muscle in humans is much related to the adaptational change brought about in maintaining the erect posture due to evolution [4]. The presence of an accessory peroneal muscle adds to the stability of the ankle

joint. In a broader aspect, Peroneus quartus muscle can be defined as a muscle which takes origin from the lower or upper 1/3rd of the lateral aspect of the leg either originating from the fibula, the muscles of the peroneal compartment or interosseous membrane. It is commonly inserted on to the lateral part of the foot. The muscle may have variant insertions at retrotrochlear eminence of calcaneum, peroneal tubercle, base of the 5th metatarsal, in any one of the tendons of peroneal compartment, inferior peroneal retinaculum, phalanges of the fifth digit and cuboid bone [5-9]. The most common variant is found to extend from peroneus brevis to retrotrochlear eminence of calcaneum.

The Peroneus quartus muscle is usually mistaken for a longitudinal tear of the peroneus brevis tendon. Moreover, the muscle usually causes crowding in the retro malleolar groove leading to pain at the lateral aspect of the ankle [10,11], commonly described as the “crowding effect”. The prevalence of this muscle is found to vary from 3-21.7% [3]. It is commonly found to lie posteromedial to the peroneal tendons in the retromalleolar groove. Peroneus quartus is frequently asymptomatic but may cause tenosynovitis and attrition of peroneal tendons, pain in ankle and painful hypertrophy of retrotrochlear eminence [12-16]. Even though the muscle presents as an accessory structure in the peroneal compartment, it is commonly implicated in chronic lateral ankle pain. Hence the present study aims to identify the presence of such an accessory muscle to observe the incidence of the structure in this subset of population.

MATERIALS AND METHODS

The study was conducted in 64 lower limb specimens (32 cadavers) in the Department of Anatomy, Karpagam Institute of Medical Sciences and Research, Coimbatore, Tamilnadu, India. The morphologically damaged lower limb specimens were excluded. An incision was made from head of fibula to the lateral malleolus and then extended from there to the lateral aspect of the little toe. The superficial structures, the peroneal retinaculum were identified, and the peroneal region was examined and looked for an accessory peroneal muscle. When the peroneus quartus muscle was identified the parameters

of the accessory muscle were measured using a digital vernier caliper.

OBSERVATIONS

Fig. 1: Shows the A) Origin of peroneus quartus (PQ) from muscle belly of peroneus longus (PL), B) Insertion of peroneus quartus tendon (PQ) at the base of fifth metatarsal bone, peroneus longus tendon (PL) passing to the sole and peroneus brevis (PB) tendon getting inserted into the peroneal tubercle. The peroneus quartus tendon passes anterior to both the peroneal longus (PL) and peroneus brevis tendons (PB) tendons.

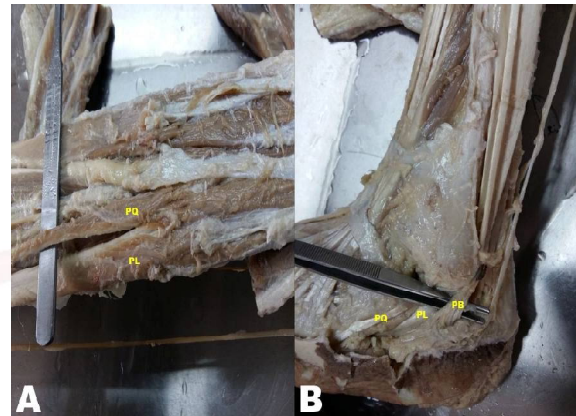


Fig. 2: Shows the measurement of A) the vertical portion of the tendon B) distal portion of the peroneus quartus tendon.

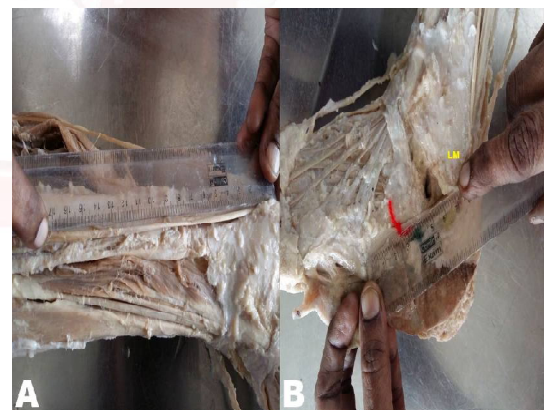


Fig. 3: Shows the width of the Peroneus quartus (PQ) tendon close to its insertion.



Out of 64 lower limb specimens from 32 cadavers dissected and examined at the Department of Anatomy, one lower limb specimen showed a marked variation in the peroneal compartment

of the leg in the left side of a 65 years old male cadaver. Interestingly, three tendons were found in the fibular compartment. The authors of the present study identified the peroneus longus and brevis tendons, then traced the course of the third tendon, which expanded into a muscular part and was found to arise from peroneus longus muscle. The distance of the origin of the muscle from the tip of the lateral malleolus and from the neck of fibula was noted and found to be 25cm and 10 cm respectively. It was also confirmed that the muscle did not arise from peroneus brevis nor was it a longitudinal tear. The insertion of the third tendon was at the base of the fifth metatarsal bone. The peroneus longus had a normal course, whereas the tendon of peroneus brevis got inserted at the peroneal tubercle, which was proximal to its usual insertion at the base of the fifth metatarsal bone.

The third tendon was identified as peroneus quartus and had a course as described below. The muscle and its tendon lay anterior to the peroneal muscles throughout its course and passed behind the lateral malleolus along with the tendons of peroneus longus and brevis. The tendon then passed undercover of peroneal retinaculum to get inserted into the base of the fifth metatarsal bone. The inferior peroneal retinaculum appeared normal. The total length of the muscle was noted as 31 cm, in that the muscle belly was measuring 6 cm in length. The tendinous part of the muscle was measured in two components. The vertical component extending from the musculotendinous junction to the tip of lateral malleolus was 17cm long and the second horizontal segment extending from the tip of the lateral malleolus to the base of fifth metatarsal bone was 8 cm long. The width of the muscle belly measured 0.93 cm. The width of the tendon was noted and found to be 0.39 cm, 0.6 cm and 0.62 cm at musculotendinous junction, lateral malleolus and at its insertion respectively. The superficial peroneal nerve passed medial to the fibers of peroneus quartus muscle and at the musculotendinous junction, the nerve pierced the deep fascia to become superficial. Then the nerve ran between the peroneus quartus muscle in front and the peroneus brevis muscle behind.

The contralateral peroneal compartment on the right side had normal anatomy consisting of only two muscles and they were identified as peroneus longus and peroneus brevis.

DISCUSSION

The presence of an accessory peroneal tendon have been described in the past based upon cadaveric dissection and intra operative data. Whenever three tendinous structures are encountered in the retromalleolar groove, the probability of the third tendon is generally confined to a longitudinal split in the peroneus brevis tendon or the presence of peroneus quartus muscle [17]. The peroneus brevis was shorter than the quartus tendon because of its proximal insertion at the peroneal tubercle. It made the authors view the change in the insertion of peroneus brevis as an adaptational change due to foot pronation owing to the presence of peroneus quartus. The foot pronation provided the much needed stability to the ankle joint in humans for bipedal gait. A noteworthy identification of peroneus quartus depends upon its location being posterior to peroneus longus and brevis tendon. On the contrary, the present study revealed an anomalous course of peroneus quartus lying anterior to the peroneus longus and brevis. This was in accordance with Sayeed Y et al, who described in detail about the anomalous peroneus quartus muscle found the tendon to be lying anterior to the other peroneal tendons in the retromalleolar groove. Sobel et al [18] described the possibility of the peoneus quartus muscle arising from peroneus longus to be 1.6%. In such cases, the insertion was limited to the retrotrochlear eminence. Out of 64 limbs examined, the authors observed the peroneus quartus variant arising from the peroneus longus muscle in one lowerlimb specimen, equating its incidence to 1.56%. Surprisingly, the authors found the insertion to extend further to the base of fifth metatarsal bone. The musculotendinous junction of the peroneus quartus muscle has a variable location [19].

In the present study, the musculotendinous junction was located 19 cm proximal to lateral malleolus. Samaras and Kingford [20] found that the presence of peroneus quartus muscle was

associated with hypertrophy of peroneal tubercle. But in our study, there was no such hypertrophy of peroneal tubercle. The width of the peroneus quartus tendon was much less than that of peroneus longus tendon close to its insertion, correlating with that of Sayeed et al study [17]. The peroneus quartus is present posterior to the peroneal tendons in majority of cases as reported in literature. But in the present study, the peroneus quartus took an anomalous anterior course giving a mind to think about evolutionary change brought about by the bipedal gait of human beings.

CONCLUSION

The peroneus quartus muscle, although an accessory muscle that causes crowding effect at the retromalleolar groove has its utility in repair of peroneal retinaculum tears. The peroneus quartus. When present, can also be used in the field of reconstructive surgery particularly in recurrent peroneal dislocations [21]. There is an increased chance of impingement of peroneal sheath by peroneus quartus muscle in people who are subjected to increased plantar flexion as in ballet dancers, gymnasts and athletes. This may result in lateral ankle pain. Hence the presence of peroneus quartus must be borne in mind by orthopaedicians in treating chronic lateral ankle pain. It is noteworthy to mention that the radiologists should be aware of an anomalous peroneus quartus muscle while viewing three peroneal tendons at the retromalleolar groove.

Conflicts of Interests: None

REFERENCES

- [1]. Sergio Ricardo Rios Nascimento, Costa rw, Ruiz ,Wafae N.analysis on the incidence of the fibularis quartus muscle using magnetic resonance imaging. *Anatomy research international*. 2012;12(6).
- [2]. Bergman RA, Afifi AK and Miyauchi R. Peroneus Quartus(Otto), *Illustrated Encyclopaedia of Human Anatomic Variation*. 2009. <http://www.anatomyatlases.org /Anatomic Variants>.
- [3]. Hecker P. Study of the peroneus on the tarsus. *Anat Rec*. 1923;26:79-82.
- [4]. Xingbo Sun, Francesca Castellucci, Tara Harrington, Erica Benson, Bryan Katz and Kevin Miller. A closer look at the recent literature on peroneus quartus. *Podiatry today*.2015.28(7).
- [5]. Zammit J, Singh D. The peroneus quartus muscle. *J Bone Joint Surg*. 2003; 85(8):1134-137.
- [6]. Trono M, Tueche S, Quintart C, Libotte M, Baillon JM. Peroneus quartus muscle: a case report and review of the literature. *Foot Ankle Int*. 1999;20(10):659-62.
- [7]. Biligili M, Kaynak G, Botanhoglu H, Basaran S, Ercin E, Baca E, Uzun I. Peroneus quartus: prevalence and clinical importance. *Arch Orthop Trauma Surg*. 2014;134(4):481-487.
- [8]. Buschmann WR, Cheung YC, Jahss MH. Magnetic resonance imaging of anomalous leg muscles: accessory soleus, peroneus quartus and ùxor digitorum longus accessorius. *Foot Ankle* 1991;12:109–116. 8. Chaney DM, Lee MS, Khan MA, Krueger WA, Mandracchia VJ, Yoho RM. Study of ten anatomic variants of the foot and ankle. *JAm Podiatr Med Assoc* 1996;86:532-537.
- [9]. Cheung YY, Rosenberg ZS, Ramsinghani R, Beltran J, Jahss MH. Peroneus quartus muscle: MR imaging features. *Radiology*. 1997;202(3):745-50.
- [10]. Ozunur A, Arik A, Alanay A. Peroneus quartus muscle as a rare cause of the chronic lateral ankle pain. *Foot Ankle Surg*. 2002;8(2):227-230.
- [11]. Sarrafian SK, Kelikian AS. Retaining systems and compartments. In: Kelikian AS (ed.) *Sarrafian's Anatomy of the Foot and Ankle, Third Edition*. Lippincott Williams & Wilkins, Philadelphia, 2011, p. 131.
- [12]. Wachter S,Beekman S.Peroneus quartus : A case report.*J Am Podiatry Assoc*. 1983;73:523-4
- [13]. Lepow GM,Korfin DH.Calcification of an accessory peroneal tendon in an athlete :A case presentation.*J Am Podiatry Assoc*. 1985;75:323-5.
- [14]. Sammarco GJ, Brainard JB. A symptomatic anomalous peroneus brevis in a high jumper. *J Bone Joint Surg*. 1991;73-A:131-3.
- [15]. White AA 3rd, Johnson D, Griswold DM. Chronic ankle pain associated with peroneus accessories. *Clin Orthop* 1974;103:53-5.
- [16]. Hammerschlag WA, Goldner JL.Chronic Peroneal Subluxation produced by an anomalous peroneus brevis: case report and literature review.*Foot ankle* 1989;10:45-7.
- [17]. Sayeed Y, Jonathan T. Finnoff, Pawlina W, Smith J. Atypical Anomalous Peroneal (Fibularis) Tendon: Potential Pitfall in Musculoskeletal Ultrasonography. *Journal of Ultrasound in Medicine*. 2011;30(5): 710-713.
- [18]. Sobel M, Levy ME, Bohne WHO. Congenital variations of the peroneus quartus muscle: An anatomic study. *Foot Ankle Int*. 1990;11(2):81-89.
- [19]. Chepuri NB, Jacobson JA, Fessell DP, Hayes CW. Sonographic appearance of the peroneus quartus muscle: correlation with MR imaging appearance in seven patients. *Radiology* 2001;218:415-419.
- [20]. Samaras D, Kingsford A. Peroneus brevis rupture associated with a hypertrophic peroneal tubercle: a case report and literature review. *J Foot Ankle Res*. 2013;6(Suppl 1):14-17.

- [21]. Mick C A, Lynch F. Reconstruction of the peroneal retinaculum using peroneus quartus: A case report. J Bone Joint surg. 1987;69-A:296-7.

How to cite this article:

Sheela Grace, Preethi Ramya T, Anjana TSR. AN ADAPTATIONAL CHANGE OF EVOLUTIONARY SIGNIFICANCE IN PERONEAL TENDONS: AN ANOMALOUS PERONEUS QUARTUS AND A PROXIMALLY MIGRATED PERONEUS BREVIS TENDON. Int J Anat Res 2016;4(2):2454-2458. DOI: 10.16965/ijar.2016.237

