

Case Report

SUPERFICIAL ULNAR ARTERY: A RARE VARIATION IN A TANZANIAN MALE CADAVER

George Joseph Lufukuja.

Lecturer, Department of Anatomy and Histology Hubert Kairuki Memorial University (HKMU).

ABSTRACT

The superficial ulnar artery is a very rare variation of the upper limb arterial system that usually arises from the brachial artery and occasionally it may arise from axillary artery and runs superficial to the muscles of the forearm that arising from the medial epicondyle. In our daily routine dissections we observed a unilateral superficial ulnar artery on the right hand side of a male cadaver of 53 years of age. The artery emerged superficially immediate below the lower margin of the bicipital aponeurosis and coursed superficial to palmaris longus and flexor carpi ulnaris making it highly vulnerable to intra-arterial injection. Knowledge of this anatomical variation is of great importance for every medical personnel.

KEY WORDS: Superficial Ulnar Artery, Ulnar Artery, Arterial Variation.

Address for Correspondence: George Joseph Lufukuja, Lecturer, Department of Anatomy and Histology Hubert Kairuki Memorial University (HKMU), P.O. Box 65300 Dar es Salaam, Tanzania (East Africa). **E-Mail:** lufukuja70@yahoo.co.uk

Access this Article online

Quick Response code



DOI: 10.16965/ijar.2016.217

Web site: International Journal of Anatomy and Research
ISSN 2321-4287
www.ijmhr.org/ijar.htm

Received: 22 Apr 2016 Accepted: 24 May 2016
Peer Review: 22 Apr 2016 Published (O): 30 June 2016
Revised: None Published (P): 30 June 2016

INTRODUCTION

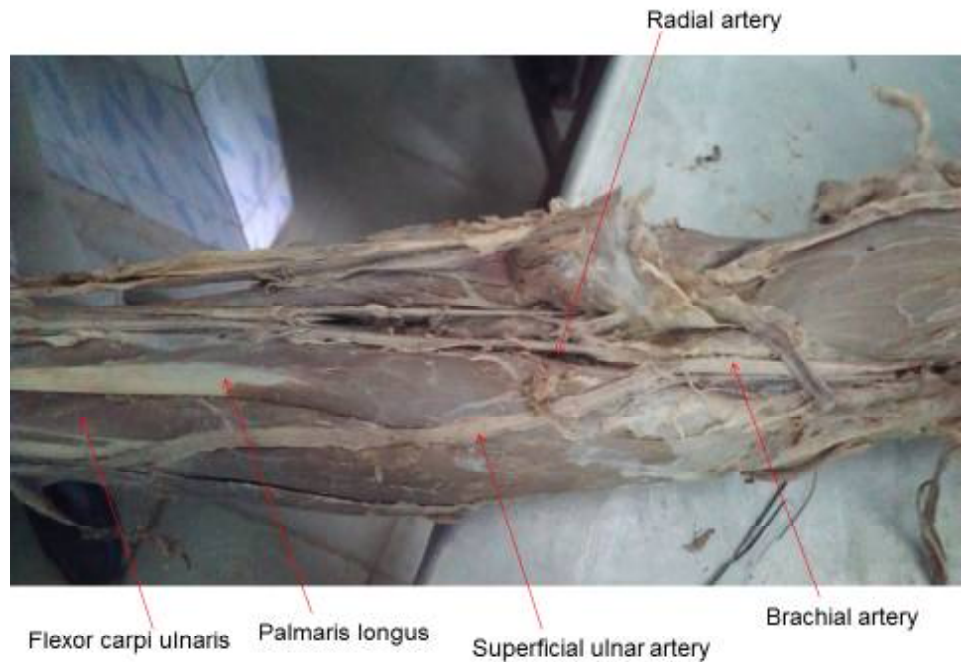
Ulnar artery is larger terminal branch of brachial artery, which arises 1cm distal to the flexion crease of the elbow and which reaches the medial side of forearm, midway between wrist and elbow. In forearm, ulnar artery lies deep to superficial flexor group of muscles and lateral to ulnar nerve [1]. The anatomical variations in the main arteries of the upper limb are common. However, superficial ulnar artery is a rarely reported anomaly with an incidence of 0.3–9.4% in the population [3,4]. The superficial ulnar artery has a lot of significant clinical implications. Its superficial position makes it more vulnerable to trauma and such a variant could easily be mistaken for a vein that it may be cannulated inadvertently by an unsuspecting physician, leading to haemorrhages and thus

ischemia of the hand. Such misinterpretation could also lead to an intra-arterial injection. Based on its clinical importance the presence of a superficial ulnar artery should not be underestimated as several cases of intraarterial injection of drugs and subsequent amputations have been reported [2].

CASE PRESENTATION

During our daily routine dissection for the medical students of the Department of Anatomy, Faculty of Medicine, at Hubert Kairuki Memorial University in Tanzania, an anomalous branch of the brachial artery was found in one cadaver. The artery was carefully traced by sectioning the bicipital aponeurosis and pronator teres. The artery was found to arise from brachial artery then emerged superficially

Fig. 1: Right upper Limb showing superficial ulnar artery originating from brachial artery.



immediate below the lower margin of the bicipital aponeurosis and coursed from the lateral to the medial side and passed superficial to palmaris longus and flexor carpi ulnaris (Figure 1). The artery formed no branches throughout its course in the forearm and it was running superficial to the deep fascia. However, the arterial pattern of the left upper limb was normal.

DISCUSSION

Based on the literature, anatomical variations of the upper limb arterial system are well documented, however, the presence of a superficial ulnar artery seems to be a very rare variation with an incidence of 0.3%–7% [3,4]. Cases of superficial ulnar artery to arise from axillary artery and occasions of it being bilaterally has been reported [5,6]. Knowledge on origin, course and distribution of ulnar artery is important, due to its clinical implications. The presence of a superficial ulnar artery may pose a risk for an unintended intra-arterial cannulation and drug administration [7].

ACKNOWLEDGEMENTS

To my Almighty God, for guiding and giving me the strength, To my parents, Joseph M. Lufukuja and Maria Petro Ng'wakami, for their love and encouragement, To my beloved wife Rachel, and Sons Joseph junior and Jonathan for their

immeasurable support throughout this case report writing, Last but not least, I thank anyone who in one way or the other contributed to the accomplishment of this case report. Any shortcomings of this work should not be attributed to any of the above mentioned individuals.

Conflicts of Interests: None

REFERENCES

- [1]. Standring Susan. Gray's Anatomy, The Anatomical basis of clinical practice. 40th edition. London: Elsevier Churchill Livingstone; 2008. pp. 852–53
- [2]. Kithsiri J S, Sujatha S, Manjula J R, Ranil F, Kosala S: A rare variant of the superficial ulnar artery, and its clinical implications. J Medical Case Reports 2007, 1:128.
- [3]. J. Dartnell, P. Sekaran and H. Ellis: The superficial ulnar artery: Incidence and calibre in 95 cadaveric specimens. Clinical Anatomy 2007;20(8):929-932 From <http://onlinelibrary.wiley.com/doi/10.1002/ca.20546/abstract?globalMessage=0>
- [4]. Fadel RA, Amonoo-Kuofi HS. The superficial ulnar artery: Development and surgical significance. Clin Anat. 1996;9:128-32.
- [5]. Yazar F, Kirici Y, Ozan H, Aldur MM. An unusual variation of the superficial ulnar artery. Surg Radio Anat. 1999;21:155-7. doi:10.1007/s00276-999-0155-1.
- [6]. Natsis K, Papadopoulou AL, Paraskevas G, Totlis T, Tsikaras P. High origin of a superficial ulnar artery arising from the axillary artery: anatomy, embryology, clinical significance and a review of the literature. Folia Morphologica-Warszawa-English Edition. 2006 Nov;65(4):400-405.

- [7]. Chin KJ, Singh K: The superficial ulnar artery a potential hazard in patients with difficult venous access. *Br. J. Anaesth.* (May 2005);94(5):692-693. Retrieved from <http://bj.oxfordjournals.org/content/94/5/692.full>

How to cite this article:

George Joseph Lufukuja. SUPERFICIAL ULNAR ARTERY: A RARE VARIATION IN A TANZANIAN MALE CADAVER. *Int J Anat Res* 2016;4(2):2409-2411. **DOI:** 10.16965/ijar.2016.217

