

A STUDY OF THE LENGTH OF POPLITEAL ARTERY IN CADAVERS

Anjali Telang ^{*1}, Mangesh Lone ², M. Natarajan ³.

^{*1} Assistant Professor, Department of Anatomy, Seth GS Medical College, Mumbai, Maharashtra, India.

² Assistant Professor, Department of Anatomy, LTMMC, Sion, Mumbai, Maharashtra, India.

³ Professor, Department of Anatomy, Seth GS Medical College, Mumbai, Maharashtra, India.

ABSTRACT

Background: Femoral artery continues as popliteal artery at the adductor hiatus. Popliteal artery terminates by dividing into anterior tibial and posterior tibial arteries. Popliteal artery is one of the commonest sites for peripheral aneurysms, entrapment syndrome, atherosclerosis and vascular injuries due to proximity to knee joint. Complete anatomical knowledge of popliteal artery is required for any surgical procedure which involves elective or emergency exposure of popliteal artery. The aim of the study was to measure the length of popliteal artery from origin to its termination, from origin to distal edge of femoral condyles and from distal edge of femoral condyles to its termination.

Materials and Methods: Fifty cadavers (100 lower limbs) embalmed with 10% formalin were utilized in this study.

Results: The mean length of popliteal artery from apex of adductor hiatus to its termination on the right side was 208.7mm \pm 19.44 and on the left side, it was 208.8 mm \pm 20.30. The mean length of popliteal artery from apex of adductor hiatus to distal edge of femoral condyles on the right side was 149.7 mm \pm 18.93 and on the left side, it was 149.2 mm \pm 21.52 whereas, that of distal edge of femoral condyles to its termination on the right side was 59.2 mm \pm 13.12 and on the left side, it was 60.6 mm \pm 15.26.

Conclusion: The metric data related to length of popliteal artery from its origin to termination from the present study will be helpful for vascular surgeons & radiologists.

KEY WORDS: Popliteal Artery, Adductor Hiatus, Femoral Condyles, Vascular Surgeons.

Address for Correspondence: Dr. Anjali Vishwanath Telang, Department of Anatomy, Second floor, Seth GS Medical College and K.E.M. Hospital, Parel, Mumbai-400012, Maharashtra, India.

E-Mail: dranatelang@gmail.com

Access this Article online

Quick Response code



DOI: 10.16965/ijar.2016.196

Web site: International Journal of Anatomy and Research
ISSN 2321-4287
www.ijmhr.org/ijar.htm

Received: 06 Apr 2016 Accepted: 09 May 2016
Peer Review: 07 Apr 2016 Published (O): 31 May 2016
Revised: None Published (P): 31 May 2016

INTRODUCTION

Popliteal artery is continuation of femoral artery at the adductor hiatus and terminates at the lower border of the popliteus muscle by dividing into anterior tibial and posterior tibial arteries [1,2]. Surgeries performed in the area of popliteal fossa are for lesions of popliteal artery (peripheral vascular disease, aneurysms,

thrombotic, neoplastic, inflammatory, and traumatic), lesions of knee joint (dislocation, fracture of articulating surfaces), arthroscopic procedures of knee joint, ligament repair or reconstruction around the posteromedial or posterolateral aspect of the knee, meniscal repair, posterior cruciate ligament tibial inlay reconstruction, and Baker's cyst excision. The

popliteal artery is a common recipient site for above or below knee bypass grafts. It is also frequently affected by penetrating and blunt trauma involving the lower extremity. Exposure of this artery is, therefore, often required in both emergent and elective vascular procedures. An understanding of the normal anatomy of popliteal artery is essential in the surgical management of vascular injuries in the popliteal fossa as well as for surgical and endoscopic repair of popliteal aneurysm or femoro-popliteal bypass grafts [3].

Review of literature on popliteal artery showed that there are very few studies on the length of the popliteal artery. This study was undertaken to measure the length of the popliteal artery from the apex of adductor hiatus to its termination the length of the popliteal artery from the apex of adductor hiatus to the distal edge of femoral condyles & the length of the popliteal artery from the distal edge of femoral condyles to its termination.

MATERIALS AND METHODS

Hundred lower limbs (50 cadavers) embalmed with 10% formalin were utilised in this study. Cadavers were obtained from medical college located in Western Maharashtra, India. All the cadavers were adult males ranging between the age group of 18-65 years. None of the limbs showed any evidence of previous surgery. After taking incision, skin was reflected followed by removal of superficial fascia and deep fascia to expose the popliteal fossa. Hamstring muscles were reflected to expose the origin of popliteal artery and two heads of gastrocnemius were reflected to expose the popliteal vessels. Soleus muscle was dissected vertically up to the termination of popliteal artery. The adductor hiatus and termination of popliteal artery were exposed. The length of popliteal artery was measured to the nearest millimetre with the help of a thread and scale calibrated in millimetres. A sufficient period of 'trial and error' preceded actual systematic record of measurements. Such checks and rechecks were carried out in 5 cadavers (Not included in the final data).

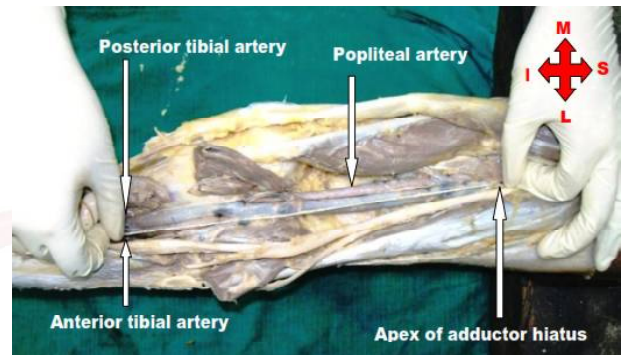
Parameters measured were

- The length of popliteal artery from apex of adductor hiatus to its termination (Fig.1)

- The length of popliteal artery from apex of adductor hiatus to distal edge of femoral condyles
- The length of popliteal artery from distal edge of femoral condyle to its termination

The data was statistically analysed for the purpose of comparison and correlation and for calculating range, mean & standard deviation.

Fig. 1: Illustration showing the measurement of the length of popliteal artery from the apex of the adductor hiatus to its termination.



RESULTS

The mean length of popliteal artery from apex of adductor hiatus to its termination on the right side was 208.7mm and 208.8 mm on the left side. (Table 1)

The mean length of popliteal artery from apex of adductor hiatus to the distal edge of femoral condyles was 149.7 mm on the right side and 149.2 mm on the left side. (Table 2)

Whereas, the mean length of popliteal artery from distal edge of femoral condyles to its termination was 59.2 mm on the right side and 60.6 mm on the left side. (Table 3)

Table 1: The mean length of popliteal artery from apex of adductor hiatus to its termination.

Number	Side	Range (in mm)	Mean (in mm)	Standard Deviation
50	Right	175-247	208.7	19.44
50	Left	170-245	208.8	20.3

Table 2: The mean length of popliteal artery from apex of adductor hiatus to distal edge of femoral condyles.

Number	Side	Range (in mm)	Mean (in mm)	Standard Deviation
50	Right	110-180	149.7	18.93
50	Left	100-184	149.2	21.52

Table 3: The mean length of popliteal artery from distal edge of femoral condyles to its termination.

Number	Side	Range (in mm)	Mean (in mm)	Standard Deviation
50	Right	25-85	59.2	13.12
50	Left	35-105	60.6	15.26

DISCUSSION

Apart from popliteal artery aneurysm, popliteal artery entrapment syndrome & atherosclerosis, popliteal artery injury is well documented complication of trauma to the knee. The popliteal artery is relatively immobile as it is tethered between the adductor hiatus and the soleus arch, which increases its susceptibility to injury during trauma [4].

The knee joint is most frequently examined by arthroscopy. To maximize surgical access for visualization and for surgical instruments & to avoid damage to structures such as nerves and blood vessels, the placement of portals for arthroscopy is critical. The standard portals are anterior [5].

There are few cadaveric studies on popliteal artery which studied its length from origin to its termination. The findings of the present study were similar to that Zuhail et al. in their study of forty lower limbs obtained from nineteen male and one female cadaver had measured the length of popliteal artery from various anatomical landmarks. They found the length of the popliteal artery from the adductor hiatus to the origin of the anterior tibial artery was 191.1 ± 34.7 mm, from adductor hiatus to femur condyles was 138.1 ± 23.8 mm [6]. Kim et al. in their study on 605 extremities, performed femoral angiograms and analysed the branching pattern of the popliteal artery [7].

Cagatay Barut et al. dissected 28 popliteal fossae (12 right and 16 left) of fixed lower extremities and measured the arterial length by using a digital caliper. The transverse plane between the distal edges of the femoral condyles (FCs) was used as reference. The mean length of the popliteal artery (PA) from the adductor hiatus (AH) to the FCs was measured $92.6 \text{ mm} \pm 16.3$ (9.26 ± 1.63 cm) on the right side and $100.8 \text{ mm} \pm 21.2$ (10.08 ± 2.12 cm) on

the left side, while the mean distance from the FCs to the site of bifurcation into the anterior and posterior tibial arteries was $72 \text{ mm} \pm 19.8$ (7.20 ± 1.98 cm) on the right side and $66.9 \text{ mm} \pm 11.5$ (6.69 ± 1.15 cm) on the left [8].

CONCLUSION

This data of popliteal artery from present study will be helpful for exposure of popliteal artery and for avoiding complications during surgeries on popliteal artery. It will help the endovascular surgeons and interventional radiologists during the surgeries or interventions for popliteal artery lesions.

ABBREVIATIONS

PA- Popliteal artery

AH- Adductor hiatus

FCs- Femoral condyles

ACKNOWLEDGEMENTS

Dr. Pritha Bhuiyan, Professor & Head, Department of Anatomy, Seth GS Medical College, Mumbai for her kind support and encouragement.

Conflicts of Interests: None

REFERENCES

- [1]. Richard LM Newell. Pelvic Girdle and Lower Limb (knee). In Gray's Anatomy: The Anatomical Basis of Clinical Practice. Edited by Standring S. 39th edition. Edinburgh: Elsevier Churchill Livingstone, printed in Spain, 2005; p 1471, 1486-1487.
- [2]. Datta AK. Essentials of Human Anatomy (Superior and inferior extremities) Part III. 3rd edition. Kolkata. Current Books International. 2007; p 195-197.
- [3]. Antonello M, Frigatti P, Battocchio P, et.al. Open Repair Versus Endovascular Treatment For Asymptomatic Popliteal Artery Aneurysm: Results Of A Prospective Randomised Study. J Vasc Surg. 2005; 42 (2): 185-193.
- [4]. Venu Akuthota, Stanley AH. Vascular Injuries in the Lower Limb of Athletes. In: Nerve and Vascular Injuries In Sports Medicine. 2009, published by Springer-Dordrecht Heidelberg, London, New York. p 185.
- [5]. Andrew Williams, Richard LM Newell (Pelvic girdle and lower limb). In Gray's Anatomy: The Anatomical Basis of Clinical Practice. Edited by Standring S. 39th edition. Edinburgh: Elsevier Churchill Livingstone, 2005, p 1417-1418.

- [6]. Zuhail Ozgur, Hulya Ucerler, Z Asli Aktan Ikiz. Branching Patterns of the Popliteal Artery And Its Clinical Importance. *Surg Radiol Anat* 2009; 31: 357- 362.
- [7]. Kim D, Orron DE, Skillman JJ. Surgical Significance of the Popliteal Artery Variants. A Unified Angiographic Classification. *Ann Surg* 1989; 210; 776-781.
- [8]. CagatayBarut, Oezdemir Sevinc, Hilmi Ozden, Alaittin Elhan. Surgical Anatomy and Bifurcation Patterns of the Popliteal Artery: An Anatomical Study. *Journal of Medical Sciences* April 2009; 29 (2): 338-343.

How to cite this article:

Anjali Telang, Mangesh Lone, M. Natarajan. A STUDY OF THE LENGTH OF POPLITEAL ARTERY IN CADAVERS. *Int J Anat Res* 2016;4(2):2281-2284. DOI: 10.16965/ijar.2016.196