International Journal of Anatomy and Research,
Int J Anat Res 2016, Vol 4(2):2192-95. ISSN 2321-4287
DOI: http://dx.doi.org/10.16965/ijar.2016.174

Original Research Article

# BRANCHING PATTERN OF RIGHT PORTAL VEIN: A CADAVERIC STUDY

**Lovesh Shukla *[1], Samridhi Puri [2].**

*[1] Senior Professor and Head, Department of Anatomy, Maharaja Agrasen Medical College, Agroha, Haryana 125047, India.

[2] Post Graduate Student, Department of Anatomy, Maharaja Agrasen Medical College, Agroha, Haryana 125047, India.

## ABSTRACT

**Introduction**: Knowledge of the ramification pattern of the right branch of portal vein is important in right lobectomy and right lobe liver transplant.

**Aims and objectives:** To find the ramification pattern of right branch of portal vein.

**Material and Methods:** The study was conducted on 30 formalin fixed liver obtained from adult cadavers from the dissection hall of Department of Anatomy. Right branch of portal vein was exposed by blunt dissection using ''finger fracture technique'' of liver parenchyma along the Cantlie's plane up to sub-segmental branches.

**Results and conclusion:** The right branch of portal vein was found to be absent in 23.33% (7 specimens), bifurcated in 33.33% (10 specimens), trifurcated in 40% (12 specimens) and divided into four branches in 3.33% (1 specimen).

**KEY WORDS:** Right branch of portal vein, Ramification pattern, Finger fracture technique, Cantlie's plane.

**Address for Correspondence:** Prof. Dr. Lovesh Shukla, Senior Professor and Head, Department of Anatomy, Maharaja Agrasen Medical College, Agroha, Haryana 125047, India.
**E-Mail:** drlovesh@gmail.com

**Access this Article online**

| Quick Response code | Web site: International Journal of Anatomy and Research<br>ISSN 2321-4287<br>www.ijmhr.org/ijar.htm |
|---|---|
| DOI: 10.16965/ijar.2016.174 | Received: 11 Mar 2016 Accepted: 04 Apr 2016<br>Peer Review: 12 Mar 2016 Published (O): 30 Apr 2016<br>Revised: None Published (P): 30 Apr 2016 |

## INTRODUCTION

Portal vein (PV) after its formation behind the neck of pancreas by union of superior mesenteric vein and splenic vein ascends obliquely to the right to reach porta hepatis where it divides into right portal vein (RPV) and left portal vein (LPV) before entering into liver parenchyma. After giving a branch to the caudate lobe near its origin, right branch of portal vein runs to the right lobe and bifurcates into right anterior (RA) and right posterior (RP) segmental branches as soon as it enters the hepatic parenchyma. RA divides into right anterosuperior subsegmental vein (RAS) and right anteroinferior subsegmental vein (RAI) to supply segment VIII and segment V respectively. RP divides into right posterosuperior subsegmental vein (RPS) and right posteroinferior subsegmental vein (RPI) to supply segment VII and segment VI respectively [1].

**Aims and Objectives:** As the number and branching pattern of these vessels are variable which make it necessary to map out these vessels preoperatively with Portal Venography, Computerized Tomography (CT scan) or Magnetic Resonance Imaging (MRI) for a successful and less morbid surgeries like liver transplantation,

hepatic resection [2, 3] that is why the present study was undertaken on the cadavers with the aim to find ramification pattern of right branch of portal vein.

## MATERIALS AND METHODS

The present study was conducted on 30 livers obtained from the formalin fixed cadavers of the dissecting room of the department of anatomy, Maharaja Agrasen Medical College, Agroha. Liver with any injury/ incision mark on abdominal wall were excluded from the study. Abdomen was opened and dissected. Peritoneal attachments of liver were incised. Portal vein proximal to its branching, hepatic artery at porta hepatis, and inferior vena cava proximal and distal to liver were incised and liver was mobilized from its location [4]. Liver were numbered by passing a cotton thread through inferior vena cava. Connective tissue and lymph nodes, at porta hepatis, were removed by using the blunt end of knife. Further branches of right portal vein were exposed by blunt dissection of liver parenchyma by ''finger fracture technique'' [3] along Cantlie's plane [5]. The big crushed pieces of liver parenchyma were picked by blunt forceps and liver was washed with formal saline to remove smaller pieces of parenchyma to expose vessels clearly.

## OBSERVATIONS AND RESULTS

In 76.67% specimens, RPV was dividing into two, three or four branches while in remainder (23.33%) it was absent.

I. RPV was bifurcating in 33.33% of specimens. Two bifurcation patterns were observed; one where RPV was dividing into a RA and a RP while in other, it was dividing directly into RPS and a RPI subsegmental vein. In the later pattern RA and RP segmental veins were absent. [Fig 1a-b and 2A]

II. RPV was trifurcating in 40% of specimens where two branching patterns were observed:

(a) RPV was dividing into a RA, RPS and RPI in 36.67% cases. Right posterior segmental vein (RP) was absent in this pattern. [Fig 1c, 2B(i)]

(b) RPV was dividing into a RP, RAS and RAI in 3.33%. Right anterior segmental vein (RA) was absent in this pattern. [Fig 1d, 2B(ii)]

III. RPV was found to be quadrifurcating in 1specimen (3.33%) where it was dividing directly into four subsegmental branches - RAS, RAI, RPS and RPI. Right anterior and posterior segmental veins were absent in that case. [Fig 1e, 2C]

In 23.33% of specimens RPV was absent. In these cases segmental or subsegmental branches were arising directly from the main trunk of portal vein. In 3 specimens (10%) RA and RP arose from PV while in 4 specimens (13.33%) RA, RPS and RPI arose from PV. [Fig 1f-g and 2D]

**Fig. 1:** Showing flowchart of different patterns of ramification of right branch of portal vein:
a) RPV dividing into RA and RP; b) RPV dividing into RPS and RPI; c) RPV trifurcating into RA, RPS and RPI; d) RPV trifurcating into RP, RAS and RAI; e) Quadrifurcation of RPV; f) RPV absent- PV dividing into LPV, RA and RP; g) RPV absent- PV dividing into RPS, RPI, RA and LPV.

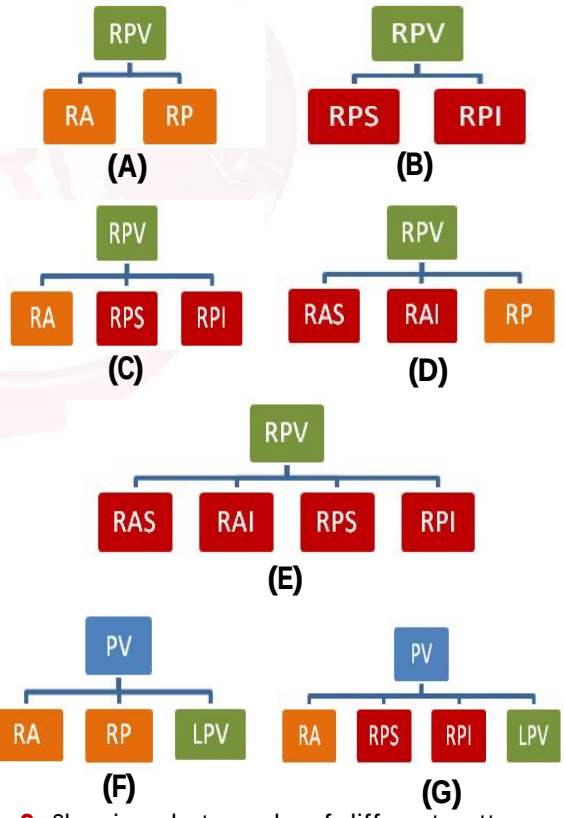


**Fig. 2:** Showing photographs of different patterns of ramification of right branch of portal vein.

A. Bifurcation of RPV

i. RPV dividing into RA and RP

ii. RPV dividing into RPS and RPI

B. Trifurcation of RPV

i. RPV trifurcating into RA, RPS and RPI

ii. RPV trifurcating into RP, RAS and RAI

C. Quadrifurcation of RPV


D. RPV absent

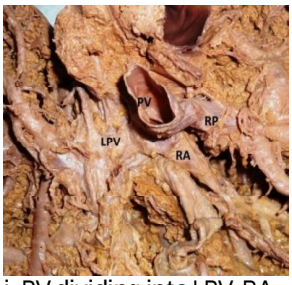


i. PV dividing into LPV, RA and RP

ii. PV dividing into RPS, RPI, RA and LPV

## DISCUSSION

**Table 1:** Showing % of Pattern of Right Branch of Portal Vein.

| Study | No. of cases (n) | No RPV (%) | Bifurcation (%) | Trifurcation (%) | Quadrifurcation (%) |
|---|---|---|---|---|---|
| Leeuwen et al (1994) [6] | 26 | 30.70% | 50% | | |
| Cheng et al (1996) [7] | 688 | 0.29% | | | |
| Arora et al (2003) [8] | 15 | | 100% | | |
| Atasoy et al (2005) [9] | 200 | | 83.20% | 12.20% | 0.80% |
| Koc Z et al (2007) [10] | 1384 | | 96.10% | 0.00% | |
| Rajput et al (2014) [11] | 25 | | 87% | 13% | |
| **Present study** | **30** | **23.33%** | **33.33%** | **40%** | **3.33%** |

RPV is variably being described to be absent in 0.29% to 30.7% cases (Table 1) as compared to our study where it is absent in 23.33% which is close to the finding of Leeuwen et al [6].

Bifurcation, trifurcation and quadrifurcation pattern of RPV is being described with range of 50% to 100%, 0.0029% to 13% and 0 to 0.8% respectively as compared to our findings of 33.33%, 40% and 3.33% respectively. After a thorough search of literature bifurcation pattern was found to be lowest; and trifurcation and quadrifurcation patterns were 3-4 times more common in the present study [6-11]. (Table 1)

RPV bifurcates into RA and RP branches in all studies and in 30% cases of the present study. Additionally, RPV was bifurcating into RPS and RPI in 3.33% of this study. After a thorough search of literature no matching results were found.

Atasoy et al [9] described trifurcation of RPV into RA, RPS and RPI while Rajput et al [11] and Gupta et al [12] described it dividing into RP, RAS and RAI. In the present study both patterns were present in 36.67% and 3.33% of liver respectively.

In 3.33% of cases RPV divided into four branches: RAS, RAI, RPS and RPI in the present study and in the study done by Atasoy et al [9] where it was present in 0.8% of cases.

## CONCLUSION

We observed that the conventional bifurcation pattern of RPV is now changing to trifurcation pattern in more cases. We conclude that ready reference to the knowledge of architecture and variation in branching pattern of portal vein will help the surgeons to plan the operative procedure in conservative manner with less complications.

## ABBREVIATIONS

**PV -** Portal Vein
**RPV -** Right branch of Portal Vein
**LPV -** Left branch of Portal Vein
**RA -** Right Anterior Segmental Vein
**RP -** Right Posterior Segmental Vein
**RAS -** Right Anterosuperior Subsegmental Vein
**RAI -** Right Anteroinferior Subsegmental Vein
**RPS -** Right Posterosuperior Subsegmental Vein
**RPI -** Right Posteroinferior Subsegmental Vein

## Conflicts of Interests: None

## REFERENCES


[1]. Stranding S. Gray's Anatomy- The Anatomical Basis of Clinical Practice. 40th ed. Edinburgh: Churchill Livingstone; 2008. p. 1166-72.

[2]. Soyer P, Blemke DA, Choti MA, Fishman EK. Variation in the Intrahepatic Portion of the Hepatic and Portal Veins. AJR Am J Roentgenol, 1995; 164(1):103-8.

[3]. More AB. Study of Vascular Segments of Liver in Dissected Cadaveric Liver Specimen. Int J Bioassay, 2013; 2(10):1349-53.

[4]. Romanes GJ. Cunningham's Manual of Practical Anatomy. 15th ed. Vol. 2. New York: Oxford University Press; 2008.

[5]. Rutkauskas R, Gedrimas V, Pundzius J, Barauskas G, Baseviėius A. Clinical and anatomical basis for classification of the structural parts of liver. Medicinia (Kaunas), 2006; 42(2):98-106.

[6]. Van leeuwen MS, Noordzij J, Fernandez MA, Hennipman A, Feldberg MAM, Dillon EA. Portal venous and segmental anatomy of the right hemiliver: Observational based on three-dimensional spiral CT renderings. AJR Am J Roentgenol. 1994 Dec; 163(6):1395-1404.

[7]. Cheng Y.F, Haung T.L, LeeT.Y, Chen T.Y, Chen C.L. Variation of the intrahepatic portal vein; angiographic demonstration and application in living-related hepatic transplant. Transplant Proc. 1996 Jun; 28(3):1667-8.

[8]. Arora J, Kapur V, Kakkar A, Dixit PC. Ramification pattern of portal vein in right lobe of liver- A corrosion cast study. J Anat Soc India. 2003 Jun; 52(1):12-4.

[9]. Atasoy C, Ozyurek E. Prevalence and types of main and right portal vein branching variations on MDCT. AJR Am J Roentgenol. 2006 Sep; 187(1):676-81.

[10]. Koc Z, Oguzkurt L, Ulusan S. Portal vein variations: clinical implications frequencies in routine abdominal multidetector CT. Diagn Interv Radiol. 2007 Jun; 13(2):75-80.

[11]. Rajput AS, Kumari S, Mishra GP. A corrosion cast study of ramification pattern of portal vein in right lobe of human liver. Int J Anat Res. 2014; 2(4):791-6.

[12]. Gupta SC, Gupta CD, Arora AK. Subsegmentation of the human liver. J Anat,1977; 124(2):413-23.



**How to cite this article**:

Lovesh Shukla, Samridhi Puri. BRANCHING PATTERN OF RIGHT PORTAL VEIN: A CADAVERIC STUDY. Int J Anat Res 2016;4(2):2192-2195. **DOI:** 10.16965/ijar.2016.174