

LIMB DEFECTS: A SPECTRUM OF CORRELATED STUDY

M. Yesender ^{*1}, Asra Anjum ², S. Saritha ³, B. Sadananda Rao ⁴, T.V. Ramani ⁵, Peter Ericson ⁶.

^{*1} Associate professor, Department of Anatomy, KAMSRC, Hyderabad, Telangana, India.

² Lecturer, Department of Anatomy, KAMSRC, Hyderabad, Telangana, India.

³ Professor & HOD, Department of Anatomy, KAMSRC, Hyderabad, Telangana, India.

⁴ Associate professor, Department of Anatomy, KAMSRC, Hyderabad, Telangana, India.

⁵ Assistant professor, Department of Anatomy, KAMSRC, Hyderabad, Telangana, India.

⁶ Assistant professor, Department of Anatomy, KAMSRC, Hyderabad, Telangana, India.

ABSTRACT

Introduction: Congenital limb defects are rare fetal anomalies which occur in approximately 6 per 10,000 live births with 3.6 per 10,000 affecting the upperlimbs and 1.1 per 10,000 affecting the lower limbs. These defects are often associated with craniofacial, cardiac and genitourinary systems. The limb defects may be represented as partial absence of one or more extremity is Meromelia, where in complete absence of one or more extremities is Amelia and rudimentary hands and feet are attached to trunk with long bones absent is Phocomelia. The limb defects may be longitudinal deficiencies like absence of radius or ulna and transverse deficiencies like Phocomelia. The Major causes of limb malformations are genetic programming and intra-uterine disruption to development.

Aim: The present work aims to provide the concise summary of common congenital limb anomalies on the basis of morphology, etiology and genetics.

Materials and Methods: The retrospective study includes 200 fetuses from the department of Obstetrics and Gynecology, and live adults from the OPD of Gandhi Medical College and Hospital, Secunderabad, for a period of two years.

Conclusion: This paper illustrates the study of complex limb defects adopted in the human series. The intimate knowledge of the genes and environmental factors govern the limb pattern formation in humans and will elucidate the interactions underlying the normal and pathological development.

KEY WORDS: Limb defects, Amelia, Phocomelia, Meromelia, Lobster claw hand.

Address for Correspondence: Dr. M. Yesender, Associate professor, Department of Anatomy, KAMSRC, Hyderabad, Telangana, India. **E-Mail:** matteda.yesender@gmail.com

Access this Article online

Quick Response code



DOI: 10.16965/ijar.2015.340

Web site: International Journal of Anatomy and Research
ISSN 2321-4287
www.ijmhr.org/ijar.htm

Received: 14 Dec 2015

Peer Review: 14 Dec 2015

Revised: None

Accepted: 06 Jan 2016

Published (O): 31 Jan 2016

Published (P): 31 Jan 2016

INTRODUCTION

The limbs, including the shoulder and pelvic girdles comprise the appendicular skeleton. At the end of the fourth week of development, limb buds become visible as outpocketings from the ventrolateral body wall. The forelimbs appears

first followed by hind limbs 1 to 2 days later. The limb buds consist of mesenchymal core covered by a layer of cuboidal ectoderm. Ectoderm at the distal border of the limb thickens and forms the Apical Ectodermal Ridge (AER). This ridge exerts an inductive influence

in the development of the limb which proceeds proximodistally [1].

The study of limb malformation has much to contribute both to human health and to developmental biology. Several recent reports indicate that administration of thalidomide in early pregnancy may be followed by malformed child with reduction deformities of the limbs which is more common with bilateral deformities as compared with unilateral deformities of the limbs. The Number of other malformations has been described in association with reduction deformities of the limbs during the recent years [2].

There are numerous systems for classification of limb anomalies on the basis of embryology and Teratology sequencing. Embryological classification defines the defect according to the malformation during limb development. Teratological sequencing grades congenital anomalies according to the severity of expression [3,4].

The present communication of this article is to high-light various types of congenital limb anomalies that require referral systemic evaluation with review of literature.

MATERIALS AND METHODS

Limb defects were studied under 2 groups: fetuses and alive child and adults.

200 Fetuses were studied which were collected from the department of Obstetrics and Gynecology, Gandhi Medical College and Hospital. Alive child and adults were 5 in number from the OPD of Gandhi Medical College and Hospital. Institutional ethical committee clearance was obtained. The fetuses were fixed in 10% formalin. Congenital limb malformations in both the groups for gross reduction defects of both upper and lower limbs were observed in detail. Internal examination was also done in fetuses only. The data were recorded in both the groups, documented and photographed, after getting informed consent from all the subjects.

OBSERVATIONS

The 7 fetuses, 5 adults and 1 child were observed for gross limb defects and internal dissection was done only in fetuses. The total limb defects

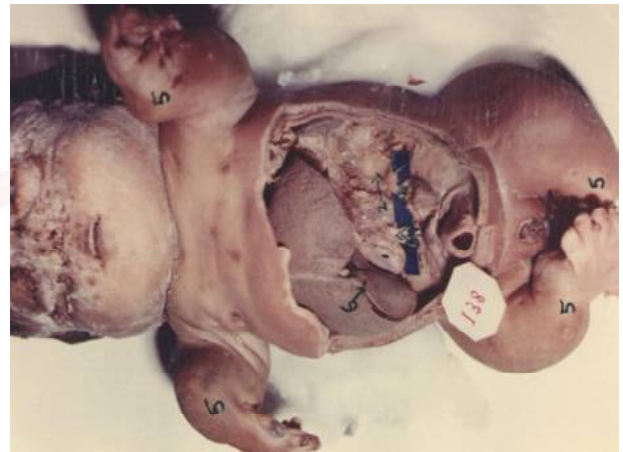studied were 13 in number.

The morphological types and variations studied and recorded were:

Foetus:

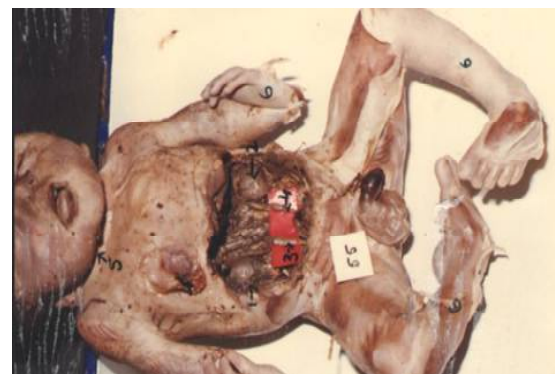Phocomelia: Female fetus of 28-32 weeks with **Phocomelia**, rudimentary hands and feet attached to the trunk and webbed neck. Internal dissection of abdomen was done and it showed bilateral renal hyperplasia and short ureters with agenesis of GallBladder (Fig. 1).

Fig. 1: Female fetus with phocomelia, rudimentary hands and feet were attached to the trunk.



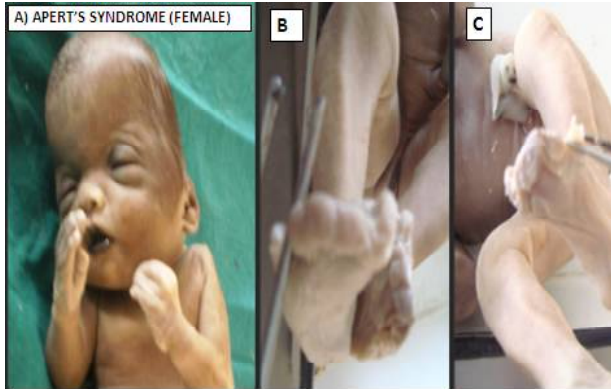
Meromelia: Male fetus of 28 – 32 weeks - upper limbs with meromelia, hands attached to the partially developed forearms. The lower limbs were normal with inverted feet (talipes equinovarus). Internal dissection of abdominal organs was normal (Fig. 2).

Fig. 2: Male fetus: Upper Limbs with meromelia, hands attached to the partially development forearms. Normal lower limbs with inverted feet (Talipes equinovarus).



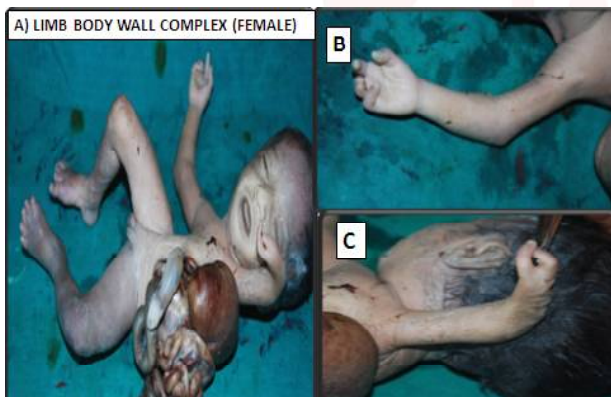
Apert's syndrome: Female fetus of 30 – 32 weeks with asymmetrical skull. Hands had syndactyly of 2nd, 3rd, 4th and 5th digits. Feet had syndactyly of 2nd, 3rd and 4th toes. Detailed internal autopsy was done. Not associated with any anomalies (Fig. 3).

Fig. 3: A. Hands: Syndactyly of 2nd, 3rd, 4th and 5th digits. B. and C. Feet: Syndactyly of 2nd, 3rd and 4th toes.



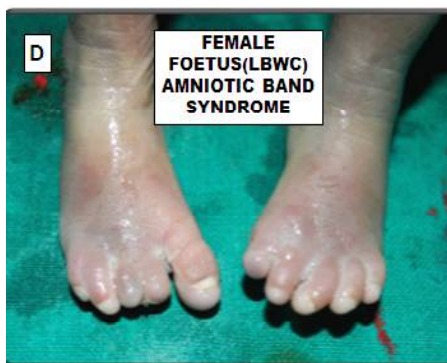Limb Body Wall Complex: Female fetus of 28-30 weeks of gestational age with ventral body wall defect associated with Omphalocele. Right hand showed syndactyly of 3rd and 4th fingers. Left forearm was absent and hand with 2 digits attached to the arm (Meromelia) (Fig. 4).

Fig. 4: A: Limb, Body wall complex (Female)
 B: Right hands: Syndactyly of 3rd and 4th fingers.
 C: Left Upper Limb: absent forearm and hand with 2 digits attached to arm (Meromelia)



Lower limbs: Amniotic band syndrome: Right foot syndactyly of 4th & 5th toes and 2nd & 3rd toes with amputation of terminal Phalanx. Left foot amputation of terminal phalanx of great toe & inversion of 3rd & 4th toes (Fig. 4 D).

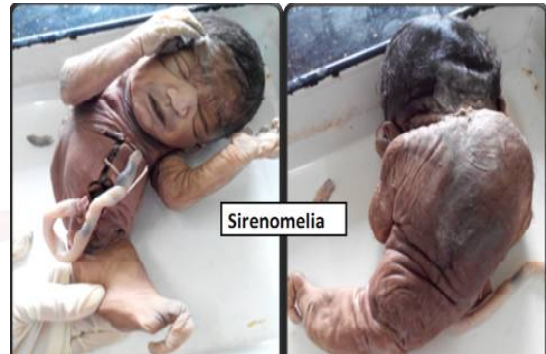Fig. 4D: Right foot syndactyly of 4th and 5th toes and 2nd and 3rd toes with amputation of terminal phalanx., Left foot amputation of terminal phalanx of great toe and inversion of 3rd and 4th toes.



Sirenomelia (due to vascular disruption) :

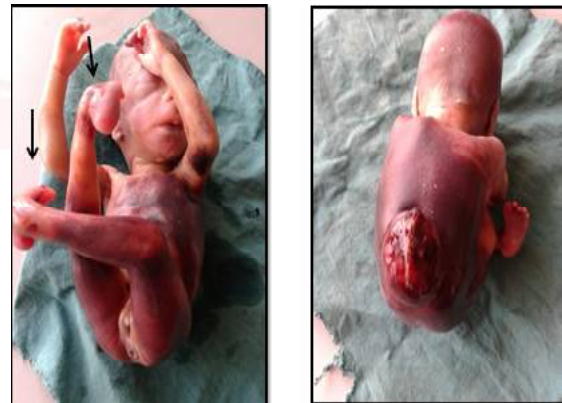Fetus of 20 – 22 weeks of gestation with single umbilical artery, fused lower limbs having one femur, one tibia, no fibula, no tarsal bones, only with one metatarsal and one toe(inverted). Absence of external genitalia and imperfect anus. Internal features presents hypoplasia of lungs with no fissures, agenesis of kidney and urinary bladder and single gonad (Fig. 5).

Fig. 5: Lower limbs fused with one femur, one tibia, no fibulae, no tarsal bones, only with on metatarsal and one toe (inverted).



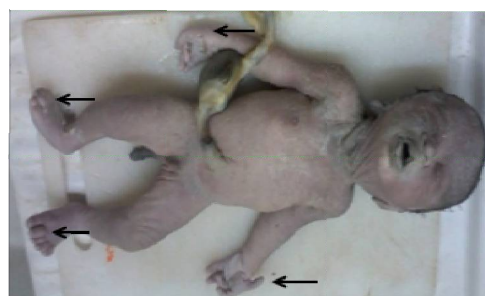Female Fetus 18-20 weeks of gestation with Arnold Chairii syndrome type II associated with Spina bifida and club feet (Fig. 6).

Fig. 6: Arnold chiarii Syndrome type-II with spina bifida and clubfeet.

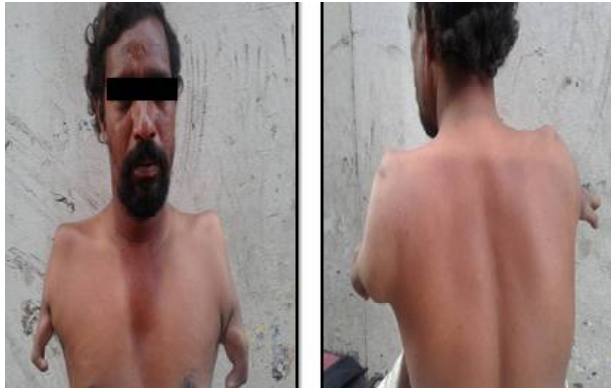

Fetus with omphalocele. right thumb absent, left thumb hyperextended, bilateral macrodactyly (digital Gigantism) of second toe (Fig. 7).

Fig 7: Fetus with omphaloccele right thumb absent, left thumb hyper extended, bilaterally macrodactyly (digital gigantism) of second toe.

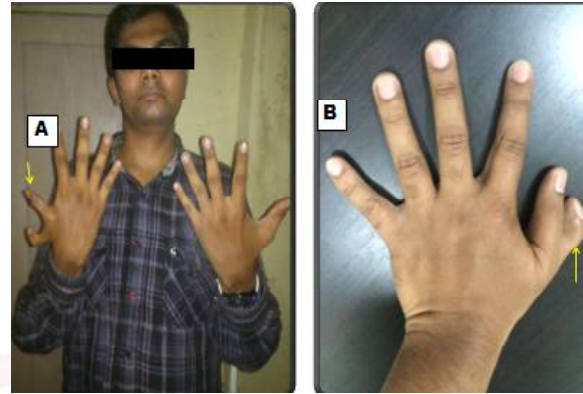

Alive Adults: Adult male of 35years old, with upper limbs Phocomelia, rudimentary hands with two fingers attached to the trunk. The Lower limbs were normal (Fig. 8).



Adult male 24yrs old: Post axial polydactyly of right handwith duplication of the right thumbwith a wide web space. Extra digit is present on the ulnar side of the right thumb with lack of function (Fig. 11).

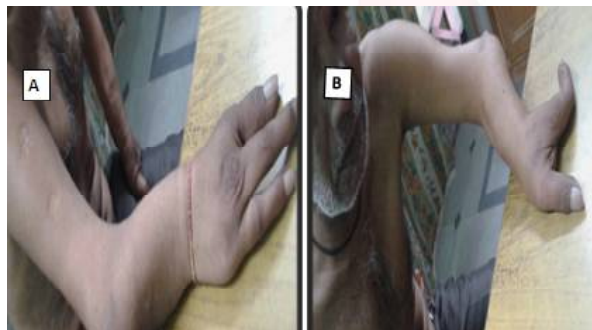Fig. 11: A. Adult male 24 yrs old with post axial polydactyl of right hand.
B.Preaxial polydactyl on left hand.



Adult male of 45years old, split hand syndrome
A) Right upper limb: arm is formed, with short forearm and hand with three digits, absence of index and ring finger
B) left upper limb: arm is formed, partially formed forearm with lobster claw hand (Fig. 9).

Fig. 9A: Adult male split hand syndrome.

A. Right upper limb: arm is not formed, short forearm and hand with three digits.
B. Left upper limb: arm is formed, partially formed forearm with lobster claw hand.



Preaxial polydactyly of left hand.Duplication of the left thumb with a narrow web space. It involves duplicated proximal and distal phalanges that share a common articulation with bifid first metacarpal head. The extra digit on the radial side of the left thumb with lack of function.

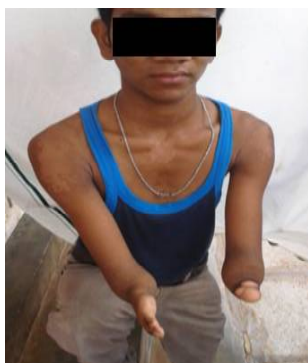Female child 4 years old: (Amniotic band syndrome) right upper limb with absence of forearm & hand. Other three limbs are normal (Fig. 12).

Fig. 12: Female child 4 years old: Amniotic band syndrome right upper limb with absence of forearm and hand. Other three limbs are normal.



Adult male 20 years old (Meromelia): upper limbs: arms are present, forearms are absent, right hand syndactyly with fused 2 digits and left hand is completely absent (Fig. 10).

Fig. 10: Adule male (Meromelia): Upper Limbs- arms are present, forearms are absent, right hand syndactyly with fused 2 digits and left hand is completely absent.



Achondroplasia(ACH): In the family, two brothers and one sister with 3' – 3' 4" height. Both extremities are very short, large head with flat nasal bridge. ACH is inherited autosomal dominant present in 1 per 20,000 live births. ACH

is also known as short limb dwarfism (Fig. 13).

Fig. 13: Achondroplasia: in the famil, 3' -3.4' height with short extremities.



DISCUSSION

Congenital limb deficiencies have proved valuable to the anatomist, the biochemists, the embryologists, the geneticist and the clinician to modify the final configuration of the deformity.

Limb differentiation occurs in a definite sequential order in a human embryo. The upper and lower limbs are recognizable first as small buds of tissue on the lateral body wall at the fourth week of gestation. The buds grow and differentiate rapidly by seventh week of gestation. The forelimb appears first followed by hind limb 1 to 2 days later. The various regions of the limbs grow in proximodistal sequence. The arm and the forearm appear before the hand. The skeletal elements of the limbs are found within the limb buds chondrify in a definite order and followed by ossification. The differentiation of soft tissue elements of the limb follows an order similar to the skeletal elements. Limb defects occur in 4th to 8th week of gestation during the embryonic phase.

Number of environmental factors inhibits the rate of differentiation of the part at precise stage of embryonic development of the limb. The degree of severity depends upon the teratogenic insult occurring on the fashioning of the limb bud. The common environmental agents are anoxia, radiation, antivitamin, hormones, drugs and some viral infections [5].

Bilateral reduction deformities have become common since introduction of thalidomide in 1958. Toxic effects of thalidomide and vitamin B deficiency showed similarities in several

reduction deformities. Thalidomide basically inactivates and interferes with the metabolism of vitamin B group and combines with it, leading to vitamin B deficiencies [2].

The study of inherited human limb malformations has continued to throw up new genes not previously suspected to play a role in limb development. Chromosomal aberrations lead to limb anomalies due to duplication or deficiency of genes involved in the limb development. Example: trisomy 13 (post axial polydactyly) [6,7]. trisomy 18 (pre axial polydactyly) and trisomy 21 (syndactyly) [8]. The need for performing karyotyping as a routine investigation in case of congenital limb anomalies may be presented with number of chromosomal aberrations. The most widely accepted classification of congenital limb anomalies was proposed by Frantz and O'Rahilly and presented by Swanson [9]. Embryological classification of congenital anomalies of the limb [9]:

I. Arrest of the developmental parts: Pectoral girdle, arm, forearm and hand (upper limb). Pelvic girdle, thigh, leg and foot (lower limb)

Transverse: This group represents congenital amputations ranging from Aphyalangia to Amelia.

Intermediate: In this group the hand or the foot is directly attached to the trunk, demonstrating the failure of development of intermediate segments of the limbs. Ex: Classical Phocomelia.

Longitudinal: preaxial or postaxial deficiencies:

Upperlimb: Radial: absence of radial or preaxial side of the limb (thumb or radius). Central: middle finger or metacarpal is missing. Ex: Cleft hand/foot (lobster hand or foot/). If 2nd, 3rd and 4th metacarpals are missing, it is a Claw hand. This feature is known as **Ectrodactyly**, involves the deficiency of one or more central digits of the hand or foot (split hand or foot), which is characterized by underdevelopment or absence of mesenchyme forming the central digital rays which appears bilaterally or unilaterally, ulnar: Deficiency on the ulnar side of the limb (little finger or ulna).

Lowerlimb: Tibial: Absence of tibia or preaxial side of the lower limb, Central: Cleft foot Absence of central rays, Fibular: Fibular deficiency or postaxial side of the limb. Absence of tibiae or fibulae with fusion of lower

limbs known as sirenomelia.

II. Failure of differentiation of the parts:

Upper limb: Shoulder: Undescended scapula or absence of pectoral muscles (Poland Sequence), Arm : Synostosis of elbow, Forearm : Synostosis of proximal radius and ulna, Hand: syndactyly – fusion of parts, mesenchyme between prospective digits in hand and foot plate is removed by cell death. 1 in 2000 births this process fails and results in fusion between 2 or more digits [1]. brachydactyly – shortening of the digits.

Lower limb: Pelvic girdle: congenital dislocation of the limb, Thigh: congenital dislocation of the knee, Leg: Arthrosis of tibia and fibula, Foot: Congenital club foot.

III. Duplication:

Polydactyly: (preaxial and postaxial) usually bilateral. Extra digits frequently lacks proper muscle connections and Mirror hand

IV. Over growth:

Digital gigantism or whole limb may be affected.

V. Congenital circular constriction and syndrome:

Amniotic bands can cause annular constrictions and may result in intrauterine gangrene leading to fetal amputations, it can be digits or the limb.

VI. Generalized skeletal defects:

Ex: Achondroplasia

Human inherited limb malformations based on fundamental knowledge of genes interacting and events governing the limb pattern formation. The major causes of limb malformations are abnormal genetic programming and intra-uterine disruption to the development. The Congenital Transverse deficiency is defined according to the last remaining bone segment ranging from aphalangia to Amelia. These defects are partial or complete absence due to disruption of apical ectodermal ridge or its signaling or vascular abnormalities.

Amelia is a rare condition with an incidence range from 0.053 to 0.095 in 10,000 live births. It is a traditionally sporadic anomaly with little risk of reoccurrence or genetic origin, but sometimes involved in autosomal recessive or sex linked dominant inheritance. Robert's syndrome, an autosomal recessive inheritance considered as single genetic entity includes babies being

reported with severe facial defects, tetra Amelia and pulmonary abnormality. Infants with Amelia only appear to have good prognosis whereas Amelia's associated with organ malformations die in 1st year of life [10,11].

The present survey has no case of Amelia.

Meromelia means partial absence of limb segments. Micromelia, all three segments of the limbs are present but abnormally short.

These abnormalities are rare and mainly hereditary, but teratogenic induced limb defects have also been documented. Many mothers of these infants had taken thalidomide between 4th and 5th week of gestation, a drug widely used as anti-nauseant, also used to treat AIDS and cancer patients. This is known as thalidomide syndrome [1].

Phocomelia is the long bones are absent and rudimentary hand and feet that look like flippers on a seal attached to the trunk by small shaped bones. It is a familial heritable form and is transmitted as an autosomal recessive trait. The gene mutation has been tracked to a site on chromosome 8 at gene map locus 8p21.1.

Phocomelia is a rare defect with prominent roots comes from the use of Thalidomide or genetic inheritance. It may be genetically transmitted within the family as an autosomal recessive trait with parents coming from consanguineous background. The risk of passing the abnormal gene from affected parent to offspring is 50% for each pregnancy regardless of the sex of the child. Increased prevalence of Phocomelia is 60% in association with thalidomide when taken during first trimester of pregnancy [9].

A Phocomelia syndrome is associated with limb defects and craniofacial anomalies [12].

The present survey had two fetuses, one with Phocomelia and other with Meromelia. Both were associated with severe visceral anomalies with no cleft lip or cleft palate which agree with above authors. These babies are still born and mothers are from very poor socioeconomic background. The study also had two adult males, one with meromelia with complete absence of forearms on both sides and both the hands with only two digits and other adult male Phocomelia with hands attached to trunk by a small shape bones.

Syndactyly (fusion of adjacent digits) is most common congenital anomaly with an incidence of 2 to 3 per 10,000 live births involving the regions on the chromosome 2 and considered to be autosomal dominant inheritance signifying familial propagation. Complicated syndactyly is frequently seen in generalized disorders like Poland, Apert's syndrome and Limb body wall complexes. Human limb phenotypes in Apert's syndrome is an autosomal dominant disorder caused by mutation in FGFR2 which plays a key role. It is characterised by combination of craniosynostosis and syndactyly. In the present study no isolated syndactyly was observed and the other two cases associated with generalized disorders. The study had one fetus with typical features of Apert's syndrome with syndactyly of both hands and feet and other fetus being with Limb body wall complex had Syndactyly of the right hand and left upper limb with meromelia i.e., absence of forearm and hand with only two digits. LBWC foetus was also associated with amniotic band syndrome of the toes [9].

Polydactyly can occur on preaxial or postaxial side of the limb. Post axial Polydactyly is an autosomal dominant pattern. Central polydactyly is an extra digit within the hand not along its borders commonly seen with ring finger duplication, associated with mutation of HOXD13 gene on chromosome 2. The Heterogeneous mutations of gene SALL1 in humans causes preaxial polydactyly. Treatment often requires reconstruction and alignment [13].

The current study had an adult male with Post axial polydactyly of right hand i.e. Duplication of the right thumb with a wide web space. Extra digit is present on the ulnar side of the right thumb with lack of function. He also had Pre-axial Polydactyly of left hand with duplication of the left thumb with a narrow web space. It involves duplicated proximal and distal phalanges that share a common articulation with bifid first metacarpal head. The extra digit was on the radial side of the left thumb with lack of function. Longitudinal limb reduction anomalies are much rarer than transverse ones. Classical anomalies can be on the preaxial side of the limb or postaxial side. It may vary from partial to complete absence which includes radial de-

ciency, ulnar deficiency, tibial deficiency, fibular deficiency or central deficiency. Sirenomelia is an example of vascular disruption theory leads to abnormal caudal dysgenesis syndrome. It presents with fusion of lower limbs associated with longitudinal deficiencies. In the present study, one fetus with sirenomelia had fused lower limbs. It presents with one femur, one tibia, no fibulae and no tarsal bones and only with one metatarsal and one toe (inverted).

Amniotic band syndrome is a heterogenous disease. These bands originate from tears in the amnion and surround the part of the fetus and may encircle the part of fetus, the limbs or digits cause ring constrictions followed by amputations leading to necrosis of superficial tissues. These bands may be associated with other abnormalities including craniofacial malformations, limb body wall complexes and gastroschisis or omphalocele. The diagnosis of amniotic disruption sequence requires the presence of constriction band affecting the extremity or the digits. The chemical risk factors like smoking, drug use and maternal hyperglycemia and mechanical risk factors such as the puncture of the amniotic sac after amniocentesis can all lead to Amniotic band constriction. Data from number of studies suggest that amniotic band syndrome is associated with young maternal age and unplanned pregnancy [1]. In this work, one fetus with LBWC was associated with syndactyly of fingers of upper limb and amniotic band syndrome in the toes of the feet. The work also had one female child with amniotic band syndrome of right upper limb and other three extremities were normal [14].

Split hand/ split foot malformation (SHFM)/ Lobster claw hand or foot is a heterogenous limb developmental disorder occurring at the 41th day of gestation. It is characterized by missing digits and fusion of the remaining digits giving a claw like appearance of the distal extremities. It is an autosomal dominant disorder mapped on chromosome 7q21.3-q22.1 associated with chromosomal rearrangement. While some may be has autosomal recessive or X-linked patterns of inheritance which occurs rarely [15]. The pathophysiology of cleft is thought to be a

result of a wedge-shaped defect of the apical ectoderm of the limb bud (AER: apical ectodermal ridge). A typical cleft hand is V shaped defect with phalanges missing and metacarpals are present, it is usually X-linked dominant trait with syndactyly of small, ring fingers and thumb, index fingers. Atypical claw hand is U shaped defect where index, long and ring finger are absent while metacarpals are present.

Ectrodactyly denotes congenital absence of all or a part of one or more fingers or toes, synonymous with split hand/ foot deformity or lobster claw hand/ foot. Ectodermal dysplasia is characterized by abnormal development of embryonic ectodermal tissue which leads to anomalies of hair, teeth, sweat glands, nails and limbs. This syndrome is known as ectrodactyly, ectodermal dysplasia and cleft lip with or without cleft palate (EEC syndrome) inherited as an autosomal dominant feature [16].

The current study showed an adult male with deformities of both the hands. Left hand showing split hand malformation, the classical lobster claw deformity. The right hand showing absence of index and ring fingers and had double cleft. Both feet were normal and not associated with EEC syndrome.

General skeletal dysplasia may be a common congenital dysplasia or acquired disorder. The congenital dysplasias may manifest as cleidocranial dysostosis, craniostenosis, achondroplasia and thanatophoric dysplasia. Common to all these skeletal dysplasia are mutations in FGFR3 causing abnormality in endochondrial ossification [1].

Achondroplasia or dwarfism is very rare and quite few are lethal. It is a nonlethal type of short limb dwarfism associated with autosomal dominant disorder. 1 per 20,000 live births are primarily affecting the long bones [1].

In the present survey a family presented with Achondroplasia. The affected people were two brothers and one sister.

Several reports indicate that administration of Thalidomide in early pregnancy may be followed by birth of malformed child. Most of these children had bilateral reduction deformities of the limbs, sometimes associated with malformations of ears, eyes or viscera. The limb buds

are more susceptible than viscera to the effects of Thalidomide [2].

Susceptibility to skeletal defects has been observed with respect to deficiencies of Riboflavin (vit B6) and Nicotinamide causing number of limb deficiencies. The difference between thalidomide and riboflavin limb defects is, thalidomide is not associated with cleft lip or cleft palate [17,18].

CONCLUSION

Detection of limb anomalies is now been enhanced by amniocentesis and high resolution ultrasound examination of developing fetus.

Management of congenital limb anomalies include classification, etiology, incidence, diagnosis before birth including genetic work up and counseling of the parents.

The limb defects require multidisciplinary approach that includes orthopedicians, dermatologist and plastic surgeon for cosmetic disturbance.

ACKNOWLEDGEMENTS

I most humbly acknowledge my patients who gave me intuitive guidance to write this article. Authors of this study also acknowledge to authors, editors & publishers of all those articles, journals & books from where the literature for this article has been reviewed and discussed.

Conflicts of Interests: None

REFERENCES

- [1]. T. W. Saddler. Langman's Medical Embryology. 11th edn. New Delhi. Wolters Kluwer Health (India) Pvt Ltd; 2011; p 113-145
- [2]. IAN M. LECK, Ph.D., M.B., Ch.B. and E. L. M. Miller, M.D., M.sc., D.P.H. Incidence of malformations since the introduction of thalidomide. British Medical Journal. 1962;16-20.
- [3]. Bamshad M et al. Reconstructing the history of human limb development: lessons from birth defects. *Pediatr Res.* 1999;45:291-9.
- [4]. Daluiski A, Yi SE, Lyons KM. The molecular control of upper extremity development: implications for congenital hand anomalies. *J Hand Surg [Am].* 2001;26:8-22.
- [5]. Alfred B. Swanson, M.D. Classification Of Limb Malformations On The Basis Of Embryological Failures. *ICIB.* 1966;6:1-15.
- [6]. Flatt AE. Genetics and Inheritance. In: The care of congenital hand anomalies. St Louis: Quality Medical Publisher. 1994.

- [7]. Martinez-Frias et al. Limb deficiencies in infants in Trisomy 13. *Am J Med Genet.* 2000;93(4):339-41.
- [8]. Tayel SM, Fawzia MM, Niran A Al-Naqeeb, Said Gouda, Al Awadi SA, Naguib KK. A morpho-etiological description of congenital limb anomalies. *Ann Saudi Med* 2005; 25(3):219-227.
- [9]. Scott H. Kozin. Upper-Extremity Congenital Anomalies. *J Bone Joint Surg Am.* 2003;85: 1564-1576.
- [10]. Bod M, Czeizel A, Ienz W. Incidence at birth of different types of limb reduction abnormalities in Hungary 1975- 1977. *Hum Genet* 1983;65(1):27-33.
- [11]. Kallen B, Rahmani TM, Winberg J. Infants with congenital limb reduction registered in the Swedish register of congenital malformation. *Teratology* 1984 feb;29(1):73-85.
- [12]. Moore KL, Persaud TVN, Torchia MG. Textbook of essentials of embryology and birth defects. The musculoskeletal system. 7th ed. Philadelphia: John . F. Kennedy;2008:248.
- [13]. Andrew O. M. Wilkie. Why study human limb malformations? *J. Anat.* 2003; 202;27-35.
- [14]. P. Cignini et al. Epidemiology and risk factors of amniotic band syndrome, or ADAM sequence. *Journal of Prenatal Medicine* 2012;6(4):59-63.
- [15]. Michael A et al. Characterization of the split hand/ split foot malformation locus SHFM1 at 7q21.3-q22.1 and analysis of a candidate gene for its expression during limb development. *Human Molecular Genetics.* 1996;5(5):571-579.
- [16]. M. J. Cylrac, E. Lashpa. Lobster-claw hand: A manifestation of EEC syndrome. *Indian J Dermatol Venereal Leprol.* January-February 2006;72:1.
- [17]. Murphy, M. L., Dagg, C. P., and Karnofsky, D. A. Comparison of teratogenic chemicals in the rat and chick embryos. *Pediatrics.* 1957;19:701.
- [18]. Chamberlain JG, Nelson MM. Multiple congenital abnormalities in the rat resulting from acute maternal niacin deficiency during pregnancy. *Experimental Biology and Medicine.* 1963 Apr 1;112(4):836-40.

How to cite this article:

M. Yesender, Asra Anjum, S. Saritha, B. Sadananda Rao, T.V. Ramani, Peter Ericson. LIMB DEFECTS: A SPECTRUM OF CORRELATED STUDY. *Int J Anat Res* 2016;4(1):1810-1818. **DOI:** 10.16965/ijar.2015.340