

## PREVALENCE OF ACCESSORY RENAL VESSELS AMONG CADAVERIC SPECIMEN IN COLLEGE OF HEALTH SCIENCES MEKELLE UNIVERSITY ETHIOPIA AND ITS CLINICAL IMPLICATION

Sunday Abba<sup>\*1</sup>, Berhanu Mebrahte G<sup>2</sup>, Peter E. Ekanem<sup>2</sup>, Lydia O. Bajeh<sup>3</sup>.

<sup>1,2</sup> College of Health Sciences, Biomedical science department, Anatomy unit, Mekelle University Ethiopia.

<sup>\*1</sup> College of Health Sciences, Anatomy department, Kogi State University Anyigba, Nigeria.

<sup>3</sup> Nursing Department, Sheba University College, Ethiopia.

### ABSTRACT

Renal transplantation is now an established operation for the treatment of selected cases of chronic renal failure. The procedure requires removal of the kidney from a donor and even the damaged kidney to be replaced. In either case, care must be taken to safe guard the renal vessels so as to avoid hemorrhage. Anatomic variations of the renal arteries are common in general population with different frequencies among several ethnic and racial groups. It is therefore imperative to understand renal vasculature and any form of variation that is associated with the renal blood supply within the context of any society.

The aim of this study was to establish the prevalence of the presence of accessory renal vessels in the college of health sciences Mekelle University Ethiopia, using cadaveric specimens.

Following the 12<sup>th</sup> edition Grant dissector (2005) guide for dissection we exposed the kidneys and their associated vessels were observed, counted and estimated in percentages.

The result showed a 10.7% prevalence of both accessory renal artery and 7.1% accessory renal vein and none in females.

We concluded that the prevalence of the accessory renal vessels among cadaveric specimen in the college of health science Mekelle University is less than the values reported by other studies.

**KEY WORDS:** Renal artery, Accessory renal artery, Variation, Mekelle.

**Address for Correspondence:** Dr. Sunday Abba, College of Health Sciences, Anatomy department, Kogi State University Anyigba, Nigeria. **E-Mail:** [suneabba007@gmail.com](mailto:suneabba007@gmail.com)

### Access this Article online

#### Quick Response code



DOI: 10.16965/ijar.2015.312

**Web site:** International Journal of Anatomy and Research  
ISSN 2321-4287  
[www.ijmhr.org/ijar.htm](http://www.ijmhr.org/ijar.htm)

Received: 06 Nov 2015	Accepted: 11 Dec 2015
Peer Review: 06 Nov 2015	Published (O): 31 Jan 2016
Revised: None	Published (P): 31 Jan 2016

### INTRODUCTION

Renal transplantation is now an established operation for the treatment of selected cases of chronic renal failure. The procedure requires removal of the kidney from a donor and even the damaged kidney to be replaced. In either case, care must be taken to safe guard the renal vessels so as to avoid hemorrhage. Anatomic

variations of the renal arteries are common in general population with different frequencies among several ethnic and racial groups [1].

These variations are becoming more important considering the gradual increase in the number of interventional radiological procedures, as well as urological- vascular operations and transplantations [2]. It is therefore imperative

to understand renal vasculature and any form of variation that is associated to the renal blood supply within the context of any society. The presence of an accessory renal artery has been reported to be present in 25% of the population [3]. This prevalence varies among different population. As a result, it becomes very important to establish the percentage of cases of accessory renal vessel in any population. The focus of this study is to establish the prevalence of accessory renal vessels by dissecting and observing their presence among cadaveric specimens in College of Health Sciences Mekelle University of Ethiopia.

During the ascent of the kidneys to their final position in the posterior abdominal wall, the embryonic kidneys receive their blood supply and venous drainage from successively more superior vessels [3]. Usually the inferior vessels degenerate and the superior ones take over the blood supply and venous drainage, failure of these inferior vessels to degenerate results in accessory renal arteries and veins.

The renal arteries branch laterally from the aorta just below the origin of the superior mesenteric artery. Both cross the corresponding crus of the diaphragm at right angles to the aorta. The right renal artery is longer and often higher, passing posterior to the inferior vena cava, right renal vein, head of the pancreas, and descending part of the duodenum. The left renal artery is a little lower and passes behind the left renal vein, the body of the pancreas and splenic vein. It may be crossed anteriorly by the inferior mesenteric vein [4].

A single renal artery to each kidney is present in 70% of individuals. The arteries vary in their level of origin and in their calibre, obliquity, and precise relations. In its extrarenal course each renal artery gives off one or more inferior suprarenal arteries, a branch to the ureter and branches which supply perinephric tissue, the renal capsule, and the pelvis. Near the renal hilum, each artery divides into an anterior and a posterior division, and these divide into segmental arteries supplying the renal vascular segments. Accessory renal arteries are common (30% of individuals), and usually arise from the aorta above or below the main renal artery and follow it to the renal hilum. They are regarded

as persistent embryonic lateral splanchnic arteries. Accessory vessels to the inferior pole cross anterior to the ureter and may, by obstructing the ureter, cause hydronephrosis. Rarely, accessory renal arteries arise from the coeliac or superior mesenteric arteries near the aortic bifurcation or from the common iliac arteries.

Existence of aberrant vessels is accountable in cases of renal pathologies, radiological interventions, renal transplants, and other surgical approach on them. Altered state of hemodynamics was thought of in cases of multiple arteries supplying the renal [4].

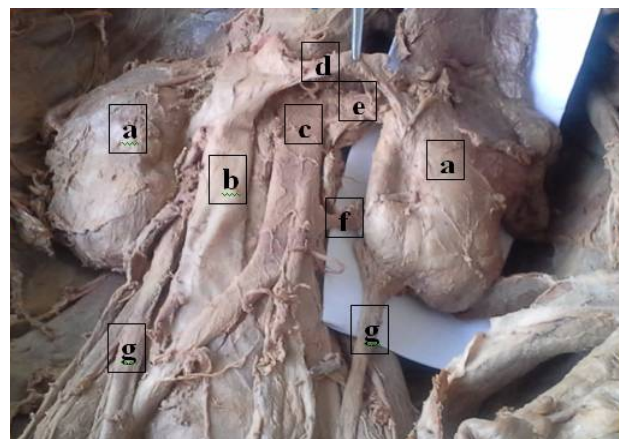
The aim of this study is to establish the prevalence of the presence of accessory renal vessels in the College of Health Sciences Mekelle University using cadaveric specimens.

## MATERIALS AND METHODS

**Research Design:** This research is a descriptive observational study in which dissected cadavers were observed for the presence of accessory renal vessels. The study was carried out in the dissection laboratory of the College of Health Sciences Mekelle University, Ethiopia. Study samples used for this study were all the dissected cadavers within the period of the study (2012-2015) i.e., a total of thirty two kidneys and their vessels were observed.

**Dissection procedure for exposing the kidneys and associated vessels:** Following the 12<sup>th</sup> edition Grant dissector (2005) guide for dissection we exposed the kidneys and their associated vessels as illustrated in the figure below.

**Fig. A:** Dissected posterior abdominal wall; (a) right and left kidneys, (b) Inferior vena cava, (c) abdominal aorta, (d) left renal vein, (e) left renal artery, (f) left accessory renal artery, (g) the left and right ureters, and other associated structures.

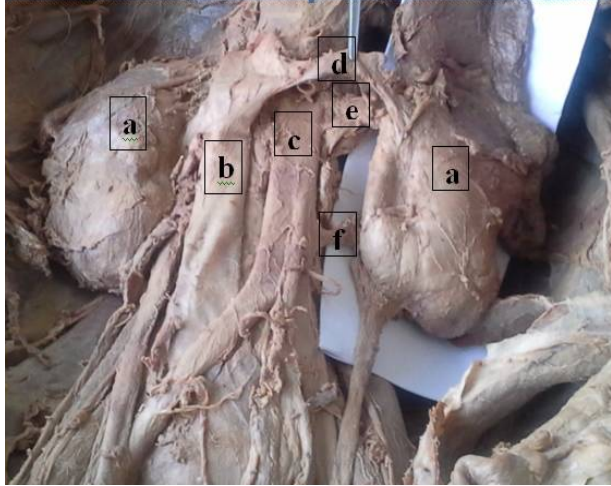




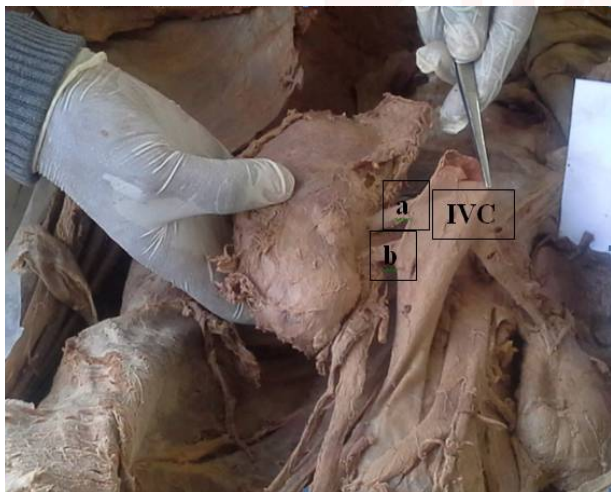
## RESULTS

The result of the observations made on the dissected bodies are shown in the figures below

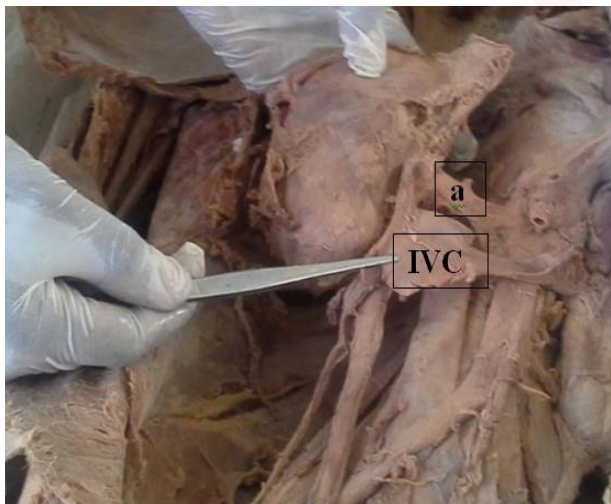
**Fig. B:** (a) The right and left kidneys, (b) Inferior vena cava, (c) abdominal aorta, (d) left renal vein, (e) left renal artery, (f) left accessory renal artery.



**Fig. C:** right kidney showing an extra vein draining into the inferior vena cava (IVC). a = normal renal vein, b = accessory renal vein.



**Fig. D:** Showing reflected IVC to reveal the right renal artery (a).



**Table 1:** Showing the prevalence of accessory renal vessels in male and female expressed in percentage.

SEX	Number of kidneys observed	Number of accessory renal artery present	Number of accessory renal veins present	Prevalence of accessory renal artery (%)	Prevalence of accessory renal vein %
Male	28	3	2	10.7	7.1
Female	4	0	0	0	0
Total	32	3	2	9.4	6.3

## DISCUSSION

The aim of this study was to estimate the prevalence of the presence of accessory renal vessels among cadaveric specimen in the College of Health Sciences Mekelle University Ethiopia. The result as expressed in percentages shows that the prevalence of accessory renal vessels is 17.9% in male and no case was observed in the female cadavers. The result showed that accessory renal vessels are less common among cadaveric specimens in Ethiopia as compared to values of 30% given by Strandings (2008) [4], and 25% given by Moore and persaud (2003) [3]. And also showed that accessory renal artery is common in males than females even if none was observed in the female cadavers. This may be due to sample of female cadavers that were observed.

Accessory renal arteries are common in fused kidneys [5]. In one of the kidneys observed in this study, accessory renal artery was seen to be present in a kidney that is excessively rotated such that the hilus faces lateral. Accessory arteries perforate the substance of the kidney rather than entering its hilum to supply it. All the ones observed in this study do not enter through the hilum, rather they perforate the inferior poles. Accessory renal arteries could arise as high as inferior phrenic artery or as low as internal iliac arteries. The unusual vessels may originate from the aorta, as well as gonadal, common iliac, middle sacral, external or internal iliac or superior or inferior mesenteric arteries. Superior renal polar renal arteries are usually single [5]. The ones observed in this study all arised from the abdominal aorta as shown in the diagrammes above. Accessory arteries have been in the causation of hydronephrosis [6].

Figure b, showed the presence of an accessory renal artery (f) branching from the abdominal aorta just at the level of L3. The artery pierces

the body of the left kidney to enter into it. This was not present on the right side as shown in figure d when the IVC was reflected. On the contrary, two accessory renal veins were observed on the right as shown in figure C.

The most common venous variant is the presence of supernumerary renal veins which can be seen in approximately 15–30% of individuals [7], and occasionally the accessory renal vein that can drain into the iliac vein. In this study supernumerary renal vein was only present 6.3% of the kidneys observed.

On the basis of many studies it has been accepted that the high frequency of variations are present in renal vessels. Variation in renal arterial pattern is more common as compared to venous pattern. Second additional renal veins occurred infrequently on the right side (5%) [8]. Variations of right renal veins are more common than the left [9]. In this present study an additional renal vein was only observed on the right kidney.

## CONCLUSION

We conclude that the prevalence of accessory renal artery among cadaveric specimen in the College of Health Sciences Mekelle University is approximately 10.7% in males, a value less than the values given in other studies. And accessory renal vein was 7.1%. Accessory renal vessels were not observed in the female cadavers.

**Recommendation:** Furthermore, study can be conducted with higher sample size and equal number of male and female cadavers may include for the study.

**Conflicts of Interests: None**

## REFERENCES

- [1]. Boijesen E. Renal angiography: techniques and hazards; anatomic and physiologic considerations. In: Baum S, ed. Abrams' angiography. 4th ed. Philadelphia: Little, Brown and Company, 1997;1101-1131.
- [2]. Khamanarong K, Prachaney P, Utravachien A, Tong-Un T, Sriporaya K. Anatomy of renal arterial supply. *Clin Anat.* 2004;17:334-336.
- [3]. Keith L. Moore. Persaud T.V.N. Clinically Oriented Embryology. 8<sup>th</sup> edition Saunders 2003.
- [4]. Standring S, ed. Gray's Anatomy. The Anatomical Basis of Clinical Practice. 40th Ed., Edinburgh, Churchill & Livingstone. 2008;1231-1233.
- [5]. Bergman RA, Thomson SA, Afifi AK, Saadeh FA. Compendium of Human Anatomic Variation. Baltimore, Urban & Schwarzenberg. 1988;81-83.
- [6]. Graves FT. The arterial anatomy of the congenitally abnormal kidney. *Br J Surg* 1969; 56: 533-541.
- [7]. Kadir S. Angiography of the kidneys. In: Kadir S, ed. Diagnostic angiography. Philadelphia: Saunders, 1986;445-495.
- [8]. Satyapal KS, Kalideen JM, Haffejee AA, Singh B and Robbs JV. Left renal vein variations. *Surg Radiol Anat.* 1999;21:77-81.
- [9]. Nayak BS. Multiple variations of the right renal vessels. *Singapore Med J.* 2008;49:153-155.

### How to cite this article:

Sunday Abba, Berhanu Mebrahte G, Peter E. Ekanem, Lydia O. Bajeh. PREVALENCE OF ACCESSORY RENAL VESSELS AMONG CADAVERIC SPECIMEN IN COLLEGE OF HEALTH SCIENCES MEKELLE UNIVERSITY ETHIOPIA AND ITS CLINICAL IMPLICATION. *Int J Anat Res* 2016;4(1):1750-1753. DOI: 10.16965/ijar.2015.312