

VARIATIONS OF SUPRASCAPULAR NOTCH IN ADULT EGYPTIAN SCAPULAE

Gamal Hamed El-Syed Hassanein *, Mohammad Bahgat Ali.

Department of Anatomy, Faculty of Medicine, Zagazig University, Egypt.

ABSTRACT

Background: The suprascapular notch (SSN) lies on the superior border of scapula, close to the root of coracoid process. The suprascapular nerve passes through the notch, below superior transverse scapular ligament. The objective of the present study was to determine variations in the size and shape of SSN in adult Egyptian scapulae to provide a better diagnosis and management of suprascapular nerve entrapment syndrome.

Material and methods: A total of 85 dry adult unpaired scapulae of unknown age and sex were randomly selected. The shape of SSN was determined by direct inspection and the vertical and transverse diameters of the notch were measured in each specimen. The results were recorded and statistically analyzed.

Results: In the studied scapulae, the SSN was revealed in 89.41%, absent in 8.24% and replaced by a scapular foramen in 2.35%. Three morphological types of SSN were observed; U-shaped (60.53%), V-shaped (31.58%) and J-shaped (7.89%). The SSN had a longest transverse diameter (type II) in 55.26% and had a longest vertical diameter (type III) in 44.74%. The U-shaped variety was observed in 32.61% of type II and 67.39% of type III. All of J-shaped variety (100%) were exclusively observed in type II, whereas half (50%) of the V-shape variety were observed in type II and the other half (50%) in type III.

Conclusion: The diameters and morphological type of SSN documented in the present study might be easily identified on a plain radiograph that might be helpful in diagnosis of suprascapular nerve entrapment syndrome. Moreover, these anatomical data would improve the safety of arthroscopic nerve decompression.

KEY WORDS: Egyptian Scapula, Suprascapular Notch, Suprascapular Nerve Entrapment.

Address for Correspondence: Dr. Gamal Hamed El-Syed Hassanein, Department of Anatomy, Faculty of Medicine, Zagazig University, Egypt. **E-Mail:** gamalhs@hotmail.com

Access this Article online

Quick Response code



DOI: 10.16965/ijar.2015.274

Web site: International Journal of Anatomy and Research
ISSN 2321-4287
www.ijmhr.org/ijar.htm

Received: 18 Sep 2015 Accepted: 13 Oct 2015
Peer Review: 18 Sep 2015 Published (O): 30 Nov 2015
Revised: None Published (P): 31 Dec 2015

INTRODUCTION

The superior border of the scapula, at its anterolateral end, is separated from the root of the coracoid process by the suprascapular notch (SSN). The notch is bridged by the superior transverse scapular ligament (SSTL) which is attached laterally to the root of the coracoid process and medially to the limit of the notch [1]. The SSTL is a strong fibrous band which may be a fan-shaped, a band-shaped or bifid-shaped [2]. Partial or complete ossification of SSTL sometimes occur [3-6].

The suprascapular nerve runs inferior to the SSTL, then obliquely across the floor of the supraspinous fossa, and passes around the neck of the scapular spine to enter the infraspinous fossa. It gives motor branches to the supraspinatus and the infraspinatus muscles and also gives sensory branches to the shoulder joint [7]. Lesions of the suprascapular nerve can occur at SSN or at the spinoglenoid notch (SGN) and electromyographic evaluation of the infraspinatus, and especially the supraspinatus muscles distinguishes SGN from SSN lesions [8]. Injury

to the nerve at the suprascapular notch causes weakness of both the supraspinatus and infraspinatus muscles, whereas injury at the spinoglenoid region affects only the infraspinatus muscle [9]. Entrapment of the suprascapular nerve at the SSN was first described in 1959 [10].

When the diagnosis of suprascapular nerve entrapment syndrome is being considered, variations in anatomy of the SSN and the SSTL are possible etiologic factors [3]. The size and shape of the SSN may be a factor in suprascapular nerve entrapment [4]. SSN variations were studied either on the basis of its morphological appearance [3], [11] or on the basis of geometric parameters of the SSN [12], [13]. The knowledge of normal diameters of SSN and the anatomical variations in its shape and size may be helpful in diagnosis and management of suprascapular nerve entrapments. The present study was done to determine and analyze the morphological types and diameters of the SSN in adult Egyptian scapulae to help clinicians to diagnose the suprascapular nerve entrapment and to improve the safety of arthroscopic nerve decompression in these conditions.

MATERIALS AND METHODS

In this study, eighty five adult Egyptian dry unpaired scapulae (46 right and 39 left) were collected from Department of Anatomy, Faculty of Medicine, Zagazig University. The selected specimens were of unknown age and sex and did not show any evidence of deformity or pathology. The scapulae without a discrete suprascapular notch (SSN) (fig.1) and those with a scapular foramen (SF) (fig.2) due to complete ossification of the superior transverse scapular ligament (STSL) were recorded and separated for later analysis. The scapulae with a distinct non-ossified SSN (fig.3) and those with partial ossification of STSL (fig.4), were classified on the basis of gross examination into U-shaped (fig.5) , V-shaped (fig.5) and J-shaped (fig.7) , as proposed by Iqbal et al [11] , and a photograph representing each type was documented using a digital camera and its percentage was calculated, recorded and tabulated.

After the morphological classification of SSN in

the scapulae with a distinct non-ossified SSN and those with partial ossification of STSL, the vertical and transverse diameters of SSN were measured using an imaginary line joining the two superior corners of the notch. The vertical diameter was taken as the maximal length of SSN starting from the imaginary line and perpendicular to it, whereas the transverse diameter was taken as the maximal width perpendicular to the midpoint of the vertical diameter (fig.8). A piece of rubber was fastened to the two tips of compasses and the two tips were placed on the two superior corners of the notch to represent the imaginary line. Then, a transparent ruler was placed perpendicular to the rubber and the distance from the rubber, passing over the deepest point of the SSN, was measured by a Vernier caliper to estimate the vertical diameter. The second transparent ruler was placed perpendicular to the first ruler, passing through the midpoint of the vertical diameter and the distance between the two lateral margins of the SSN was measured by a Vernier caliper to estimate the transverse diameter. Then, the morphological type of SSN was determined, based on the comparison of vertical and transverse diameter of SSN, according to the classification system proposed by Natsis et al [12] , into type II, with a longer transverse than a vertical diameter and type III, with a longer vertical than transverse diameter (fig.9). Each type was recorded and its percentage was calculated, tabulated and analyzed.

Fig. 1: The ventral surface of a right scapula showing absence of a suprascapular notch (SSN) on its superior border (arrow).

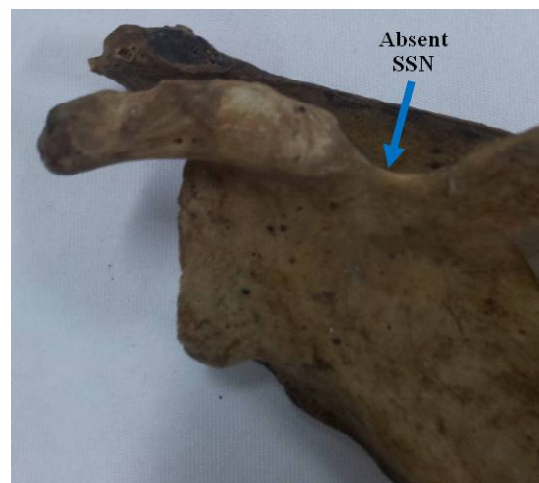

Fig. 2: The dorsal surface of a right scapula showing the presence of a scapular foramen (SF) on its superior border (arrow).

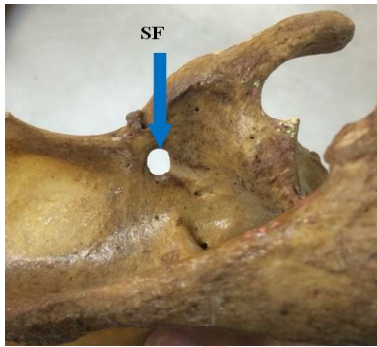


Fig. 3: The dorsal surface of a right scapula showing a distinct suprascapular notch (SSN) on its superior border (arrow).

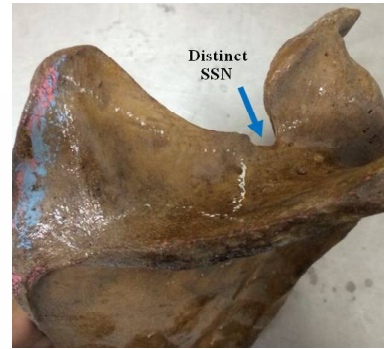


Fig. 4: The ventral surface of a left scapula showing partial ossification of the insertion points of superior transverse scapular ligament at the two superior corners of the suprascapular notch.

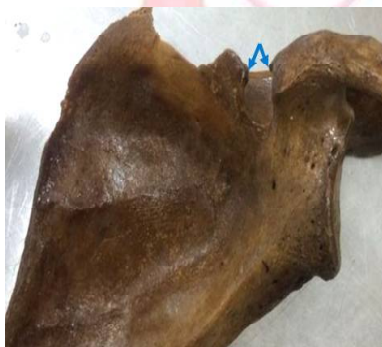

Fig. 5: The dorsal surface of a right scapula showing a U-shaped (arrow) suprascapular notch (SSN) on its superior border.

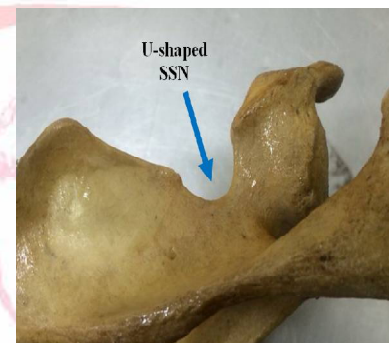

Fig. 6: The dorsal surface of a left scapula showing a V-shaped (arrow) suprascapular notch (SSN) on its superior border.



Fig. 7: The dorsal surface of a left scapula showing a J-shaped (arrow) suprascapular notch (SSN) on its superior border.

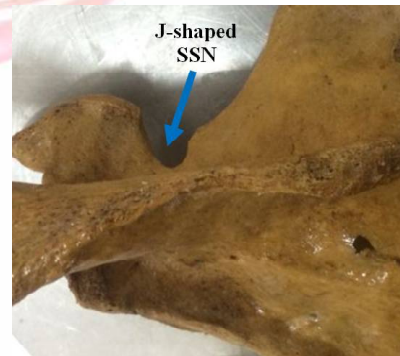
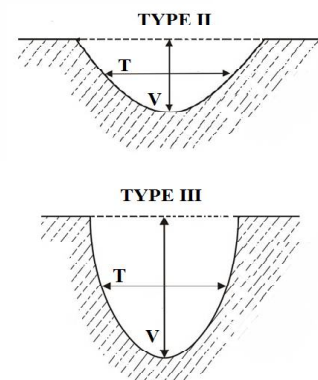


Fig. 8: Measurements of the suprascapular notch in a right scapula: (L) an imaginary line joining the superior corners, (V) the vertical diameter and (T) the transverse diameter.

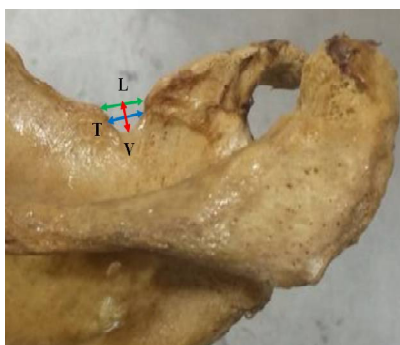

Fig. 9: A diagram showing type II suprascapular notch (SSN), with a longer transverse (T) than a vertical diameter (V) and type III SSN, with a longer vertical (V) than transverse diameter (T).



RESULTS

In the studied scapulae, 8.24% showed absence of a suprascapular notch, 89.41% revealed a distinct notch and 2.35% contained a scapular foramen (table 1 & fig.10). In the scapulae with a distinct suprascapular notch, 60.53% were U-shaped, 31.58 % were V-shaped and 7.89 % were J-shaped, based on gross examination as proposed by Iqbal et al [11] (table 2 & fig.11). Comparing the measured vertical and transverse diameters of suprascapular notch (SSN), based upon the classification of Natsis et al [12] , revealed that 55.26% of studied scapulae had type II SSN (longest in transverse diameter) and 44.74% had type III SSN (longest in vertical diameter). Type II SSN had a mean vertical diameter of 6.19 ± 0.99 mm & 6.16 ± 1.07 mm and a mean transverse diameter of 9.10 ± 1.45 mm & 9.30 ± 1.46 mm on the right and left sides respectively. Type III SSN had a mean vertical diameter of 8.96 ± 1.81 mm & 9.40 ± 1.56 mm and a mean transverse diameter of 6.26 ± 1.29 mm & 6.34 ± 0.90 mm on the right and left sides respectively (table 3). Based on the gross appearance of SSN, 32.61% and 67.39% of U-shaped variety were observed in type II and type III respectively. All of J-shaped variety (100%) were exclusively observed in type II, whereas half (50%) of the V-shape variety were observed in type II and the other half (50%) in type III (table 4).

Table 1: Categories of scapulae in the present study according to presence or absence of a suprascapular notch (SSN) or a scapular foramen (SF).

Characteristic feature	Incidence (%)		
	Total	Right	Left
Absent SSN	7 (8.24%)	4 (8.70 %)	3 (7.69 %)
Distinct SSN	76 (89.41%)	40 (86.96%)	36 (92.31%)
SF	2 (2.35%)	2 (4.35%)	-----
Total	85 (100%)	46 (100%)	39 (100%)

Fig. 10: A pie chart showing the incidence of suprascapular notch (SSN), compared to notch absence and scapular foramen (SF) in the studied scapulae.

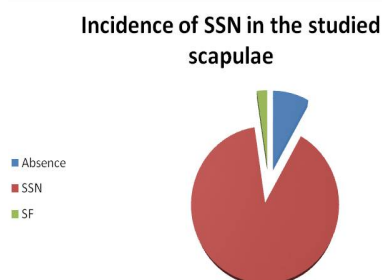


Table 2: Classification of suprascapular notch in the studied scapulae, based upon the gross examination of shape, as described by Iqbal et al [11].

Shape	Incidence (%)		
	Total	Right	Left
U-shaped	46 (60.53%)	27 (67.5%)	19 (52.78%)
J-shaped	24 (31.58 %)	9 (22.5%)	15 (41.67%)
V-shaped	6 (7.89 %)	4 (10%)	2 (5.56%)
Total	76 (100%)	40 (100%)	36 (100 %)

Fig. 11: A histogram showing the percentage of the observed morphological types of suprascapular notch (SSN) in the studied scapulae.

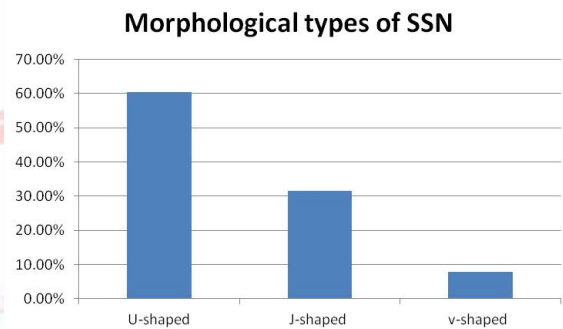


Table 3: Classification of the suprascapular notch (SSN) into type II & type III by comparing the measured vertical and transverse diameters, based upon the classification of Natsis et al [12].

	Type II 42/76 (55.26%)		Type III 34/76 (44.74%)	
	Right	Left	Right	Left
Number per side	23/40 (57.5%)	19/36 (52.78%)	17/40 (42.5%)	17/36 (47.22%)
Vertical diameter	6.19 ± 0.99 (4.21-8.56) mm	6.16 ± 1.07 (4.37-7.94) mm	8.96 ± 1.81 (4.87-11.54) mm	9.40 ± 1.56 (6.52-11.58) mm
Transverse diameter	9.10 ± 1.45 (6.78-11.54) mm	9.30 ± 1.46 (6.98-11.45) mm	6.26 ± 1.29 (4.21-9.63) mm	6.34 ± 0.90 (4.58-8.33) mm

Table 4: Incidence of the morphological types of the suprascapular notch (SSN), described by Iqbal et al [11] in type II & type III SSN, described by Natsis et al [12], in the studied scapulae.

Shape	Total	Type II			Type III		
		Right	Left	Total	Right	Left	Total
U-shaped	46 (60.53%)	11 (47.83%)	4 (21.05%)	15/46 (32.61%)	16 (94.12%)	15 (88.24%)	31/46 (67.39%)
J-shaped	24 (31.58%)	9 (39.13%)	15 (78.95%)	24/24 (100%)	---	---	---
V-shaped	6 (7.89%)	3 (13.04%)	--	3/6 (50%)	1 (5.88%)	2 (11.76%)	3/6 (50%)
Total	76 (100%)	23 (100%)	19 (100%)	42/76 (55.26%)	17 (100%)	17 (100%)	34/76 (44.74%)

DISCUSSION

Studies on the anatomical variations of the SSN are based on gross examination [3, 11] or on its geometric parameters [12, 13]. In the present

study, based on gross examination of SSN, three morphological types of SSN were observed; U-shaped (60.53%) , V-shaped (31.58 %) and J-shaped (7.89%), with U-shaped type being the most common one. These types, apart from differences in frequencies, are in accordance with the observations of Iqbal et al [11], in Pakistani population; U-shaped (13.2%), V-shaped (20%) and J-shaped (22%). However, in the latter study, the scapulae with indentation at site of suprascapular notch were ignored and J-shaped variety was the commonest one. In contrast to the present study, Ticker et al [3] and Dunkelgrun et al [4], only described two types of the SSN in American population; the U-shape and the V-shape. The incidence of U-shaped was 77% [3] and 73% [4], whereas incidence of the V-shape was 23% [3] and 27% [4]. In both studies, the U-shape was the prevalent type as documented in the present study. On the other hand, Sinkeet et al [14], in Kenyan population, described six types of SSN; type I (a wide depression) (22.2%) , type II (a wide blunted V shaped) (21.5%), type III (a symmetrical U shaped) (29.5%) , type IV (A small V shaped) (5.19%) , type V (partial ossification of the STSL (18.5%) and type VI (complete ossification of the STSL converting the notch into a complete bony foramen) (2.96%), with the U-shape (type III) the most prevalent type. The large number of SSN variations described by Sinkeet et al [14], compared to the three types described in the present study, could be attributed to the separation of V-shaped type by these authors into two categories; wide blunted type and a small type, moreover, they classified SSN with partial or complete ossification of STSL into separate types. In the present study, SSN with partial ossification of STSL were classified and measured as those with non ossified ligament. According to geometric parameters of SSN, Natsis et al [12], in scapulae of German origin, distinguished five types of SSN; type I; with absent SSN (8.3%) , type II; SSN longest in its transverse diameter (41.85%) , type III; SSN longest in its vertical diameter (41.85%), type IV; the STSL is calcified and forms a bony foramen (7.3%) and type V; the scapula has a notch and a bony foramen (0.7%). In the present study, 89.41% of the studied scapulae revealed a distinct SSN. The scapulae with absent SSN

(8.24%) or those presenting a scapular foramen (2.35%) were not included in the classification of SSN. The measurement and classification of SSN in the scapulae with distinct SSN (89.41%) was carried out, based on classification of Natsis et al [12], into type II SSN (longest in transverse diameter) (58.16%) and type III SSN (longest in vertical diameter) (28.23%), however, type V described by Natsis et al [12]; the presence of SSN and a scapular foramen, was not found in the present study. In accordance, Wang et al [13] similarly classified Chinese scapulae into four categories; type I; absent SSN (9.52%) , type II SSN (58.16%) and type III SSN (28.23%), type IV; scapular foramen (4.08%) and type V of Natsis et al [12] was similarly not found. In the present study, type II was prevalent (55.26%) than type III (44.74%). In agreement, Wang et al [13], apart from the differences in figures from the present study, similarly reported the prevalence of type II (58.16%) than type III (28.23%) SSN. On the other hand, type II and type III had equal percentage (41.85%) in the study of Natsis et al [12].

Ticker et al [3] reported partial and complete ossification of STSL, and described it to be a cause of a suprascapular nerve entrapment syndrome, and may also pose a challenge during decompression of the suprascapular nerve if the condition is not fully appreciated. In the present study, complete ossification of the STSL with conversion of the SSN into a foramen was not classified as a type of SSN, however, Natsis et al [12] and Wang et al [13] classified this finding as type IV SSN. On the other hand, Sinkeet et al [14] classified it as type VI. Das et al [15] reported that the entrapment of the suprascapular nerve by the ossified STSL may result in symptoms like pain in the shoulder region and also result in wasting and weakness of the supraspinatus and infraspinatus muscles. In the present study, the complete ossification of the STSL and the transformation of SSN into a foramen was found in 2.35% of scapulae. The rarity of this condition observed in the present study was similarly reported in Kenyans (2.96%) [14], in Chinese people (4.08%) [13], in Americans (5%) [3, 4] and in Germans (7.3%) [12], however, this condition seems very common in Brazilians (30.76%) [6]. This wide

variability in the incidence of complete ossification of STSL in different populations are probably attributed to due to racial factors rather than an aging process. Supporting this opinion, Dunkelgrun et al [4] described that there did not seem to be any relation between age and the degree of ossification of the STSL, when the scapular types were compared as two groups less than or equal to 50 years and greater than 50 years old.

As regard the morphological type of SSN and its possible role in suprascapular nerve entrapment, Cummins et al [16] reported that no direct correlation between the notch type and the suprascapular nerve entrapment has been shown clinically. In contrast, Dunkelgrun et al [4] stated that U-shaped notches had larger area than V-shaped notches, leading to the assumption that a V-shaped notch would be more likely to be found with nerve entrapment. In the present study, the higher incidence of the U-shaped notches (60.53%) and the much lower incidence of the V-shaped notches (31.58 %) would indicate that suprascapular nerve entrapment is unlikely among Egyptians. However, Avery et al [17] described for the first time the anterior coracoscapular ligament (ACSL) as a fibrous band extending on the anterior side of the SSN and stated that its presence reduces the height of SSN and should be considered as a possible etiological factor in suprascapular nerve entrapment. The authors described that the suprascapular nerve passes below ACSL, in close contact to the bony floor of the SSN and this is intensifying the risk of suprascapular neuropathy. On contrary, Polguy et al [2], in 41 of 44 dissected shoulders, described that the suprascapular nerve runs between the ACSL and STSL and it can hypothetically be protected from the sharp bony boundaries of the SSN.

CONCLUSION

In conclusion, the diameters and morphological type of SSN documented in the present study might be easily identified on a plain radiograph that might be helpful in diagnosis of suprascapular nerve entrapment syndrome. Moreover, these anatomical data would improve the safety of arthroscopic nerve decompression.

Conflicts of Interests: None

REFERENCES

- [1]. Standring S (Editor-In- Chief), Borley NR, Collins P, Crossman AR, Gatzoulis MA, Healy JC. Section 6 – Pectoral girdle and upper limb Chapter 46 -Pectoral Girdle, Shoulder region and Axilla. In: Gray's Anatomy The Anatomical Basis of Clinical Practice. 40th ed., Churchill Livingstone, 2008:791-822.
- [2]. Polguy M, Jędrzejewski K, Podgórski M, Majos A, Topol M. A proposal for classification of the superior transverse scapular ligament: variable morphology and its potential influence on suprascapular nerve entrapment. *J Shoulder Elbow Surg*. 2013;22(9):1265-73.
- [3]. Ticker JB, Djurasovic M, Strauch RJ, April EW, Pollock RG, Flatow EL. The incidence of ganglion cysts and other variations in anatomy along the course of the suprascapular nerve. *J Shoulder Elbow Surg* 1998;7(5):472-8.
- [4]. Dunkelgrun M, Iesaka K, Park SS, Kummer FJ, Zuckerman JD: Interobserver reliability and intraobserver reproducibility in suprascapular notch typing. *Bull Hosp Joint Dis* 2003;61:118–122.
- [5]. Khan MA. Complete ossification of the superior transverse scapular ligament in an Indian male adult. *Int J Morphol* 2006;24 (2):195-196.
- [6]. Silva JG, Abidu-Figueiredo M, Fernandes RMP, et al., High incidence of complete ossification of the superior transverse scapular ligament in Brazilians and its clinical implications. *Int J Morphol* 2007;25(4):855-859.
- [7]. Vorster W, Lange CP, Briët RJ, Labuschagne BC, du Toit DF, Muller CJ, de Beer JF. The sensory branch distribution of the suprascapular nerve: An anatomic study. *J Shoulder Elbow Surg* 2008;17(3):500-2.
- [8]. Liveson J A, Bronson M J, and Pollack M A Suprascapular nerve lesions at the spinoglenoid notch: report of three cases and review of the literature. *J Neurol Neurosurg Psychiatry* 1991;54(3):241-243.
- [9]. Walsworth MK , Mills JT 3rd, Michener LA. Diagnosing suprascapular neuropathy in patients with shoulder dysfunction: a report of 5 cases. *Phys Ther* 2004;84(4) : 359-72.
- [10]. Kopell HP, Thompson WAL. Pain and the frozen shoulder. *Surg Gynecol Obstet* 1959;109:92-96. (cited by Natsis et al, 2007)
- [11]. Iqbal K, Iqbal R, Khan SG. Anatomical variations in shape of suprascapular notch of scapula; *J Morphol Sci*. 2010;27(1):1-2.
- [12]. Natsis K, Totlis T, Tsikaras P, Appell HJ, Skandalakis P, Koebeke J. Proposal for classification of the suprascapular notch: a study on 423 dried scapulas. *Clin Anat* 2007;20(2):135-9.
- [13]. Wang HJ, Chen C, Wu L P, et al. Variable morphology of the suprascapular notch: an investigation and quantitative measurements in Chinese population. *Clinical Anatomy* 2011;24(1):47-55.

- [14]. Sinkeet SR, Awori KO, Odula, PO, et al. The suprascapular notch: its morphology and distance from the glenoid cavity in a Kenyan population. *Folia Morphologia* 2010;69(4):241-5.
- [15]. Das S, Suri R and Kapur V. Ossification of Superior Transverse Scapular Ligament and its Clinical Implications. *Sultan Qaboos Univ Med J*. Aug 2007;7(2):157-160.
- [16]. Cummins CA, Messer TM, Nuber GW. Current concepts review -Suprascapular nerve entrapment. *J Bone Joint Surg Am*. 2000;82(3):415-424
- [17]. Avery BW, Pilon FM, and Barclay JK. Anterior Coracoscapular Ligament and Suprascapular Nerve Entrapment. *Clinical Anatomy* 2002;15:383-386.

How to cite this article:

Gamal Hamed El-Syed Hassanein, Mohammad Bahgat Ali. VARIATIONS OF SUPRASCAPULAR NOTCH IN ADULT EGYPTIAN SCAPULAE. *Int J Anat Res* 2015;3(4):1536-1542. DOI: 10.16965/ijar.2015.274

