

Case Report

VARIANT OMOHYOID MUSCLE: REPORT OF TWO CASES

Shiva Murthy K ^{*1}, Syeda Tasneem Kauser ², Ashwini.C. Appaji ³, Komala. N ⁴.

^{*1,2} Post Graduate cum Tutor, Department of Anatomy, M.S.Ramaiah Medical College, Bengaluru, Karnataka, India.

^{3,4} Associate Professor, Department of Anatomy, M.S.Ramaiah Medical College, Bengaluru, Karnataka, India.

ABSTRACT

Omohyoid muscle consists of superior and inferior bellies connected by an intermediate tendon. Various anomalies of superior belly of omohyoid are described in literature. However, absence of superior belly of omohyoid is rarely reported. During regular head and neck dissection conducted for dental students at M S Ramaiah Medical College, variant omohyoid muscle were found in two male cadavers of south Indian origin. The variation noticed was unilateral in both the cases with normal inferior belly of omohyoid. In these cases the absent superior belly of omohyoid, is replaced by a fibrous tendon. Surgeons should be aware of this variation as it forms an important landmark for head and neck surgeries. It is also used as myocutaneous flaps for various reconstruction procedures.

KEY WORDS: Superior Belly, Inferior Belly, Omohyoid, Internal Jugular Vein.

Address for Correspondence: Dr. Shiva Murthy. K, Post Graduate cum Tutor, No: 9, Pipe Line Road, A cross, Bahubalinagar, Jalahalli, Bengaluru 560013, Karnataka, India. Phone number: 9535537340 **E-Mail:** shivuom.79622@yahoo.com

Access this Article online

Quick Response code



DOI: 10.16965/ijar.2015.138

Web site: International Journal of Anatomy and Research
ISSN 2321-4287
www.ijmhr.org/ijar.htm

Received: 11 Mar 2015 Accepted: 02 Apr 2015
Peer Review: 11 Mar 2015 Published (O): 30 Apr 2015
Revised: None Published (P): 30 June 2015

BACKGROUND

Omohyoid muscle is one of the infrahyoid muscles that consist of superior and inferior bellies connected by an intermediate tendon. Inferior belly arises from the upper border of scapula, near the scapular notch and from superior transverse scapular ligament. It passes behind sternocleidomastoid and ends in the intermediate tendon. The intermediate tendon lies on the internal jugular vein (IJV) at the level of the cricoid cartilage and is bound to the clavicle by a facial pulley. The superior belly begins at the intermediate tendon passes vertically upwards near the lateral border of sternohyoid and is attached to the lower border of body of hyoid bone lateral to insertion of

sternohyoid. The superior belly of omohyoid [SOH] forms an important landmark for dividing the neck into various triangles and for the recognition of important structures of neck. Absence of superior belly of omohyoid is a rare anomaly. However multiple origin and unusual origin of the muscle, insertion and fusion of the omohyoid with sternohyoid have been reported [1].

The deep group of cervical lymph nodes are divided by intermediate tendon of omohyoid into upper and lower group. Among the lower group, the jugulo-omohyoid lymph node, which is the principal lymph node of tongue is identified by intermediate tendon of omohyoid, as these are

found just above the tendon over the internal jugular vein. Hence the muscle is utilized routinely by clinicians as a consistent landmark [2].

Here a variant form of omohyoid seen in two cadaver specimens are being reported.

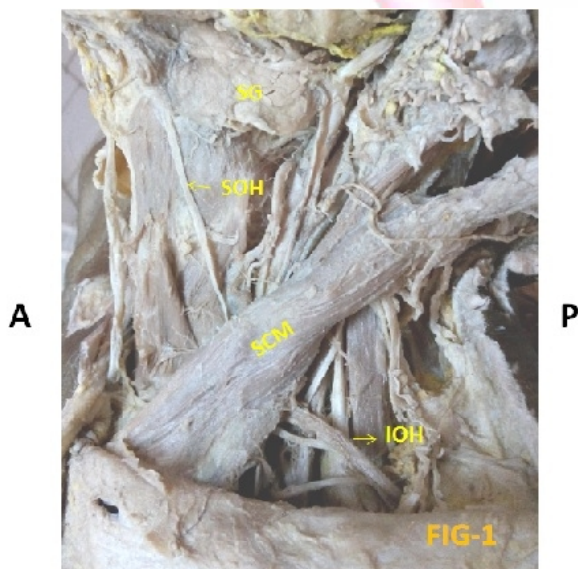
CASE REPORT

During regular head and neck dissection conducted for dental students at M.S. Ramaiah Medical College the following variation was observed in two cadavers:

1. In one male cadaver aged around 60 years (Fig-1), superior belly of omohyoid was absent on left side. A fibrous band was found extending from intermediate tendon to hyoid bone lateral to sternohyoid muscle in the place of superior belly. On the right side the muscle was normal.
2. In another male cadaver aged around 65 years (Fig-2), superior belly of omohyoid was absent on right side. Fibrous band was seen to replace the superior belly of omohyoid. On the left side the origin, insertion of the muscle belly was normal.


The Inferior belly of omohyoid was normal in origin and insertion in both cadavers. After further dissection and fine cleaning of the related structures, the findings were noted and necessary photographs were taken.

Fig. 1: Absent superior belly of omohyoid in human specimen 1 (left side).



SG-submandibular gland; SOH-superior belly of omohyoid; SCM-sternocleidomastoid muscle; IOH-inferior belly of omohyoid.

Fig. 2: Absent superior belly of omohyoid in human specimen 2 (right side).



SG-submandibular gland; SOH-superior belly of omohyoid; SCM-sternocleidomastoid muscle; IOH-inferior belly of omohyoid.

DISCUSSION

A study conducted by Rai.R et.al reports 85% of normal and 15% of variations in omohyoid muscle [3].

Unusual omohyoid forms described by Bergman et.al include cleidofascialis, which originates from the middle third of the clavicle and inserts into the fascia colli; cleidohyoideus which originates behind the sternocleidomastoid muscle and inserts onto the body of the hyoid bone and hyofascialis which originates from the hyoid and inserts into the omosternoclavicular fascia [4].

Embryologically, all the infrahyoid muscles are formed from a muscle primordium occurring in the anterior cervical area. The muscle primordium is first divided into a shallow and a deeper layer. The deep layer forms the sternothyroid and thyrohyoid muscles. The shallow layer becomes the splenius separated into internal and external muscles. The internal muscle becomes the sternohyoid muscle and runs straight into the anterior cervical region. The lower part of the external muscle grows in the external and inferior direction and becomes the omohyoid, which runs obliquely in the lateral cervical area [5].

Absence of superior belly of omohyoid has been reported in three studies [6] [7] [8]. In one of the

S.N	VARIATION	DESCRIPTION	PERCENTAGE
1	Cleidohyoideus	Inferior belly arising from clavicle and superior belly attached to hyoid bone.	6%
2	Double omohyoid (both bellies)	Superior and inferior omohyoid	3%
3	Short omohyoid	Inferior belly from clavicle and superior belly merging with sternohyoid.	3%
4	Double origin of superior belly	Superior belly receiving slips from sternum with normal inferior belly.	3%

Table 1: Description of variations in the omohyoid muscle (Rai.R et.al).

Types	FEATURES
1	Unclear anterior margin of the superior belly due to the poor myofiber development.
2	The superior belly was composed of a posterior large belly and an anterior small belly.
3	Superior belly composed of three to five bellies and the bellies were arranged in a roof tile like morphology.
4	The superior belly was found to consist of two bellies arranged parallel to each other in antero-posterior direction.

Table 2: Variations of Superior belly of Omohyoid (Sukekawa R et.al).

cases, the superior belly was totally absent [6]. One case was very similar to the present study where in the superior belly was replaced by a fibrous band [7]. Another similar case reported absence of superior belly of omohyoid [8]. Inferior belly of omohyoid were found to be normal in all these cases and the variations were unilateral.

A study was done on intermediate morphologies between normal and anomalous morphology of the superior belly of omohyoid. The intermediate morphologies were classified into 4 types as shown in table 2 [9].

When the above mentioned literature is compared with present case series, it can be noticed that multiple bellies of SOH is more common than its absence. When the muscle belly is absent it is usually replaced by a fibrous band. This has been observed in the present case series as well as the case reports mentioned above. The classification of anomalies of SOH (table 2) does not mention the absence or replacement by a fibrous band. So, total absence of SOH is a rare entity. This further emphasizes the importance of omohyoid existence.

Omohyoid is important in neck dissections because it is the surgical landmark for level 3 and 4 lymph node metastases [3]. Wang et.al reported that infrahyoid myocutaneous flaps are used for the reconstruction of the tongue after resection of lingual carcinoma [10]. The omohyoid muscle is the best landmark for identifying the internal jugular vein; any variation in this muscle may increase the risk of injuring the internal jugular vein during surgeries in the lower neck region [11]. Marian Simka et.al reported a multiple sclerosis patient presenting with compression of internal jugular vein caused by aberrant omohyoid muscle [12]. Omohyoid muscle flap has been also used for treatment of bowed vocal cords [13].

CONCLUSION

Surgeons operating in the region of neck should be aware of the variations of superior belly of omohyoid which is one of the important landmarks for identifying various important structures to prevent inadvertent complications during surgery. The Omohyoid muscle has been successfully used for reconstructions of small

and medium size defects in the neck caused due to tumor resection and also for laryngeal muscles. The omohyoid muscle is an important landmark for identification of internal jugular vein for IJV puncture which is usually done on the right side. It is also used as a landmark for endoscopic exploration of brachial plexus.

Anatomically, it forms the boundaries of the carotid and muscular triangles and also divides the posterior triangle into a carefree and careful zone.

Hence, omohyoid variant anatomy is of surgical importance for various procedures in the head and neck. Knowledge of the same helps the surgeons to find alternate methods and landmarks in the variant omohyoid cases.

Conflicts of Interests: None

REFERENCES

- [1]. Standring S: Gray's anatomy- The anatomical basis of clinical practice. 39th ed. Edinburgh: Churchill and Livingstone; 2005:538-539.
- [2]. A.K.Dutta: Essentials of human anatomy, Head and Neck. 4th ed. Current books international, Kolkata; 2004:191-193
- [3]. Rai.R, Ranade A, Nayak.S, Vadgaonkar R, Mangala P, Krishna MurthyA. A study of anatomical variability of the omohyoid muscle and its clinical relevance. Clinics 2008; 63(4):521-524.
- [4]. Bergman RA, Afifi AK and Miyauchi R. illustrated encyclopedia of Human anatomic variation. Muscular system omohyoideus, sternohyoideus, thyrohyoideus, and sternothyroideus. 1996. <http://www.anatomyatlases.org/AnatomicVariants/MuscularSystem/muscleGroupings/21infracoroid.shtml>. Accessed 28.02.2015.
- [5]. Lewis WH: The development of the muscle system, manual embryology. 1st edn. lippincott, Philadelphia; 1910:454-522.
- [6]. Ashwini Aithal P, Naveen kumar, Satheesha Nayak B. Absence of the superior belly of omohyoid muscle: a case report. JPBMS 2012; 23(12):1-2.
- [7]. Rajesh Thangarajan et.al. Unusual morphology of the superior belly of omohyoid muscle. Anat Cell Biol 2014; 47: 271-273.
- [8]. Tamega OJ, Garcia PJ, Soarer JC, Zorzetto NL. About a case of absence of superior belly of the omohyoid muscle. Anat Anz. 1983; 154:39-42.
- [9]. Sukekawa R, Itoh I. Anatomical study of the human omohyoid muscle: regarding intermediate morphologies between normal and anomalous morphologies of the superior belly. Anat Sci int 2006; 81:107-114.
- [10]. Wang HS, Shen JW, Ma DB, Wang JD, Tian AR. The infracoroid musculocutaneous flap for reconstruction after resection in head and neck cancer. 1986; 57:663-668.
- [11]. Naveen kumar Bandarupalli, Srinivasa Rao Bolla. Bilateral Cleidohyoideus accessorius muscle- a case report. Journal of evolution of medical and dental sciences 2013; vol2 (4):356-359.
- [12]. Marian simka et. al. Internal jugular vein entrapment in a multiple sclerosis patient. Case reports in Surgery 2012:1-5.
- [13]. Kojima H, Hirano S, Shoji K, Omori K, Honjo I. Omohyoid muscle transposition for the treatment of bowed vocal fold. Ann Otol Rhinol Laryngol 1996; 105: 536-540.

How to cite this article:

Shiva Murthy K, Syeda Tasneem Kauser, Ashwini.C. Appaji, Komala. N. VARIANT OMOHYOID MUSCLE: REPORT OF TWO CASES. *Int J Anat Res* 2015;3(2):991-994. DOI: 10.16965/ijar.2015.138