

## STUDY OF MEDIAL CIRCUMFLEX FEMORAL ARTERY AND ITS CLINICAL AND SURGICAL IMPORTANCE

Sowmya S <sup>\*1</sup>, Meenakshi P <sup>2</sup>, Sharmada KL <sup>3</sup>.

<sup>\*1</sup> Assistant Professor, Department of Anatomy, Bangalore Medical college & Research Institute, Bangalore, Karnataka, India.

<sup>2</sup> Associate Professor, Department of Anatomy, Bangalore Medical college & Research Institute, Bangalore, Karnataka, India.

<sup>3</sup> Tutor, Department of Anatomy, Bangalore Medical college & Research Institute, Bangalore, Karnataka, India.

### ABSTRACT

**Background:** The diagnosis and treatment of idiopathic ischemic necrosis of head of femur needs the anatomy of medial circumflex femoral artery (MCFA) which is the main source for the blood supply of head of femur. As it gives the muscular perforators its knowledge is important in the posteromedial cutaneous flap (gracilis flap). In the femoral artery obstruction, MCFA takes bypass route for the blood supply of lower limb as it forms anastomosis with branches of other arteries.

**Objectives:** The study describes the origin and course of the medial circumflex artery.

**Methods:** The present study was conducted on 50 lower limbs from embalmed human cadavers from the Department of Anatomy, Bangalore Medical College and Research Institute, Bengaluru. Femoral triangle was dissected and the medial circumflex artery and branches were traced.

**Results:** The study describes that in 8-10% cases MCFA showed variations whereas in 90-92% cases the MCFA has taken normal origin and course

**KEY WORDS:** Medial circumflex artery, Profunda femoris artery, Femoral artery.

**Address for Correspondence:** Dr Sowmya S, Assistant Professor, Department of Anatomy, Bangalore Medical College & Research Institute, Bangalore-560002, Karnataka, India.

**E-Mail:** drsowmyanandan@gmail.com

### Access this Article online

#### Quick Response code



DOI: 10.16965/ijar.2014.539

**Web site:** International Journal of Anatomy and Research  
ISSN 2321-4287  
[www.ijmhr.org/ijar.htm](http://www.ijmhr.org/ijar.htm)

Received: 18 Nov 2014

Peer Review: 18 Nov 2014 Published (O):31 Dec 2014

Accepted: 02 Dec 2014 Published (P):31 Dec 2014

### INTRODUCTION

The medial circumflex femoral artery usually originates from the posteromedial aspect of the profunda, but often originates from the femoral artery itself. It supplies the adductor muscles and curves medially around the femur between pectineus and psoas major and then between obturator externus and adductor brevis, finally appearing between quadratus femoris and adductor magnus. It divides into transverse and

ascending branches. The transverse branch takes part in the cruciate anastomosis. The ascending takes part in the trochanteric anastomosis.

The primary source for the blood supply of the head of the femur is the deep branch of the medial femoral circumflex artery (MFCA) and also gives four superior retinacular and occasionally inferior retinacular vessels. In posterior approaches to the hip and pelvis the

short external rotators are often divided. This can damage the deep branch and interfere with perfusion of the head.

MCFA can be used in flaps in reconstructive surgery or in selective arteriography in idiopathic ischemic necrosis of the femoral head to determine its arterial supply. It can be injured during femoral neck fracture or hip dislocation or in surgery of the hip joint [1]. To prevent necrosis of the femoral head it is important to take care that the artery is not severed. Because of its importance its normal and variation anatomy should be borne in mind if undesirable outcomes are to be avoided. All these procedures need precise knowledge of anatomy of medial circumflex femoral artery. Hence in this study an attempt is made to study the origin, course, and branching pattern of medial circumflex femoral artery.

**Review of literature:** Usual origin of MCFA was found in 123; the directly from FA in 41 cases. Medial circumflex femoral artery may arise from the profunda femoris before lateral circumflex femoral artery; from the femoral artery, external iliac artery or one of its branches or superficial epigastric artery [2]. The origin pattern of the medial circumflex femoral artery in 61.7% belonged to type 1 Adachi's classification [3]. The MCFA arises from the medial side of profunda or occasionally from the FA very near its lateral companion and immediately passes backwards between pectineus and the psoas tendon [4]. The origins of the circumflex femoral arteries were classified into two groups. In group A, medial and lateral circumflex arteries arose from the deep femoral artery. In group B either one or both femoral circumflex arteries arose from the common femoral artery. The distance of origin of the deep femoral artery from the midpoint of the inguinal ligament was measured in both groups and compared. In 300 male and 300 female femoral angiographies and noticed distinct intergender differences in the incidence of direct origin of the medial circumflex artery from the femoral artery (17.8% in males and 80% in females) [5]. In 79 extremities (79%) medial circumflex artery branched from deep femoral artery, while in 15 extremities (15%) it branched from femoral artery. In four (4%) extremities it was found to be double – one from femoral

artery and other from deep femoral artery. In one of these 4 cases, lateral circumflex femoral artery was also double. In one case they found common trunk for medial circumflex femoral artery and deep femoral artery and in another case a common trunk for medial circumflex femoral artery, deep femoral artery and lateral circumflex femoral artery [6].

A rare variation of the MCFA, arising by a common trunk with the PFA, also coursed superficially to the femoral vein to continue further [7]. MCFA took origin from the posterolateral aspect of the FA, 32 mm distal to the inguinal ligament. A frequency rate of 17–26% has been reported regarding this variation. However, MCFA emerged from the posterolateral aspect of the FA 3.2cm distal to the inguinal ligament [8].

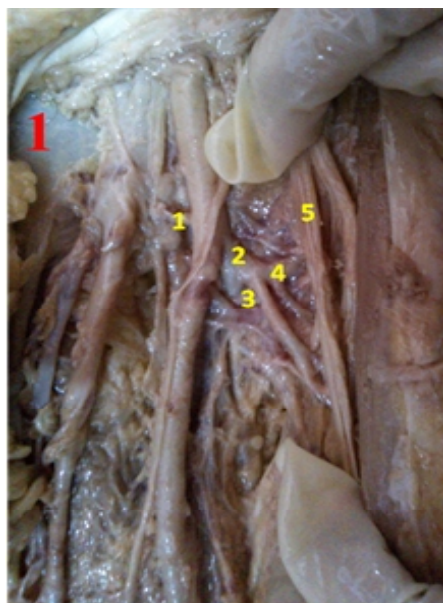
## MATERIALS AND METHODS

The present study was conducted in Department of Anatomy, Bangalore Medical College and Research Institute, Bangalore, Karnataka, India. Study conducted on 50 lower limbs from embalmed cadavers preserved in 5% formalin solution. Dissection of femoral artery and its branches were carried out by adopting the dissection methods as given in the Cunninghams 'Manual of Practical Anatomy' Volume; I 15<sup>th</sup> ed, Upper limb and Lower limb, Photographs of each specimen were taken after dissection, with digital camera.

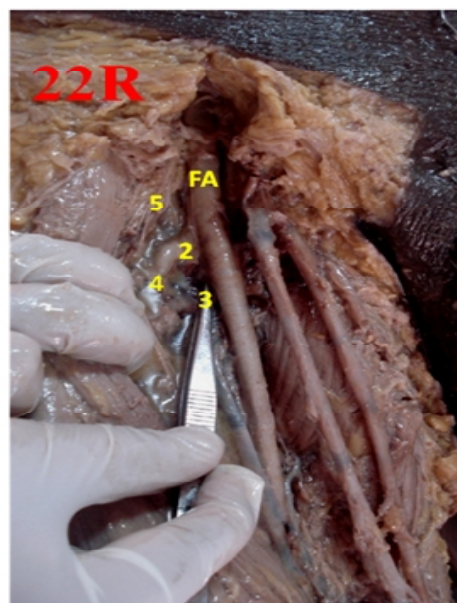
## RESULTS

Origin of MCFA was from PFA in 46 cases (92%) & FA in 4 (8%) (Fig.1). The mean distance of origin of MCFA from PFA ranged from 0.1-5.6 cm & from FA ranged from 0.5 to 8.5 cm. The mean was 1.8 cm. In present study the distance between the origins of MCFA from the origin of PFA was 0.1 – 2.7cm in 39 cases and 2.8 – 5.6cm in 7 cases out of 46 cases which originated from PFA (Fig.2). Out of 7 cases which originated from FA, the distance between origin of MCFA and midinguinal point ranging from 0.5 – 4.2cm in 3 cases and 4.3-8.5cm in one case. The origins of MCFA were compared with other authors (Table1). The distance between origin of MCFA and origin of PFA between 0-3cm in 19 cases on right side and 21 on left side, between 3-6cm in 2 on right side and 4 on left side.

**Fig. 1:** Specimen showing normal origin of MCFA



**Fig. 2:** Specimen showing origin of MCFA directly from FA



1. Deep circumflex femoral artery 2. Profunda femoris artery 3. MCFA 4. Lateral circumflex femoral artery 5. Femoral Nerve.

## DISCUSSION

In present study the MCFA originated from PFA in 46 cases (92%) and from FA in 4 cases (8%). The origins of MCFA were compared with other authors. In a study MCFA arises from the FA more frequently than the LCFA [9]. An author mentioned that in 200 limbs MCFA took origin from PFA in 123 limbs and in 41 limbs from FA<sup>2</sup>. The MCFA arises occasionally from the FA very near its lateral companion and immediately passes backwards between pectineus and psoas tendon [10]. The pattern of origin of MCFA in different studies are tabulated and compared with present study (Table 1)

**Table 1:** Comparison of variations of origin of MCFA with other studies.

S. No.	Authors	Prevalence of origin of MCFA from PFA	Prevalence of origin of MCFA from FA
1	Tanyeli et al. (2006) [6]	79	21
2	Siddarth et al. (1985)[11]	63	37
3	Dixit et al. (2001) [12]	62.5	37.5
6	Prakash et al. (2009) [13]	67.2	32.8
7	Present study	92	8

## CONCLUSION

The MCFA took normal origin from PFA in 92% cases & showed variation by taking origin directly from FA in 8% cases. The distance between origin of MCFA and origin of PFA ranged

between 0.1-2.7cm in 84.8% cases and 2.8 – 5.6cm in 15.2% cases among 46 specimens. So the MCFA showed normal origin and course in 90-92% cases.

**Conflicts of Interests:** None

## REFERENCES

- [1]. Moore KL, Dalley AF and Agur AMR. Clinically Oriented Anatomy, Lower limb. 6<sup>th</sup>ed. New Delhi: Wolters Kluwer,2010;p. 554-555.
- [2]. Bergman RA, Afifi AK, Miyauchi R, origin of deep group and circumflex group of arteries, cardiovascular system, Illustrated Encyclopedia of Human Anatomic Variation. OpusII.
- [3]. Emura S, Shoumura S, Ishizakin, et al. The Anatomical study on the branches of the femoral artery(II). Comparison with the findings of Adachi's classification .Kaibogaku Zasshi, 1989, 64(3):196-205.
- [4]. Perera J. Anatomy of origin of the deep femoral artery. Ceylon Med J. 1995 Dec; 40(4): 139-41.
- [5]. Basar R, Sargon MJF, Cumbhur M, et al. Distinct intergender difference in the femoral artery ramification patterns found in Turkish population; angiographic study. Anat Soc India Dec 2002; 77(4):250-3.
- [6]. Tanyeli E, Uzel M, Yildiram M, et al. An anatomical study of the origins of the medial circumflex femoral artery in Turkish population . Clin Anat 2006; 20(2): 180-5.
- [7]. Chitra R. A rare variational anatomy of the Profunda Femoris artery. Folia Morph 2008 May; 67(2): 157-8.

- [8]. Ciftcioglu E, Kopuz A, Eclizer M, Aydin E, Demir MT. Medial circumflex femoral artery with different origin and course: a case report and review of the literature. *Folia Morphol.* 2009; 68(3):188-191.
- [9]. Hollinshed WH. *Anatomy for surgeons*. Vol.3, Philadelphia: Hoeber- Harper International; 1966: p.705.
- [10]. Sinnatamby CS. *Last's Anatomy Regional and Applied*. 12<sup>th</sup> ed. China: Churchill Livingstone Elsevier; 2011:p.118-119.
- [11]. Siddarth P, Smith NL, Mason RA, Giron F, Variational anatomy of the deep femoral artery, *Anat rec*, 1985,212(2):206-209.
- [12]. Dixit DP, Mehta LA, Kothari ML. Variation in the origin and course of profunda femoris. *J Anat Soc India* 2001;50(1):6-7.
- [13]. Prakash, Jyothi Kumari, et al. Variations in the origins of the Profunda Femoris, medial and lateral circumflex arteries: a cadaver study in the Indian population. *Romanian Journal of Morphology and Embryology* Jan 2010, 51(1):206-209.

**How to cite this article:**

Sowmya S, Meenakshi P, Sharmada KL. STUDY OF MEDIAL CIRCUMFLEX FEMORAL ARTERY AND ITS CLINICAL AND SURGICAL IMPORTANCE. *Int J Anat Res* 2014;2(4):748-751.

**DOI:** 10.16965/ijar.2014.539