

Demonstration of the Neurovasculature of the Platysma Muscle and Its Role in Facial Reanimation

Naser A. ElSawy *¹, Abdullah G. Al-Kushi ², Naief A Dahran ³, Reham M Filfilan ⁴,
Nada Mohamed Mohamed Soliman ⁵, Mohammed A. S. Amin ⁶.

*^{1,5&6} Department of Anatomy and Embryology, Faculty of Medicine, Zagazig University, Egypt.

² Department of Anatomy, Faculty of Medicine, Umm Al-Qura University, Makkah 24382, Saudi Arabia.

³ Department of Basic Medical Sciences College of Medicine, University of Jeddah, Jeddah, Saudi Arabia.

⁴ Department of Clinical Laboratory Sciences, Faculty of Applied Medical Sciences Umm Al-Qura University, Makkah, Saudi Arabia.

ABSTRACT

The platysma is a superficial muscle located in the neck overlapping the sternocleidomastoid muscle. It is innervated by the cervical branch of facial nerve. The platysma is a potential candidate for use in free muscle transfer for facial reanimation around the eye due to its lack of muscle bulk. It has been used extensively in intraoral reconstruction. The purpose of this study is to demonstrate the possibility of using platysma free flap through detailing the precise neurovasculature of the platysma in relation to two bony landmarks: the mental protuberance and the angle of the mandible. Measurements were done using calipers to measure the shortest distance from the edge of the insertion of each vessel or nerve to the mark of the mental protuberance or angle of the mandible on the platysma. Measurements were taken to 6 old male German cadavers, 4 Caucasian from Umm Al-Qura University, Saudi Arabi and 20 cadavers' specimens and jars from Human Anatomy and Embryology department, Zagazig University. Our results show there are close proximity to the cervical branch of the facial nerve and the blood vessels of platysma would be attached to the superficial temporal branches and the nerve of platysma attached to an ipsilateral branch of the facial nerve.

KEY WORDS: Platysma, Neurovasculature, Facial Nerve, Muscle Transfer, Mandible.

Corresponding Author: Dr. Naser A. ElSawy, Department of Anatomy and Embryology, Faculty of Medicine, Zagazig University, Egypt. **ORCID:** 0000-0002-6189-0196

E-Mail: elsawynaser@gmail.com

Access this Article online	Journal Information
Quick Response code 	International Journal of Anatomy and Research ISSN (E) 2321-4287 ISSN (P) 2321-8967 https://www.ijmhr.org/ijar.htm DOI-Prefix: https://dx.doi.org/10.16965/ijar 
	Article Information
	Received: 22 Mar 2026 Peer Review: 28 Mar 2026 Revised: 10 Apr 2026
	Accepted: 09 May 2026 Published (O): 05 June 2026 Published (P): 05 June 2026
DOI: 10.16965/ijar.2026.147	

INTRODUCTION

The platysma is a superficial muscle in the neck that covers the sternocleidomastoid muscle. It has its origin at the pectoral and deltoid muscles and has an insertion point on the clavicle and at the end of the mouth and lower region of the cheek [1]. It is innervated by the cervical branch of facial nerve. The role of the platysma muscle is to draw down and laterally the corner of the

mouth and to open the mouth to a certain extent. Platysma receives a number of arteries as a blood supply. Above the muscle is supplied by the submental branch of the facial artery and below by a branch of the transverse cervical artery. Branches of the superior thyroid artery supply the muscle anteriorly and the posterior cervical triangle supply with the branches of the occipital and posterior auricular arteries [2].

Venous drainage is accomplished through the external jugular vein which is usually located at the posterior part of the muscle [1]. In addition the anterior jugular veins, submental vein and anterior communicating veins also contribute to the venous drainage [3]. The platysma muscle is of a great importance in research due to its role in facial reanimation of people with facial paralysis. Facial paralysis is weakness of the facial muscles as a result of dysfunctional or damaged facial nerve and the most common type is Bell's palsy brought about most likely by a viral infection. Past literature has demonstrated that platysma muscle has been utilized in cheek, parotid, ear [4], tracheoesophageal reconstruction and intra-oral reconstruction. The methods of reanimation can be divided into the static and dynamic ones. The enhancement of the face symmetry is done by the aid of facial soft tissue suspension (static technique) and cross transfer of the facial nerve (primary neuroorrhaphy of the facial nerve), nerve transfer, cross facial nerve grafting and muscle transfer [5]. However, only dynamic techniques provide a functional outcome. Plastic surgery around the orbit is still a challenge to facial reanimation. Previously temporalis was used for dynamic eyelid animation and it was found to provide increased tone of the eyelid but it failed to improve blinking [6]. The other non-invasive methods including the upper eyelid weight loading offered passive lid closure that results in corneal protection. But there is no restoration of blinking. Thus, scientists suggest the platysma muscle as a potential candidate of facial reanimation around the orbit of the eye. The platysma is the best suited as it can be replaced by like tissue with like tissue, it matches well in terms of facial colour and is made of thin layer of muscle [7]. This study attempts to explore the neurovasculature of the platysma, and determine whether there exist a window of the platysma that can be utilized in facial reanimation. Facial paralysis is treated by carrying out facial reanimation procedures. Facial paralysis is an impairment of voluntary motor activity of any of the structures supplied by cranial nerve VII, the facial nerve. The resultant weakness of the musculature of the face impacts verbal communication and oral competence, as well as protection of the cornea, ocular globe and vision [8].

The aetiology of facial paralysis has a number of causes such as congenital facial paralysis (e.g. Moebius syndrome), inflammatory diseases (e.g. Bell's Palsy), traumatic (e.g. iatrogenic damage during parotidectomy), tumours (e.g. Acoustic neuromas) and neuromuscular diseases (e.g. Myasthenia Gravis). The most common acquired facial paralysis is the inflammatory disease, Bell's palsy, a peripheral palsy of the facial nerve that results in muscle weakness on one side of the face. The palsy is believed to have the potential to be caused by herpes simplex virus infection and is caused by inflammation of the facial nerve [9]. Facial reanimation has the potential to enhance facial symmetry, oral competence, eye closure and regain voluntary facial movements. Reanimation techniques can be divided into static and dynamic. The soft tissues of the face are held in a static position to create facial symmetry, correct lagophthalmos and decrease the lower lid laxity [10]. Dynamic techniques, unlike the non-dynamic techniques, offer a functional result. Primary neuroorrhaphy of the facial nerve, nerve transfer, cross facial nerve grafting and muscle transfer (regional or free transfer) are dynamic reanimation techniques [5]. Although primary neuroorrhaphy is the most effective in this case it is not always feasible e.g. in the case of tumour excision, proximal nerve stump removed, or the distal motor plates atrophied. In such cases, it is possible to use muscle transfers. This may be either in the form of regional muscle or free muscle transfer. There are a number of regional muscle transfers, which can be done and result in immediate reanimation [11]. Although there are techniques, like temporalis transfer, to reanimate the mouth and generate a voluntary smile [12]. There are relatively few techniques to reanimate the area around the eye other than some form of static reanimation like weight loading on the upper eyelid. Weight loading of upper eyelid offers passive lift closure and is used in early stages to offer corneal protection to prevent complication like blindness [13]. Although these non-contact methods defend the eye against the aftermaths of facial paralysis, it fails to give a functional result and bring back the blinking of the eye. A variety of other muscles have been used as free muscle transfer since the original description of the first

facial paralysis transfer using the gracilis muscle by Harii in 1976 [14]. The most frequent is the gracilis muscle, pectoralis minor and latissimus dorsi.

MATERIALS AND METHODS

Before the beginning of the study, an approval was taken from Umm Al-Qura University, Saudi Arabi carrying the following number (HAPO-02-K-012-2026-04-3322). In addition, an approval was taken to use 20 cadavers' specimens and jars from Human Anatomy and Embryology department, Zagazig University, Egypt for study the external features of the platysma and its neurovascular supply.

. The platysma was dissected from total 6 old male German cadavers of ages 84 and 88 with no craniofacial abnormalities.

The cadavers were placed in the supine position with the head facing forwards. Both sides were dissected starting with an incision along the midline of the neck, from the mental protuberance to the suprasternal notch. Then, a horizontal incision was made from the mental protuberance following the line of the mandible and finishing behind the lobule. Subsequently, another horizontal incision was made from the suprasternal notch to the acromioclavicular notch, remaining superior to the clavicle. The skin was then reflected posteriorly to reveal the platysma muscle. Next, the platysma was dissected starting from the midline and moving laterally. The platysma was also dissected from the remaining 4 Caucasian old cadavers (mean age at death: 84; range 68-92; 2 females, 2 males; with no craniofacial abnormalities). Both sides of the cadaver were used and dissected in the supine position with the head facing forwards. An incision to the depth of platysma was made along the midline of the neck, from the mental protuberance to the suprasternal notch.

A horizontal incision was made from the mental protuberance to pass to the angle of the mandible and finish behind the lobule, remaining superior to the mandible. A further horizontal incision was made from the suprasternal notch to the acromioclavicular joint, remaining superior to the clavicle. A skin flap was created in the posterior direction to expose the platysma

beneath. Dissection of the platysma then began at the midline moving laterally. At the most superior edge a portion of fascia if necessary was dissected with the platysma to allow for marking of the mental protuberance and angle of the mandible. An incision was made on the platysma at the mental protuberance and the angle of the mandible through which a thread was tied to mark these points for future measuring. The mental protuberance was identified as the depressed centre on either side of the mental tubercles at the midline of the mandible. The measured point on the angle of the mandible was defined as the most inferior and posterior palpable bony edge felt at the angle of the mandible. The inferior border of the platysma was identified and cutted by its connection with the clavicle and surrounding fascia. During reflection of the platysma if a structure was suspected of being a blood vessels or nerve, a coloured thread was attached to either end prior to dissecting the structure so as to allow for vessel tracing and correct identification of the branch's origin to later occur. Following removal of the platysma, calipers were used to measure the shortest distance from the edge of the insertion of each vessel or nerve to the mark of the mental protuberance or angle of the mandible on the platysma. Measurements were also taken to record the distance of the nerve to surrounding vessels.

- (1) Dissection of both sides of the cadaver in the supine position with the head facing forwards.
- (2) Identify mental protuberance and angle of mandible on cadavers.
- (3) An incision on platysma was made along the midline of the neck, from the mental protuberance to the suprasternal notch.
- (4) Dissection of the platysma then began at the midline moving laterally. At the most superior border a fascia was dissected for marking the mental protuberance and angle of mandible.
- (5) The inferior border of the platysma was taken by marking its connection with the clavicle and surrounding fascia.
- (6) Any structure was suspected of being a blood vessels or nerve, a coloured pen was attached to either end prior to dissecting the structure so

as to allow for vessel tracing and correct identification of the branch's origin to later occur.

(7) Measurements were done using calipers to measure the shortest distance from the edge of the insertion of each vessel or nerve to the mark of the mental protuberance or angle of the mandible on the platysma. Measurements were also taken to record the distance of the nerve to surrounding vessels.

RESULTS

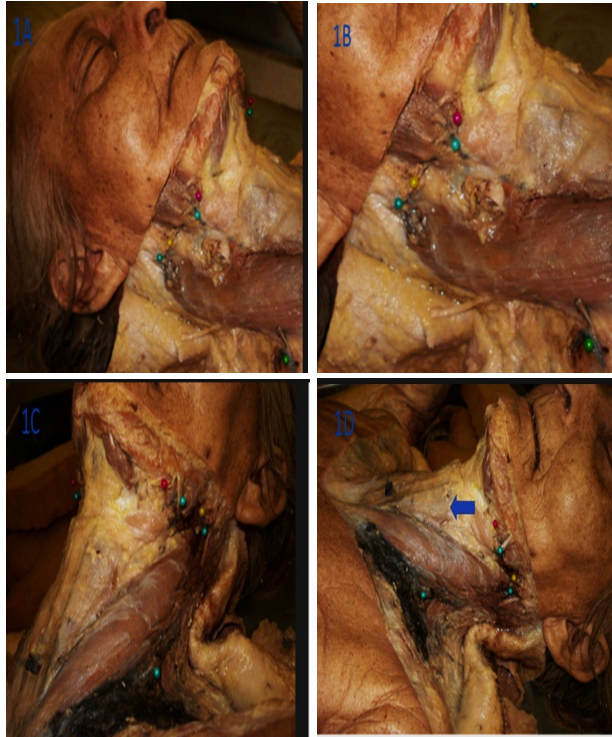

Plate 1 (Figs. A-D): Neck after dissected platysma 1A and 1B right platysma 1C and 1D left platysma.

1- Yellow color pins: cervical branch of the facial nerve
 2- blue color pins: facial vein,
 3- Red color pins: facial artery,
 4- Green color pins: external jugular vein (cut),
 The blue arrow shows the decussation between right and left at the level of thyroid gland

Following removal of the platysma, calipers were used to measure the shortest distance from the edge of the insertion of each vessel or nerve to the mark of the mental protuberance or angle of the mandible on the platysma. Measurements were also taken to record the distance of the nerve to surrounding vessels. **Plate 2 (Figs. A-D)**

2A to 2C- Only one cervical branch of facial supply platysma. 2D- Double branches supply the platysma as one of the variations rather than the common.

During dissection, incisions were made to mark the point of the angle of the mandible (A) and the mental protuberance (B) On this specimen the cervical branch of the facial nerve can be seen at point 1. Point 2 marks the closest venous tributary, a tributary to the facial vein, and point 3 marks the closest arterial branch, a branch of the facial artery. **Plate 2 (Figs. A-D)**

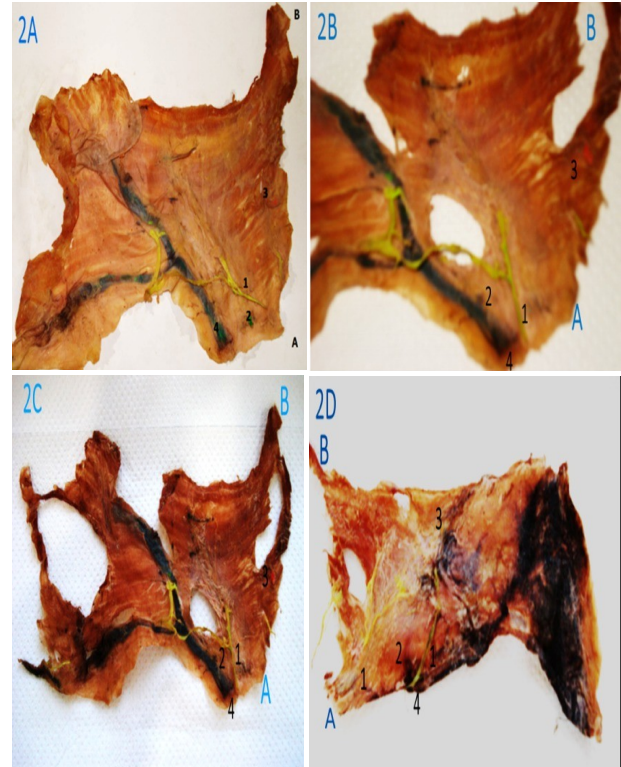


Plate 2 (Figs. A-D): Posterior aspect of dissected platysma: show a dissected left platysma. The specimen was removed from a fresh frozen cadaver and has subsequently been treated in formaldehyde following dissection. A: Angle of mandible. B: mental protuberance, 1: cervical branch of the facial nerve, 2: facial vein, 3: facial artery, 4: external jugular vein (cut),

The upper margin of the external jugular vein, cut and removed with the platysma during dissection, and marked by point 4.

Plate 3 (Figs. A-D) show the corresponding dissected neck to the removed platysma. In this figure the origins of the described vessels can be seen.

On the lateral surface:

- 1-superficial temporal vessels. 2-parotid gland
- 3-parotid duct. 4- Retromandibular vein.
- 6- Branches of the facial nerve.
- 7-internal jugular vein.
- 8- vagus nerve.

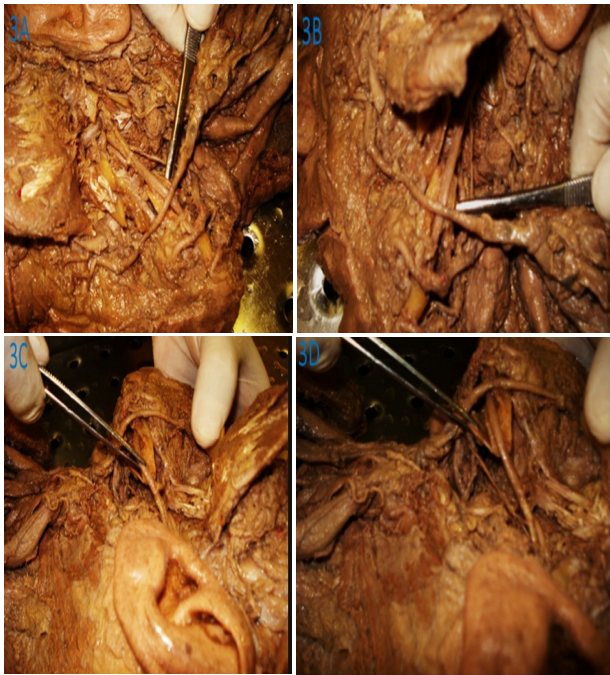


Plate 3 (Figs. A-D): show both an artery and a vein distinguished by differences in shape shows the corresponding dissected neck after the removal of platysma. The forceps show the different origins of the described vessels (external jugular vein and facial artery) On all figures the superior, inferior, medial and lateral parts are labeled as well as mental protuberance and angle of mandible. Multiple numbered are shown on each platysma and these are described in detail in the above figures. Plate 3 (Figs. A-D)




Fig. 4: Sagittal Section Of The Head And Neck from Egyptian cadaver

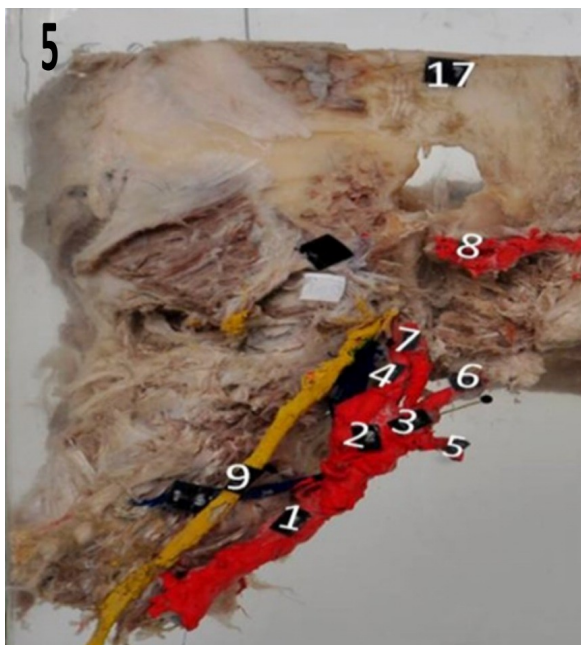


Fig. 5: Sagittal Section Of The Head And Neck from Egyptian cadaver

- 1- Common carotid artery. 2- Carotid sinus.
- 3- External carotid artery. 4- Internal carotid artery.
- 5- Superior thyroid artery.
- 6- Facial artery. Lingual artery is cut (pin inside)
- 7-Ext Carotid artery. 8- Maxillary artery.
- 9- Vagus nerve.

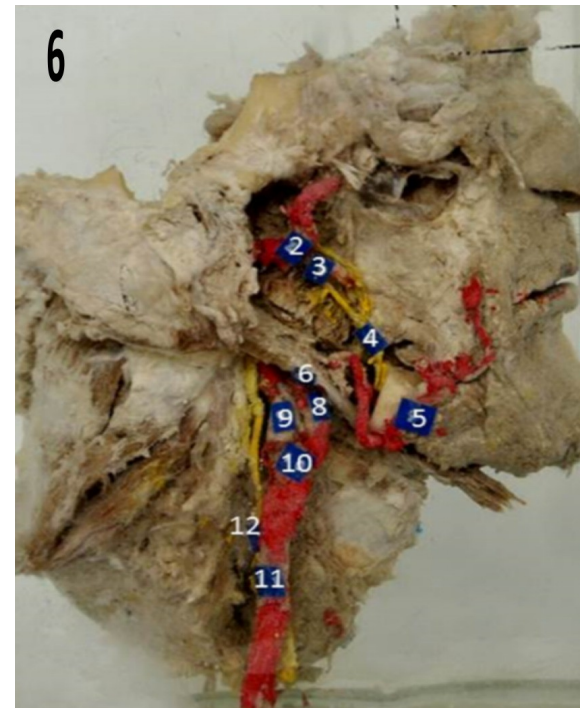


Fig. 6: Sagittal Section Of The Head And Neck from Egyptian cadaver

- 2- Maxillary artery 3-inferior alveolar artery.
- 5-facial artery 6-Post.belly of digastric muscle
- 8-External carotid artery
- 9-internal carotid artery
- 10-Carotid sinus
- 11-common carotid artery
- 12-vagus nerve



Fig. 7: Sagittal Section Of The Head And Neck from Egyptian cadaver Blue arrow show nerve supply to platysma


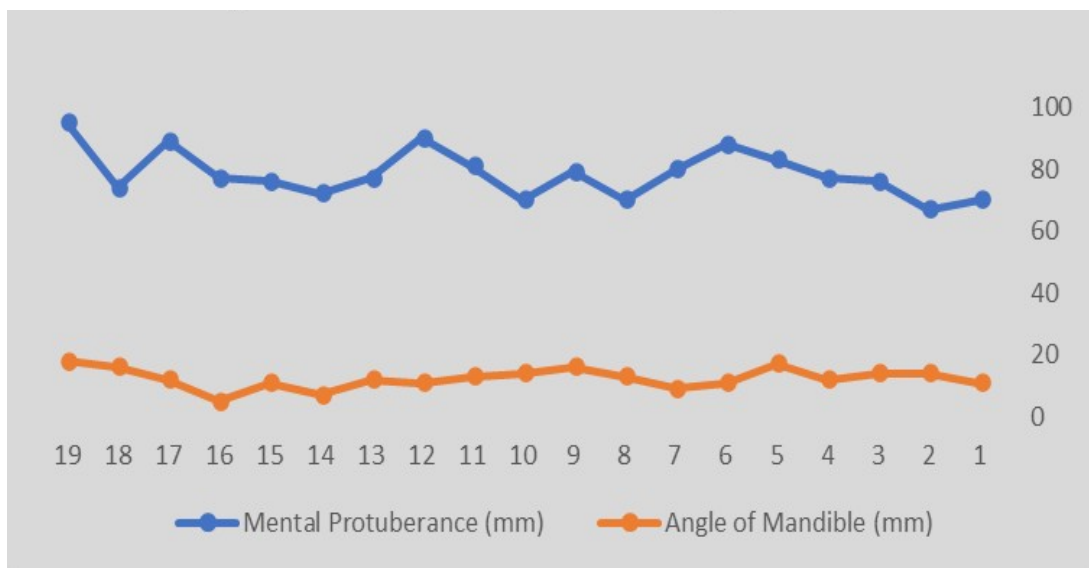


Fig. 8: Sagittal Section Of The Head And Neck from Egyptian cadaver Blue arrow and circle show blood supply to platysma (blue circle)

The results were documented in the same manner across all platysma specimens. In all instances the nerve supply arose from the cervical branch of the facial nerve. In two specimens the nerve branched prior to entry. In these instances, the largest nerve was taken to be the dominant nerve and used for measurements. In one platysma specimen (Cadaver 1, left side) the suspected nerve was not identified during dissection. The specimen was as such invalidated and removed from the results. The identified arterial supply and venous drainage across all specimens is shown in tables 1 and 2:

Cadaver number	Nerve Branch	Angle of Mandible (mm)	Mental Protuberance (mm)
Cadaver 1, Right	Cervical branch of the facial nerve	11	70
Cadaver 1, Left	Cervical branch of the facial nerve	14	67
Cadaver 2, Right	Cervical branch of the facial nerve	14	76
Cadaver 2, Left	Cervical branch of the facial nerve	12	77
Cadaver 3, Right	Cervical branch of the facial nerve	17	83
Cadaver 3, Left	Cervical branch of the facial nerve	11	88
Cadaver 4, Right	Cervical branch of the facial nerve	9	80
Cadaver 4, Left	Cervical branch of the facial nerve	13	70
Cadaver 5, Right	Cervical branch of the facial nerve	16	79
Cadaver 5, Left	Cervical branch of the facial nerve	14	70
Cadaver 6, Right	Cervical branch of the facial nerve	13	81
Cadaver 6, Left	Cervical branch of the facial nerve	11	90
Cadaver 7, Right	Cervical branch of the facial nerve	12	77
Cadaver7, Left	Invalid	x	x
Cadaver 8, Right	Cervical branch of the facial nerve	7	72
Cadaver 8, Left	Cervical branch of the facial nerve	11	76
Cadaver 9, Right	Cervical branch of the facial nerve	5	77
Cadaver 9, Left	Cervical branch of the facial nerve	12	89
Cadaver 10, Right	Cervical branch of the facial nerve	16	74
Cadaver 10, Left	Cervical branch of the facial nerve	18	95
Mean ±Standard deviation		12.421 + 3.167	78.474 +7.486

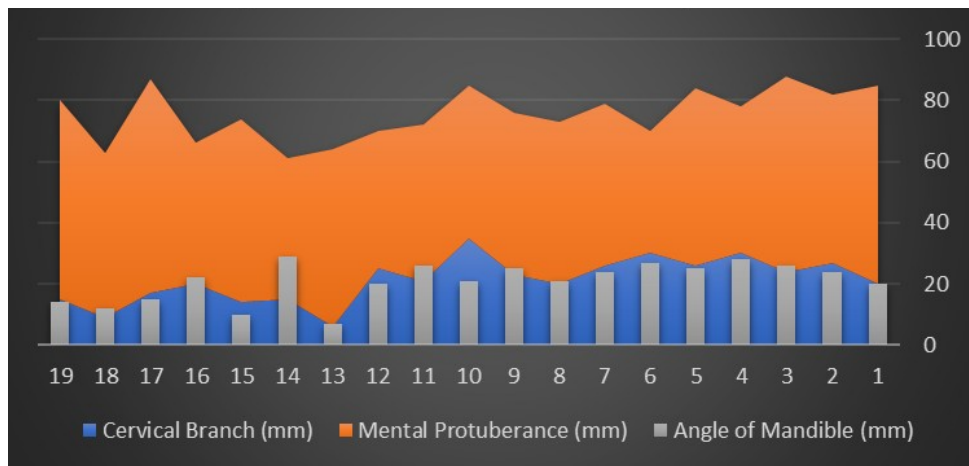
Table 1: The distance of the insertion point of the cervical branch of the facial nerve into the platysma in relation to the angle of the mandible and the mental protuberance can be seen



Graph 1: The distance of the closest arterial branch to the cervical branch of the facial nerve, and its relation to the angle of mandible and the mental protuberance, is displayed:

Table 2: The distance of the closest arterial branch to the cervical branch of the facial nerve, and its relation to the angle of mandible and the mental protuberance, is displayed:

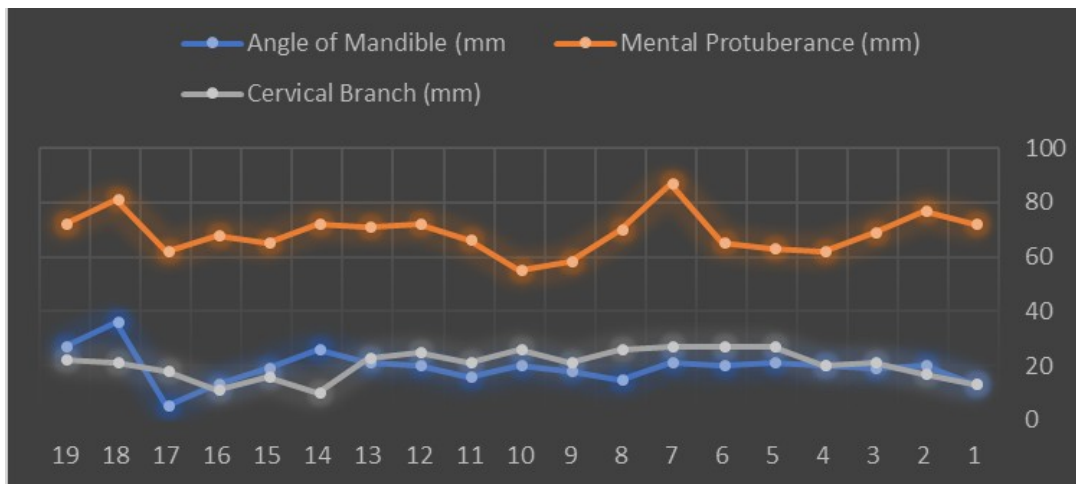
Cadaver number	Closest arterial branch	Angle of Mandible (mm)	Mental Protuberance (mm)	Cervical Branch (mm)
Cadaver 1, Right	Submental artery Facial artery	20	65	20
Cadaver 1, Left	Facial artery	24	55	27
Cadaver 2, Right	Submental artery Facial artery	26	64	24
Cadaver 2, Left	Facial artery	28	48	30
Cadaver 3, Right	Facial artery	25	58	26
Cadaver 3, Left	Facial artery	27	40	30
Cadaver 4, Right	Facial artery	24	53	26
Cadaver 4, Left	Submental artery Facial artery	21	53	20
Cadaver 5, Right	Submental artery Facial artery	25	53	23
Cadaver 5, Left	Facial artery	21	50	35
Cadaver 6, Right	Facial artery	26	51	21
Cadaver 6, Left	Facial artery	20	45	25
Cadaver 7, Right	Submental artery Facial artery	7	58	6
Cadaver7, Left	Invalid	x	x	x
Cadaver 8, Right	Submental artery	29	46	15
Cadaver 8, Left	Facial artery	10	60	14
Cadaver 9, Right	Facial artery	22	46	20
Cadaver 9, Left	Facial artery	15	70	17
Cadaver 10, Right	Submental artery	12	54	9
Cadaver 10, Left	Submental artery Facial artery	14	65	15
Mean + Standard deviation		20.842 + 6.218	54.421+ 7.721	21.211+ 7.186



Graph 2: The distance of the closest arterial branch to the cervical branch of the facial nerve , and its relation to the angle of midible and the mental protuberance

Table 3: The distance of the closest venous tributary to the cervical branch of the facial nerve, and its relation to the angle of mandible and the mental protuberance, is displayed.

Cadaver number	closest venous tributary	Angle of Mandible (mm)	Mental Protuberance (mm)	Cervical Branch (mm)
Cadaver 1, Right	Facial vein	13	72	13
Cadaver 1, Left	Facial vein	20	77	17
Cadaver 2, Right	Facial vein	19	69	21
Cadaver 2, Left	Facial vein	20	62	20
Cadaver 3, Right	Facial vein, Central vein, External jugular vein, Anterior jugular vein	21	63	27
Cadaver 3, Left	Facial vein	20	65	27
Cadaver 4, Right	Facial vein, Anterior Jugular vein	21	87	27
Cadaver 4, Left	Facial vein, Central vein, External jugular vein	15	70	26
Cadaver 5, Right	Facial vein	18	58	21
Cadaver 5, Left	Facial vein	20	55	26
Cadaver 6, Right	Facial vein, Central vein, External jugular vein	16	66	21
Cadaver 6, Left	Facial vein	20	72	25
Cadaver 7, Right	Central vein, External jugular vein, Suprascapular vein	21	71	23
Cadaver7, Left	Invalid	x	x	x
Cadaver 8, Right	Facial vein, Central vein, External jugular vein, Anterior jugular vein	26	72	10
Cadaver 8, Left	Facial vein, Central vein, External jugular vein	19	65	16
Cadaver 9, Right	Central vein	13	68	11
Cadaver 9, Left	Facial vein, Central vein, External jugular vein	5	62	18
Cadaver 10, Right	Facial vein, Central vein, External jugular vein	36	81	21
Cadaver 10, Left	Facial vein, Anterior Jugular vein	27	72	22
Mean + Standard deviation		19.474+ 6.107	68.789+ 7.487	20.631+ 5.193



Graph 3: The distance of the closest venous tributary to the cervical branch of the facial nerve, and its relation to the angle of mandible and the mental protuberance

DISCUSSION

Subcision is mentioned to be an effective cure to atrophic acne scars especially the rolling type in the lower face and neck [15]. Past researches indicate that the most optimal skin levels to carry out subcision are in the deep dermis levels and at the dermosubcutaneous junction. A rounded blade appears to be a better choice because of the less likely occurrence of un-intentional movement to either too shallow or too deep of the skin [16]. One of the serious issues in large scale subcision of such levels is the fact that one can disrupt the Neurovasculature of platysma muscle which are stable fibromuscular strands that connect the fascia to the dermis. These important structures act as steady supports to adhere the skin and superficial fascia (i.e, the superficial muscular aponeurotic system) to provide facial stability and expression [17]. Suggested that physician must, first of all, possess a thorough knowledge of anatomy and the exact location of the Neurovasculature of platysma muscle. Selecting the correct entry points and directions to avoid detaching these important structures. Choosing an insertion point in front of the sideburns to approach the scars in all medial cheek and buccal areas may lead to facial sagging [18]. There are some concerns about vascular and neural injury in this procedure, particularly in the marginal mandibular, based on the fact that the main vascular and neural trunks are located beneath the superficial muscular aponeurotic system as during the procedure, aggressive

insertion and motion of the needle/blade in the previously mentioned skin levels may rupture Neurovasculature of platysma muscle and subsequently cause facial sagging. Therefore, it can give an aged look to young patients who undergo treatment to remove acne scars, especially after a series of treatment [19].

The clinical significance of this research study is another argument in favor of a flap of the platysma muscle which is more suitable in the upper face and in the neck as far as facial reanimation is concerned. The thickness of the platysma muscle resembles orbicularis oculi muscle and this had been the reason behind the hypothesis that platysma could be used to develop reanimation methods to enable restoration of functions around the eye [20]. A process such as this would entail an incision of a small area of the platysma to the extent of anchoring it to the temporalis fascia as well as to the superior and inferior areas of orbicularis oculi. Therefore, when the muscle contracts it would drag the eye back and shut it. As per our results, number of structures supplying platysma muscle in both sides (tables 1-4) and even between cadavers is different. Such variations reaffirm that human difference is incredible. The platysma muscle varies with individuals and cadaver 1 is a great example to prove this conclusion [11]. Although the two muscles may be of similar shape, the size difference is notable.

Furthermore, it was concluded that the platysma of some cadavers is supplied by a greater number of structures than the others

as mention in the tables from 1 to 4 and possibly the difference in size contributes to this observation since the larger the platysma the more vessels were found. Thus, the sum of the number of vessels and nerves is proportional to the size of the platysma. The other conclusion is that the left and right side of each cadaver does not show any pattern of difference [21]. Thus, based on our results there is no constant relationship that determines whether one side supplied by more vessels than the other. The difference is also observed between the platysma of one and the other cadaver (Tables 1-4). In addition, the fact that more veins than arteries supply both the platysma muscles show that there is more venous drainage in the platysma muscle. Additionally, the main venous drainage was the external jugular, with submental as a second. Moreover, this research adds to the evidence of the earlier research, which has concluded that the superior region is fed by submental artery [22]. The vessels and nerves were found to be distributed over most of the platysmas but yet the distribution is still different on each side and on each cadaver. The cadavers used in this study did not have any particular window of the platysma muscle. Thus, our study suggests that a muscle section that is supplied by both nerves and vessels can be taken from anywhere on the platysma for a graft around the eye. It may be applied to either the static or dynamic reanimation but a more appropriate method is the dynamic reanimation technique [23].

In dynamic reanimation the blood vessels can be attached to a branch of the superficial temporal artery and the nerves could be attached by a cross facial nerve graft, in patients with paralysis on one side of the face. The circulation of the platysma in all cases was by a branch of either the facial or submental arteries. This is in line with existing literature that explains the arterial supply to the platysma to be originated mainly by the submental and facial arteries [2]. The venous drainage of the platysma was more variable. The central vein was the most common tributary with tributaries draining (70%) of specimens. Following this, the facial vein and external jugular vein were found to drain (23%)

of specimens. The anterior jugular vein was a minor drain (6% of specimens) but the suprascapular vein occurred just once (1%) [2]. discovered that the venous drainage was mainly through branches of the external jugular vein. The posterior part of platysma is reported to be drained by the external jugular vein and the anterior part of platysma is reported to be drained by the facial and anterior jugular veins [3]. Still other vessels have been mentioned to help supply and drain the platysma such as the submental vein, thyroid vein, suprascapular and transverse cervical vein, the superior thyroid, occipital and supraclavicular arteries. It is likely that some of these vessels were not seen in this study due to the small samples size and variability of the blood vessels. Table 1-3 shows the mean \pm standard deviation of the entry point of the cervical branch of the facial nerve, the closest supplying artery and draining vein in relation to the angle of the mandible, the mental protuberance and each other [24]. In the vast majority (71%) of the specimens the nearest arterial supply was seen to originate in the facial artery with the rest 29% of the specimens having their origin in the submental. On the same note, the venous drainage was observed in most specimens (71%), to drain in the facial vein with the other (29%), draining in the central vein [25]. All these vessels were located near the cervical branch of the facial nerve. These findings demonstrate that there is a window in the neck through which one can obtain the innervated platysma muscle that can be used in the process of facial reanimation. A small piece of platysma muscle would be necessary in order to have a reanimation procedure around the orbit. A piece of platysma, 40mm x 50mm, would be excised to expose enough muscle to fix to both the temporalis fascia as well as fix to both superior and inferior parts of orbicularis oculi, using a partially bisected trouser graft. On contraction, the muscle would pull backwards and close the eye [3].

The superficial temporal branches would be connected to the blood vessels of platysma and the nerve of platysma connected to an ipsilateral one of the facial nerves, or a cross

facial nerve graft. A 40mm x 50mm (40mm better/worse, 50mm medial/lateral) section, sampled at the angle of the mandible would be adequate to contain the nervous supply, arterial supply and venous drainage according to the values mentioned in this study [25]. This part of the muscle would use the facial or submental artery and either the facial or central vein. This is because they are very near to the cervical branch of the facial nerve and at least one of such arteries/veins is present in all specimens. The biggest hindrance in the study was the constraints in the number of cadavers. Further work to study the transplantation point around the orbit would be useful in identifying the ideal blood vessels for transplantation based on their location as well as local availability of nerve branches to determine the need for a cross facial nerve graft.

CONCLUSION

There are close proximity to the cervical branch of the facial nerve and the blood vessels of platysma would be attached to the superficial temporal branches and the nerve of platysma attached to an ipsilateral branch of the facial nerve. The slender muscle, pectoralis minor, and latissimus dorsi are among the most frequently used muscles

ACKNOWLEDGEMENTS

The authors extend their sincere thanks and appreciation to the Deanship of Scientific Research and Graduate Studies at Umm Al-Qura University for funding this work through a research project under approval number (HAPO-02-K-012-2026-04-3322).

Conflicts of Interests: None

REFERENCES

- [1]. Baur, D et al. The posteriorly based platysma flap in oral and facial reconstruction. *Journal of Oral and Maxillofacial surgery*. 2002;60(10):1147-1150. <https://doi.org/10.1053/joms.2002.34989> PMID:12378489
- [2]. Uehara M. Helman JI. Lillie JH. Brooks SL. Blood supply to the platysma muscle flap: an anatomic study with clinical correlation. *Journal of Oral & Maxillofacial Surgery*. 2001;59(6):642-656. <https://doi.org/10.1053/joms.2001.23389> PMID:11381387
- [3]. Agarwal A. Schneck CD. Kelley DJ. Venous drainage of the platysma myocutaneous flap. *Otolaryngology - Head & Neck Surgery*. 2004;130(3):357-369. <https://doi.org/10.1016/j.otohns.2003.12.005> PMID:15054379
- [4]. Puxeddu R. Dennis S. Ferreli C. Caldera S. Brennan PA. Platysma myocutaneous flap for reconstruction of skin defects in the head and neck. *British Journal of Oral & Maxillofacial Surgery*. 2008;46(5):383-6. <https://doi.org/10.1016/j.bjoms.2007.11.015> PMID:18207614
- [5]. Falcioni M. Taibah A. Russo A. Piccirillo E. Sanna M. Facial nerve grafting. *Otology & Neurotology*. 2003;24(3):486-499. <https://doi.org/10.1097/00129492-200305000-00022> PMID:12806304
- [6]. Boahene K. Reanimating the paralyzed face. *F1000Prime Rep*. 2013 Nov 1;5:49. <https://doi.org/10.12703/P5-49> PMID:24273650 PMCID:PMC3816764
- [7]. Neil, A et al. Use of innervated platysma flap in facial reanimation. *Annals of plastic surgery*. 1995;34(3):326-330. <https://doi.org/10.1097/00000637-199503000-00018> PMID:7598393
- [8]. Evans AK. Licameli G. Brietzke S. Whittemore K. Kenna M. Pediatric facial nerve paralysis: patients, management and outcomes. *International Journal of Pediatric Otorhinolaryngology*. 2005; 69(11): 1521-8. <https://doi.org/10.1016/j.ijporl.2005.04.025> PMID:15985298
- [9]. Yeo SG. Lee YC. Park DC. Cha CI. Acyclovir plus steroid vs steroid alone in the treatment of Bell's palsy. *American Journal of Otolaryngology*. 2008; 29(3):163-6. <https://doi.org/10.1016/j.amjoto.2007.05.001> PMID:18439948
- [10]. Vlastou C. Facial paralysis. *Microsurgery*. 2006;26(4):278-87. <https://doi.org/10.1002/micr.20240> PMID:16628742
- [11]. Tate JR. Tollefson TT. Advances in facial reanimation. *Current Opinion in Otolaryngology & Head & Neck Surgery*. 2006;14(4):242-253. <https://doi.org/10.1097/01.moo.0000233594.84175.a0> PMID:16832180
- [12]. Erni D. Lieger O. Banic A. Comparative objective and subjective analysis of temporalis tendon & microneurovascular transfer for facial reanimation. *British Journal of Plastic Surgery*. 1999;52(3): 167-72. <https://doi.org/10.1054/bjps.1997.3060> PMID:10474465
- [13]. Seiff SR. Carter SR. Facial nerve paralysis. *International Ophthalmology Clinics*. 2002;42(2):103-112. <https://doi.org/10.1097/00004397-200204000-00010> PMID:11914707

- [14]. Harii K. Ohmori K. Torii S. Free gracilis muscle transplantation, with microneurovascular anastomoses for the treatment of facial paralysis. A preliminary report. *Plastic & Reconstructive Surgery*. 1976;57(2):133-43.
<https://doi.org/10.1097/00006534-197602000-00001>
PMid:1250883
- [15]. Kravvas G, Al-Niaimi F. A systematic review of treatments for acne scarring. Part 1: non-energy-based techniques. *Scars Burn Heal*. 2017; 3:2059513117695312.
<https://doi.org/10.1177/2059513117695312>
PMid:29799567 PMCID:PMC5965325
- [16]. Gheisari M, Iranmanesh B, Saghi B. Blunt cannula subcision is more effective than Nokor needle subcision for acne scars treatment. *J Cosmet Dermatol* 2019;18(1):192-196.
<https://doi.org/10.1111/jocd.12523>
PMid:29524284
- [17]. Alghoul M, Codner MA. Retaining ligaments of the face: review of anatomy and clinical applications. *Aesthet Surg J*. 2013;33(6):769-782.
<https://doi.org/10.1177/1090820X13495405>
PMid:23855010
- [18]. Lee S-Y, Sung K-Y. Subcision: an ancillary procedure to face-lift operation to improve prominent nasolabial folds. *Arch Plast Surg*. 2013;19(2):120-124.
<https://doi.org/10.14730/aaps.2013.19.2.120>
- [19]. Howaldt HP, Bitter K. The myocutaneous platysma flap for the reconstruction of intraoral defects after radical tumor resection. *Journal of Cranio-Maxillo-Facial Surgery*. 1989;17(5):237-240.
[https://doi.org/10.1016/S1010-5182\(89\)80076-9](https://doi.org/10.1016/S1010-5182(89)80076-9)
PMid:2760228
- [20]. Szudek J, Taylor SM. Systematic review of the platysma myocutaneous flap for head and neck reconstruction. *Archives of Otolaryngology — Head & Neck Surgery*. 2007;133(7):655-661.
<https://doi.org/10.1001/archotol.133.7.655>
PMid:17638777
- [21]. Friedman M, Schild JA, Venkatesan TK. Platysma myocutaneous flap for repair of hypopharyngeal strictures. *Annals of Otolaryngology, Rhinology & Laryngology*. 1990;99(12):945-450.
<https://doi.org/10.1177/000348949009901203>
PMid:2244726
- [22]. Lazaridis N, Dimitrakopoulos I, Zouloumis L. The superiorly based platysma flap for oral reconstruction in conjunction with neck dissection: a case series. 2007;65(5):895-900.
<https://doi.org/10.1016/j.joms.2006.06.296>
PMid:17448839
- [23]. Dadkhahfar S, Robati RM, Gheisari M, Moravvej H. Subcision: indications, adverse reactions, and pearls. *J Cosmet Dermatol*. 2020;19(5):1029-1038.
<https://doi.org/10.1111/jocd.13308>
PMid:31990113
- [24]. Cartier C, Jouzdani E, Garrel R, Makeieff M, Crampette L, Guerrier B. Study of the platysma coli muscle vascularisation by the facial artery. Implication during the elevation of the musculo-cutaneous platysma coli muscle flap. *Rev Laryngol Otol Rhinol*. 2009;130(3):139-144.
- [25]. Harpf, C, Papp, H, Maurer, J, Thurner. Reconstruction of the lower lip with the myocutaneous platysma flap. *Eur J Plast Surg* 1992;15:296-299.
<https://doi.org/10.1007/BF00212185>
- [26]. Posnick JC, McCraw JB. Reconstruction of the chin-lower cheek complex with a platysma myocutaneous flap. *Journal of Oral & Maxillofacial Surgery*. 1988; 46(2):152-5.
[https://doi.org/10.1016/0278-2391\(88\)90270-4](https://doi.org/10.1016/0278-2391(88)90270-4)
PMid:3422282

How to cite this article:

Naser A. ElSawy, Abdullah G. Al-Kushi, Naief A Dahran, Reham M Filfilan, Nada Mohamed Mohamed Soliman, Mohammed A. S. Amin. Demonstration of the Neurovasculature of the Platysma Muscle and Its Role in Facial Reanimation. *Int J Anat Res* 2026;14(2):9546-9558. DOI: 10.16965/ijar.2026.147