

Case Report

Hepatopancreatic Anomaly with its histomorphological study in Adult Cadaver

Jeneeta baa.

* Assistant Professor, Department of Anatomy, Veer Surendra Sai Institute of Medical Sciences and Research (VIMSAR), Burla, Orissa, India.

ABSTRACT

The pancreas is a soft, lobulated and mixed gland. As the liver and pancreas develop together from the hepatopancreatic bud it is common that congenital anomalies of liver and pancreas exist together. This study was done during routine practical dissection where a band of tissue was found extending from the head of the pancreas to the root of the Mesentery. On histological examination the tissue was confirmed to be pancreas. It is seen that the hepatic bud grows at the expense of the ventral pancreas. In the present study, we found an atrophied left lobe of liver and an abnormally rare and large uncinat process of pancreas.

KEY WORDS: Uncinate Process, Pancreas, Hepatopancreatic Bud, Accessory Lobe.

Corresponding Author: Dr jeneeta Baa, Assistant Professor, Department of Anatomy, Veer Surendra Sai Institute Of Medical Sciences And Research, Burla, Orissa, India.

E-Mail: drjeneetabaa@gmail.com

Access this Article online	Journal Information
Quick Response code  DOI: 10.16965/ijar.2022.295	International Journal of Anatomy and Research ISSN (E) 2321-4287 ISSN (P) 2321-8967 https://www.ijmhr.org/ijar.htm DOI-Prefix: https://dx.doi.org/10.16965/ijar 
	Article Information
	Received: 22 Nov 2022 Peer Review: 24 Nov 2022 Revised: 25 Jan 2023
	Accepted: 02 Feb 2023 Published (O): 26 Feb 2023 Published (P): 05 Mar 2023

INTRODUCTION

The pancreas is a soft and lobulated gland, which measures about 12-15 cm extending from the duodenum to the spleen in the lesser sac of the peritoneum. It is divided into head with its uncinat process, neck, body and tail. Congenital anomalies of the pancreas are common and manifests in many ways ranging from abdominal pain to pancreatitis. Though they are incidentally detected but they are sometimes surgically corrected, so surgeons must be familiar about their anatomical knowledge and occurrence.

MATERIALS AND METHODS

This histomorphological study was conducted on a band of tissue, which was found in the infra-colic compartment, in a 65 years old male cadaver. This unidentified tissue was long,

ribbon-like, approximately 12cm long and 3cm wide extending from the head of the pancreas on the right to the posterior abdominal wall on the left side of the midline (figure1). Proximally, it was continuous with the head of the pancreas and distally it blended with the root of the Mesentery near the duodenojejunal junction. The superior mesenteric vessels were related anterior to the said structure. To confirm the nature of the tissue we did a histological study. Few samples of the tissue were processed and embedded in paraffin wax by routine method. Sections were cut at 4-6um thickness, stained in hematoxylin and eosin and studied under microscope in different magnifications.

OBSERVATIONS

The band of tissue that was obtained from the cadaver was found to be a pancreatic tissue

on H&E staining (figure 2). Serous acini were seen with their duct system. Plenty of pancreatic islets were also seen scattered between the acini.

As the liver and pancreas develop together from the hepatopancreatic bud, we searched for any abnormality in the development of the liver. In our study, the left lobe was atrophied, from the apex of which a long fibrous band extended towards the left up to the diaphragm (fibrose appendix of the liver) (figure 3). The porta-hepatis was situated close to the posterior surface and was so narrow that it led to the crowding of the structures passing through it. The posterior shift of the porta hepatis resulted in decreased size of the caudate lobe and a reciprocal increase in size of the quadrate lobe. The caudate lobe was rudimentary in size whereas the quadrate lobe was large and irregular with a tongue like accessory lobe projecting from its lower part. There was absence of the fissure for ligamentum teres hepatis because a mass of liver tissue (pons hepatis) bridged the fissure, as a result of which the lesser omentum was attached to the entire inferior surface at the site of the quadrate lobe. This also resulted in the absence of an epiploic foramen. An abnormal band of peritoneum extended from the fundus of the gall bladder to the transverse colon (cysto-colic ligament), due to which the gall bladder was horizontally placed in its fossa (figure 4).

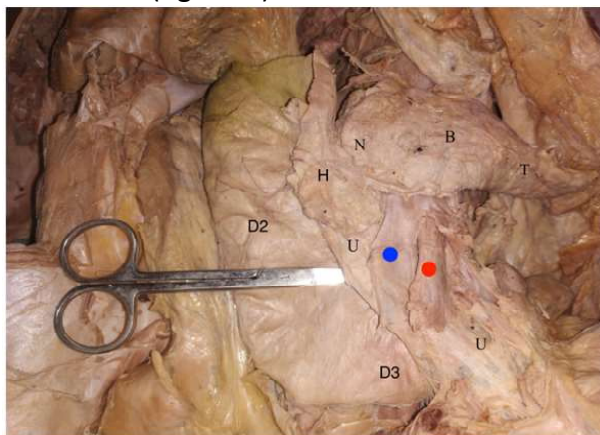


Fig. 1: Pancreas with an unusually long uncinata process in the C-shape curvature of duodenum.

D2-second part of duodenum, D3-Third part of duodenum, U-uncinate process, H-head of pancreas, N-neck of pancreas, B-body of pancreas, T-tail of pancreas, Blue dot - Superior mesenteric vein, Red dot -superior mesenteric artery.

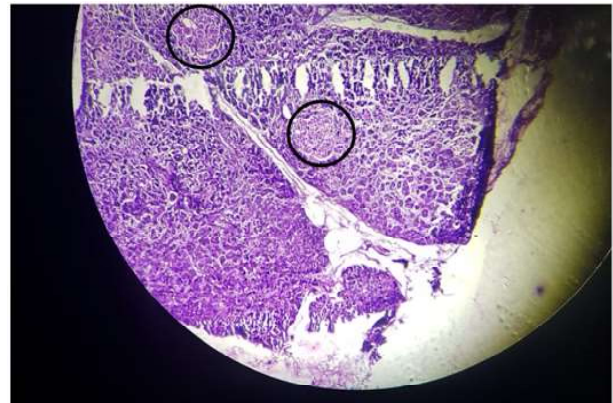


Fig. 2: The pancreatic tissue on 4x resolution and H&E staining showing serous acini in lobules with plenty of islets of langerhans (black circle) scattered between the acini.

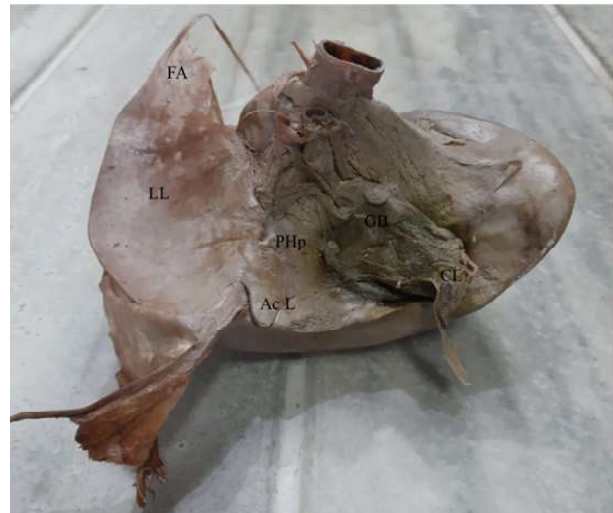

Fig. 3: Picture showing both the anatomical lobes of liver.

LL -Atrophied left lobe of liver, FA- fibrose appendix of the liver, Ac L-Accessory lobe, PHp-pons hepatis, GB-gall bladder

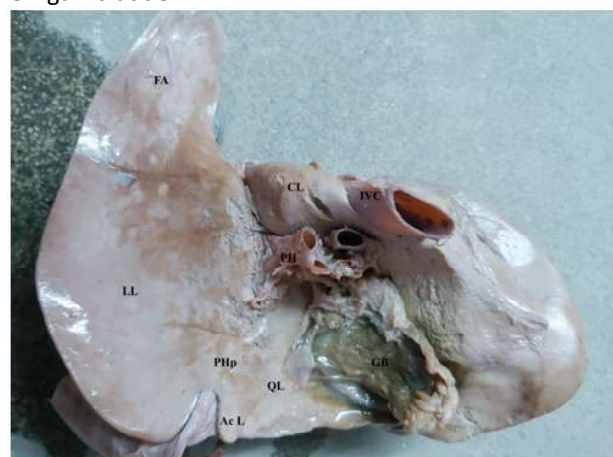


Fig. 4: Liver and Gall bladder in-situ GB-gall bladder, CL-cystocolic ligament, Cm-caecum, AC-ascending colon, TC-transverse colon.

DISCUSSION

At about 4th week of gestation the pancreas first appears as two diverticula arising from

the junction of the foregut and midgut. The pancreatic tissue develops under the influence of pancreas and duodenal homeobox gene [1]. The two buds of pancreatic tissue are expanded by the activation and deactivation of sonic hedgehog signaling. The ventral bud of endodermal tissue is formed in the ventral mesentery and the larger cluster of endoderm forms the dorsal pancreatic bud within the dorsal mesentery. The dorsal bud elongates rapidly to form the tail, body and part of the head of the pancreas. The ventral bud is initially a paired structure, the left portion of which atrophies and the right portion grows and is pulled posteriorly as the duodenum rotates. Around the 6th week of gestation the persistent part of ventral primordium fuses with the dorsal pancreatic bud to form the remainder of the head and uncinete process of pancreas [1].

The parenchyma develops from branching of endodermal pancreatic buds into the surrounding mesoderm. Because of their different surrounding tissues, different signals induce dorsal and ventral pancreatic buds. The dorsal pancreatic endoderm lies in close proximity to the dorsal aorta, the endothelium of which provides inductive signals to the dorsal endoderm, inducing the formation of a pancreatic bud expressing Pdx1 and Ptf1a [2]. Signals from lateral plate mesoderm (retinoic acid) and notochord (FGF2 and activin) are required for dorsal bud induction. In contrast, FGF signaling from cardiac mesoderm inhibits ventral pancreatic bud specifications [3].

Thereafter the morphogenesis of the two buds are different. Unlike the dorsal pancreas the ventral pancreas is not dependent on inducers from the endothelium.

The ventral pancreatic bud develops in close connection with the liver, the later receives instructive signaling from the cardiac mesoderm [4]. The function of Pdx1 and Ptf1a together with Hnf1b is essential for the formation of ventral pancreas [5].

It is seen that the hepatic bud grows at the expense of the ventral pancreas. In the present study, we found an atrophied left lobe of liver and an abnormally large uncinete process of

pancreas. In intrauterine life, the fetal portal vein joins the umbilical vein in a smooth right-hand curve, maintained after birth, with a sharp angle between the portal trunk and its left branch; the left vascular lobe may therefore be at a circulatory disadvantage and unable to keep pace in growth with the right lobe. At the left end of the adult left lobe a fibrous band (fibrose appendix of the liver) may appear as an atrophied remnant of a more extensive part of the left lobe as children [6]. Accessory pancreatic tissue may be scattered in the wall of an organ, and hence recognizable only on microscopic examination, or may form masses of appreciable size as reported by Reitmann which was 2cm long and 1cm or broader [7]. In our case, the tissue was much longer and such a large diffuse pancreatic tissue is not documented in literature. We concluded it to be an enlarged uncinete process owing to its relation with the superior mesenteric vessels which crossed anterior to it. We found another such case in literature where an unusual and extensive uncinete process was reported [8]. There is lack of documentation of such congenital pancreatic anomaly and despite of the advanced diagnostic techniques, such anomalies of the pancreas still remain unnoticed. The cause of a pancreatic hypertrophy can be either congenital or acquired [9]. After staining, the tissue was confirmed to be a normal pancreas tissue. Such rare congenital conditions must be borne in mind during surgery on hepatopancreatic -biliary tree.

CONCLUSION

Congenital abnormality in the hepatopancreatic bud can manifest in various forms. This study may help the surgeons to be aware of such anomalies to avoid any accidents.

ORCID : 0000-0002-1618-3580

Conflicts of Interests: None

REFERENCES

- [1]. Moore KL, Persaud TV. The developing human: clinically oriented embryology. 8th ed. Philadelphia: Saunders 2008; 264-265..
- [2]. Lammert et al., 2001. Induction of Pancreatic differentiation by signals from blood vessels. *Science* 294,564-567. 2001 Oct 19;294(5542):564-7. <https://doi.org/10.1126/science.1064344>.

- [3]. Kumar et al. Signals from lateral plate mesoderm instruct endoderm towards pancreatic fate. *Dev.Biol.* 2003;259,109-122. [https://doi.org/10.1016/S0012-1606\(03\)00183-0](https://doi.org/10.1016/S0012-1606(03)00183-0)
- [4]. Yoshitomi, H. Endothelial cell interactions initiate dorsal pancreas development by selectively inducing the transcription factor Ptf1a. *Development* 2004;131:807-817. <https://doi.org/10.1242/dev.00960>
- [5]. Hammarite et al. Lack of TCF2/v HNF1 in mice leads to pancreas. *Proc. Natl. Acad. Sci. USA* 2005;102:1490-1495. <https://doi.org/10.1073/pnas.0405776102>
- [6]. Standring S. *Gray's Anatomy*. 38th edition. Churchill Livingstone 2008; 1803.
- [7]. Reitmann, K. Zwei Falle von accessorischem Pankreas. *Anat. Anz.* 1903;23:155.
- [8]. Histomorphological Study of Unusual and Extensive Uncinate Process of Pancreas Encircling the Superior Mesenteric Artery and its Clinical Importance. *JOP* 2016; 17(3):281-283.
- [9]. Nayak S, Pamidi N, George BM, Guru A. A strange case of double annular pancreas. *JOP* 2013;14:96-98. [PMID: 23306345] <https://doi.org/10.6092/1590-8577/1281>

How to cite this article:

Jeneeta baa. A Case Report on Hepatopancreatic Anomaly with its histomorphological study in Adult Cadaver. *Int J Anat Res* 2023;11(1):8579-8582. **DOI:** 10.16965/ijar.2022.295