International Journal of Anatomy and Research,
Int J Anat Res 2023, Vol 11(1):8550-58. ISSN 2321-4287
DOI: https://dx.doi.org/10.16965/ijar.2022.276

Original Research Article

Prevalence of Palmaris Longus Muscle Agenesis Among Students Assessed Using Various Clinical Assessment Tests

Yaseen Ahmed Wafa [*1,2], Maher Abumosamah [1], Qais Gasibat [3,4].

[*1] Lecturer, Department of Anatomy, MAHSA University, Bandar Saujana Putra, 42610 Jenjarom, Selangor, Malaysia.

[*2] Lecturer, Department of Anatomy, Faculty of Medicine, Misurata University, Misurata, Libya

[3] Senior Physiotherapist, Department of Sport Studies, University Putra Malaysia UPM, 43400 UPM Serdang Selangor, Malaysia.

[4] Senior Physiotherapist, Department of Physiotherapy, College of Medical Technology, Misurata, Libya.

ABSTRACT

Introduction: Since the lack of Palmaris Longus Muscle (PLM) has no effect on hand and wrist function, it is considered a non-essential muscle. However, its clinical relevance stems from its widespread application in reconstructive and hand surgery. In addition to gender differences, some sources assert that its absence is more prevalent in those genders who lack it in some way, that it is more prevalent when both eyes are missing, and that it is more prevalent when just one eye is present.

Aim: The primary objective of this research was to find out how common PLM agenesis is among students of both genders. The secondary objective was to demonstrate that a classical test (Schaffer's test) can be reliably compared to other tests such as Thompson's test, Mishra's test, AIIM's test, and the Hiz-Ediz test.

Materials and Methods: The study was a cross-sectional study carried out at the MAHSA University; A total of 224 cases, comprised of 126 (56.3%) females and 98 (43.8%) males. Each participant was requested to perform five clinical tests namely, Schaeffer's test, Thompson's test, Mishra's test, AIIM's test, and the Hiz-Ediz test.

Results: The frequent agenesis of the palmaris longus in the right forearm of our study with the Schaeffer's test was (20.5%) and Thompson's and Hiz-Ediz tests had equal percentages of agenesis (22.3%) while Mishra's test (22.8%), and AIIMs test (29.5%) of the participants. Moreover, Thompson's test had the highest percentage of (70.5%) compared to other tests for detecting the presence of PLM in the left forearm. The second nearest test for PLM detection was Schaeffer's test with a percentage of (67.4%). AIIMs test was able to detect PLM in (64.3%) of the participants and Mishra's test and Hiz-Ediz tests had close percentages of (59.4%) and (57.6%) respectively for PLM detection.

Conclusion: It can be concluded that Thompson's test had a higher percentage among the tests to detect the presence of the PLM tendon in females while Schaeffer's test was more significant in males. Thompson's test had the best accuracy level and the highest percentage level of agreement with Schaeffer's test compared to the other tests.

KEY WORDS: Palmaris Longus Muscle; Agenesis; Schaeffer's Test, Anatomical Variation, Forearm.

Corresponding Author: YASEEN AHMAD WAFI., MBBS., M.SC [*1] Lecturer, Department of Anatomy, MAHSA University, Bandar Saujana Putra, 42610 Jenjarom, Selangor, Malaysia.
E-Mail: ybenwafa@gmail.com

Access this Article online	Journal Information
Quick Response code	**International Journal of Anatomy and Research** ISSN (E) 2321-4287 | ISSN (P) 2321-8967 **https://www.ijmhr.org/ijar.htm** **DOI-Prefix:** https://dx.doi.org/10.16965/ijar
DOI: 10.16965/ijar.2022.276	**Article Information** Received: 19 Oct 2022 Accepted: 08 Dec 2022 Peer Review: 22 Oct 2022 Published (O): 26 Feb 2023 Revised: 12 Nov 2022 Published (P): 05 Mar 2023

INTRODUCTION

The Palmaris Longus Muscle (PLM) is a thin muscle that arises from the medial epicondyle via the common flexor tendon and adjacent intermuscular septa [1,2]. The long tendon of this muscle, which originates in the anterior flexor retinaculum, is superficially positioned in the anterior compartment of the forearm [3]. The tendon travels deeply to the flexor retinaculum, passing deep and slightly medial to this nerve [4,5]. A few fibres detach from the tendon and intertwine with the transverse fibres of the retinaculum. The tendon makes a flat plate insertion into the palmar aponeurosis after crossing the retinaculum [6]. The short tendon and long body of this muscle are distinctive features [3]. When looking for the median nerve at the wrist, the PLM tendon can be a good landmark [7].

Plastic surgeons utilise the PLM in the restoration of upper lip defects [8, 9], lower lip and chin defects [10], as frontalis suspension surgery for ptosis correction [11], and the restoration of facial paralysis [12]. PLM is the most convenient and widely available tissue type for use in palm-to-fingertip grafts [13].

The palmaris longus is a muscle that has lost its function in human erection during evolution and has become extinct gradually [14]. Since the lack of PLM has no effect on hand and wrist function, it is considered a non-essential muscle [15]. However, its clinical relevance stems from its widespread application in reconstructive and hand surgery [16]. Aside from distinctions in gender, other sources claim that its absence is more common in the genders who lack it in one form or another, that its absence is more common when both eyes are absent, and that its absence is more common when only one eye is present [17, 18]. There is a higher rate absence of palmaris longus (11.1%) in males compared to females (9.3%) [19]. However, many studies such as the one in Brazil found that there are more frequent agenesis of the palmaris longus in females with (29.7%) compared to males at (21.1%) [20].

There are a few techniques (Schaeffer's, Thompson's, Mishra's, Pushpakumar's, and Thompson's) for identifying PLM that have been described so far [15, 21]. A fresh examination was recently suggested by Gangata [22]. Research into PLM tendon agenesis has yielded that the Schaeffer and Mishra second tests are two of the most popular ones employed. As with every method, there are benefits and drawbacks to these examinations. Some tests may be conducted simply but do not provide a clear indication of muscle presence; other tests provide a clear indication of muscle presence but are more difficult to implement [16]. Therefore, effective tests are required to detect PLM, preferably those that clearly display the muscle and may be quickly implemented. In light of this, we compared an old standby (Schaffer's test) to several more modern types (Thompson's, Mishra's, AIIM's, and Hiz- Ediz's). The primary purpose of this study was to assess the frequency of PLM agenesis among students of both genders; the secondary purpose was to demonstrate the reliability of a classic test (Schaffer's test) in comparison to more modern alternatives (Thompson's test, Mishra's test, AIIM's test, Hiz-Ediz test).

METHODS AND MATERIALS

Study design: The study was a cross-sectional study carried out at the MAHSA (Malaysian Allied Health Sciences Academy), Faculty of Dentistry, from April to July 2019. All experimental techniques were in accordance with the Helsinki Declaration and authorised by the MAHSA Ethical Committee (Reference: RMC/EC01/2019). Before beginning this investigation, individuals who consented to participate were required to give written consent.

Simple size calculation: Since the study was cross-sectional, the sample size formula was a single population proportion: (n = sample size, d = precision of estimate, z = 1.96, p = 0.09, q = 0.01, d = 0.04⁄0.05). The values of 'p' and 'q' were obtained from Roohi et al. [23]. n= z2pq/d2 , z = (1.96)2(0.9) (0.01)/ (0.04)2, z = 0.346/0.0016, z = 216 subjects.

Participants: The study included 224 respondents in all, both male and female, who were all between the ages of 17 and 22. Participants with a history of upper extremity surgery or

injury, neurological or rheumatological disease, upper extremity problems, or any related abnormalities were excluded from this study. They comprised of 126 (56.3%) females and 98 (43.8%) males. The mean age of the participants was males (17.75±5.52) and females (18.10±3.01).

Procedure: The researchers explained the steps of the procedure to the participants. Each participant was requested to perform five clinical tests, namely, Schaeffer's test, Thompson's test, Mishra's test, AIIM's test, and the Hiz-Ediz test (Figure 1 to Figure 5) The physician required seven minutes to explain the tests by performing the manoeuvre involved in every test for each participant with the aid of photographs and then the student repeats the same test manoeuvre. The same specialist performed all the examinations on each patient. The PLM was deemed missing if it could not be palpated or visible beneath the skin at the distal forearm on the wrist. Both gender and palmaris longus status (present/absent) were noted.

The following tests were performed: The individual was requested to oppose the thumb to the ring finger, and then to flex the wrist. Thompson's test requires the subject to make a fist, flex the wrist, and then oppose and flex the thumb over the fingers. Mishra's test I, II; the examiner will passively hyperextend the subject's metacarpophalangeal joints of all his/her fingers and is then asked to actively flex the wrist. In the AIIM's test, the examiner touches the ulnar aspect of the subject of the base of the little finger with the tip of the thumb by applying a moderate force keeping the wrist in neutral flexion. For the Hiz-Ediz test; the examiner applies resistance to the fingers and wrist of the subject while all fingers were at the opposition with the wrist at slight flexion.

Fig. 1: Schaeffer's test

Fig. 2: Mishra's test

Fig. 3: Hiz-Ediz's test

Fig. 4: AIIM's test

Fig. 5: Thompson test

Statistical analysis: To describe the data collected, the Statistical Package for the Social Sciences (SPSS) was used to generate frequencies of the presence of the PLM tendon among the genders using the five clinical tests. Then the presence of PLM was compared if unilateral or bilateral again with respect to gender among the same test using chi-square tests. An interrater reliability analysis using the Kappa statistic was performed to determine consistency among the raters.

RESULTS

A total of 224 cases, comprised of 126 (56.3%) females and 98 (43.8%) males. The mean age of the participants was males (17.75±5.52) and females (18.10±3.01), respectively. Some 164 cases (94.2%) had right dominant hands, while 60 cases (4.8%) were left dominant. In the Schaeffer's test, right agenesis was detected in 15 cases in males and in females 31 cases, and left agenesis was determined in males with 33 cases and in females there were 40 cases. In the Thompson's test, right agenesis was detected in 17 cases in males and in females there were 33 cases and left agenesis was determined in males as 28 cases and in females there were 38 cases. In the Mishra's test, right agenesis was detected in 24 cases in males and in femalesdetected in 24 cases in males and in females there were 42 cases and left agenesis was determined in 42 cases in males and in females 53 cases. In the AIIM's test, right agenesis was detected in 17 cases in males and in females 34 cases and left agenesis determined in males in 34 cases and in females 46 cases. In the Hiz-Ediz test, right agenesis was detected in 18 cases in males and in females there were 32 cases and left agenesis was determined in males 39 cases and in females 52 cases (Table 1 and Table 2).

It was observed that the clinical tests used were more sensitive to detect the PLM tendon in the right forearm in males than in females although the number of femaleparticipants was more than males. On the other hand, after statistical analysis the p-value was insignificant in Thompson's test (0.115), Mishra's test (0.115) and the Hiz-Ediz test (0.210) with a borderline p-value in Schaeffer's test (0.087) and AIIM's test (0.087), respectively. It was observed that the Thompson's, AIIM's and Hiz-Ediz tests were more sensitive to detect the PLM tendon in the left forearm in males than in females while Schaeffer's and Mishra's test percentages were higher in females than in males. After statistical analysis, the p-value was insignificant when comparing the tests with gender (0.760, 0.769, 0.905, 0.779, and 0.824) respectively (Table 1 and Table 2).

It was noticed that detection of the unilateral presence of the PLM tendon was different between the males and females. The Hiz-Ediz test had the highest percentage of 35% among males, while the lowest was Thompson's test at 21%. In the female group the Hiz-Ediz test showed the highest percentage at 44% and the lowest was Schaeffer's test with 33% (Chart 1). It was noticed that detection of the bilateral presence of the PLM tendon was different between the males and females. The Thompson's test had the highest percentage with 65% among males, while the lowest was Mishra's and Hiz-Ediz tests at 52%. In the female group the Schaeffer's test showed the highest percentage with 74% and the lowest was Mishra's test showed 60% (Chart 2).

To assess the level of agreement between the standard test "Schaeffer's" and the other tests, the Kappa value was recorded. The Thompson's test had a substantial percentage level of agreement with the Schaeffer's test in the right and left forearm (0.761 and 0.884, respectively). AIIM's test, Hiz-Ediz test and the Mishra's tests showed moderate agreement (0.55 and 0.66), (0.51, 0.66) and (0.41, 0.57) with the Schaffer's test respectively) (Table 3 and Table 4)

Table 1: Distribution of the PLM tendon present and absent in the right forearm among gender

Test conducted	Male n=98				Female n=126				p- value
	N Present	N Absent	% Present	% Absent	N Present	N Absent	% Present	% Absent	
Schaeffer's Test	83	15	84.7	15.3	95	31	75.4	24.6	0.087
Thompson's Test	81	17	82.7	17.3	93	33	73.8	26.6	0.115
Mishra's test	74	24	75.5	24.5	84	42	66.7	33.3	0.15
AIIM's test	81	17	82.7	17.3	92	34	73	27	0.088
Hiz-Ediz test	80	18	81.6	18.4	94	32	74.6	25.4	0.21

Table 2: Distribution of the PLM tendon present and absent in the left forearm among gender

Test conducted	Male n=98				Female n=126				p- value
	N Present	N Absent	% Present	% Absent	N Present	N Absent	% Present	% Absent	
Schaeffer's test	65	33	66.3	33.7	86	40	68.3	31.7	0.76
Thompson's test	70	28	71.4	28.6	88	38	69.8	30.2	0.769
Mishra's test	56	42	57.1	42.9	73	53	57.9	42.1	0.905
AIIM's test	64	34	65.3	34.7	80	46	63.5	36.5	0.779
Hiz-Ediz test	59	39	60.2	39.8	74	52	58.7	41.3	0.824

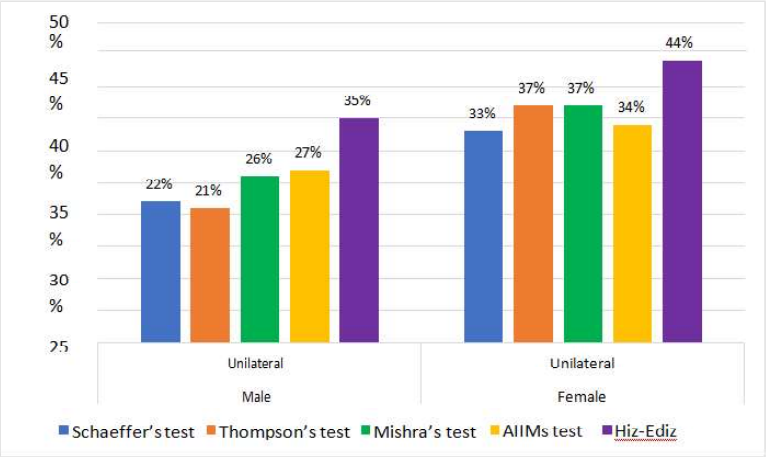

Chart 1: Percentages of Unilateral presence of PLM tendon according to gender

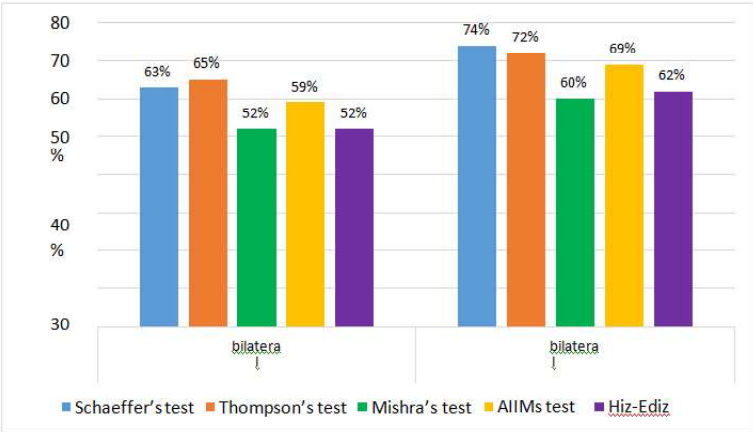

Chart 2: Percentages of Bilateral presence of PLM tendon according to gender

Table 3: Cohen's kappa test to assess the percentage of agreement between Schaeffer's and other tests for the presence and absence of PLM tendon in the right forearm.

Test in agreement with Schaffer's test	Cohen's kappa	95% CI for Kappa	
		Lower limit	Upper limit
Thompson's test	0.761	0.657	0.865
AIIMs test	0.549	0.445	0.653
Hiz-Ediz test	0.514	0.41	0.618
Mishra's test	0.411	0.307	0.514

Table 4: Cohen's kappa test to assess the percentage of agreement between Schaeffer's and other tests for the presence and absence of PLM tendon in the left forearm

Test in agreement with Schaffer's test	Cohen's kappa	95% CI for Kappa	
		Lower limit	Upper limit
Thompson's test	0.884	0.74	0.948
AIIMs test	0.656	0.552	0.76
Hiz-Ediz test	0.653	0.549	0.757
Mishra's test	0.566	0.462	0.67

DISCUSSION

According to some, the palmaris longus is the most changeable muscle in the body since it is often completely missing from one or both arms [23]. Methods for detecting the existence of the palmaris longus muscle have been developed [24]. The detection tests may yield conflicting findings because the methods used to identify neighbouring muscles to the palmaris longus tend to differ [25].

The incidence of agenesis of palmaris varies with race, and these differences have been reported [26].

The rate of absence of palmaris longus reported by Brandon et al. [7] was (11.1%) in males compared to females (9.3%) which was less than what was reported in this study. In this study, the rate of agenesis of palmaris longus in the Schaeffer's test, right agenesis was (15.6%) in males and in females (24.6%), and left agenesis was determined in males (33.7%) and in females (31.7%). In the Thompson's test, right agenesis was detected (17.3%) in males and in females (26.2%) and left agenesis was determined in males (28.6%) and in females (33.3). In the Mishra's test, right agenesis was detected (24.5%) in males and in females (66.7%) and left agenesis was determined in males (42.9%) and in females (42.1%). In the AIIM's test, right agenesis was detected (17%) in males and in females (27%) and left agenesis was determined in males (34.7%) and in females (34.5%). In the Hiz-Ediz test, right agenesis was detected (18.4%) in males and in females (25.4%) and left agenesis was determined in males (39.8%) and (41.3%) in females.

As males tend to have stronger and wider muscles and females tend to have more adipose tissue, it is possible that the higher incidence of palmaris longus described by Arquez [27] could be attributable to the latter. The current findings were corroborated by a review of the literature on agenesis in the Turkish population, which found that it was more prevalent in females and on the left side, albeit not all reported differences that were statistically significant [28, 25].

According to research conducted in Brazil, agenesis of the palmaris longus was more prevalent in females (29.7%) than in men (21.1%) [20]. In the southern region of Iran, (38.6%) of the participants with absence were females, while only (22.7%) of the participants were men [29]. However, there are contradictory studies, such as the research conducted in East Africa, which revealed a greater rate of absenteeism among females than males [30]. However, the Schaeffer's test revealed the most frequent agenesis of the palmaris longus in the right forearm (20.5%), followed by Thompson's and Hiz- Ediz tests with identical percentages of agenesis (22.3%), Mishra's test (22.8%), and AIIMs test (29.5%) of the individuals. In addition, Thompson's test exhibited the greatest detection rate of PLM in the left forearm (70.5%), compared to other tests. Schaeffer's test came in second for PLM detection with a percentage of (67.4%). AIIM's test was able to detect PLM in (64.3%) of subjects, whereas Mishra's and Hiz-tests Ediz's had similar detection rates of (59.4%) and (57%), respectively.

In this study the detection of the unilateral presence of palmaris longus tendon was different between males and females. The Hiz-Ediz test had the highest percentage (35%) among males, while the lowest was Thompson's test (21%). In the female group the Hiz-Ediz test showed the highest percentage (44%) and the lowest was for the Schaeffer's test (33%), while the detection of the bilateral presence of the palmaris longus tendon was different between the males and females. The Thompson's test had the highest percentage (65%) among males, while the lowest was the Mishra's and Hiz-Ediz tests (52%). In the female group the Schaeffer's test showed the highest percentage (74%) and the lowest was for the Mishra's test (60%). Out of the total prevalence of presence study by ALIYU et al. [34] was (82.6%), and (60.3%) exhibited unilateral presence while (20.7%) showed bilateral presence and the unilateral (69.9%) exhibited unilaterality on the right, and (90.7%) showed a left unilateral presence. This was supported by a report with a total prevalence of presence of (79%), of which (89%) were unilateral and (91%) bilateral [31].

In another study, it was also recorded with a

(93.6%) unilateral presence and (97.1%) bilateral presence, out of the total [32].

It has been stated that the most accurate test for palmaris longus evaluation is the standard or Schaeffer test [33], and the test has been applied in most of the research so that a positive result may be considered by an individual with the tendon. In the present investigation, Thompson's test detected the presence of the PLM tendon in a greater proportion of females than Schaeffer's test did in males. Concerning the level of accuracy, Thompson's test was the highest as well as had a substantial percentage level of agreement with Schaeffer's test over other tests.

CONCLUSION

Based on results of the study it can be concluded that the Thompson's test had a higher percentage among the tests to detect the presence of the PLM tendon in females while Schaeffer's test showed better results for males. Thompson's test had the highest accuracy level and the highest percentage level of agreement with Schaeffer's test compared to the other tests. According to the current study findings, Schaeffer's and Thompson's tests are recommended to be used in clinical settings to detect the presence of the PLM tendon. On the other hand, due to the limitations of the study, it is recommended to consider a larger sample size as well as an equal number of participants in terms of gender for future research. This could allow for better and clear conclusions regarding which clinical test has the highest frequency and accuracy among genders.

Conflicts of Interests: None

Author Contributions

Yaseen- data curation, **Qais-** formal analysis,
Yaseen and Maher- investigation,
Yaseen and Maher- methodology,
Yaseen- project administration, **Qais-** resources,
Qais- software, **Yaseen-** supervision,
Qais and Yaseen: validation,
Yaseen and Maher: visualization,
Qais: writing—originaldraft,
Qais: writing—review and editing,
Yaseen, Maher and Qais- The published version of the paper has been read and approved by all authors.

ORCiD

YASEEN AHMAD WAFI., MBBS., M.SC
https://orcid.org/0000-0001-5092-1551
Maher Abumosamah
https://orcid.org/0000-0003-4253-2147
Qais Gasibat
https://orcid.org/0000-0002-1193-965X

REFERENCES

[1]. Georgiev GP, Iliev AA, Dimitrova IN, Kotov GN, Malinova LG, Landzhov BV. Palmaris Longus Muscle Variations: Clinical Signifi cance and Proposal of New Classifi cations. Folia Medica. 2017;59(3):289-97. https://doi.org/10.1515/folmed-2017-0035

[2]. Eriæ M, Krivokuæa D, Savoviæ S, Lekšan I, Vuèiniæ N. Prevalence of the palmaris longus through clinical evaluation. Surgical and radiologic anatomy. 2010 Apr;32(4):357-61. https://doi.org/10.1007/s00276-009-0573-0

[3]. Olewnik £, Waœniewska A, Polguj M, Podgórski M, £abêtowicz P, Ruzik K, Topol M. Morphological variability of the palmaris longus muscle in human fetuses. Surgical and Radiologic Anatomy. 2018 Nov;40(11):1283-91. https://doi.org/10.1007/s00276-018-2069-2

[4]. Charlton S, Cyna AM, Middleton P, Griffiths JD. Perioperative transversus abdominis plane (TAP) blocks for analgesia after abdominal surgery. Cochrane Database of Systematic Reviews. 2010(12). https://doi.org/10.1002/14651858. CD007705.pub2

[5]. Zahra T, Sumra SA, Shafi S, Amjad A. Frequency of the Palmaris Longus muscle in the Population of Islamabad, Pakistan. Journal of University College of Medicine and Dentistry. 2022 Jun 25;1(2). https://doi.org/10.51846/jucmd.v1i2.174

[6]. Longhurst G, Stone D, Mahony N. Bilateral reversed palmaris longus muscle: a case report and systematic literature review. Surgical and Radiologic Anatomy. 2020 Mar;42(3):289-95. https://doi.org/10.1007/s00276-019-02363-z

[7]. Bordoni B, Zanier E. Anatomic connections of the diaphragm: influence of respiration on the body system. Journal of multidisciplinary healthcare. 2013;6:281. https://doi.org/10.2147%2FJMDH.S45443

[8]. Willard FH, Vleeming A, Schuenke MD, Danneels L, Schleip R. The thoracolumbar fascia: anatomy, function and clinical considerations. Journal of anatomy. 2012 Dec;221(6):507-36. https://doi.org/10.1111/j.1469-7580.2012.01511.x

[9]. Trussler AP, Kawamoto HK, Wasson KL, Dickinson BP, Jackson E, Keagle JN, Jarrahy R, Bradley JP. Upper lip augmentation: palmaris longus tendon as an autologous filler. Plastic and reconstructive surgery. 2008 Mar 1;121(3):1024-32. https://doi.org/10.1097/01.prs.0000299383.82723.ec

[10]. Penna V, Stark GB, Voigt M, Mehlhorn A, Iblher N. Classification of the aging lips: a foundation for an integrated approach to perioral rejuvenation. Aesthetic plastic surgery. 2015 Feb;39(1):1-7. https://doi.org/10.1007/s00266-014-0415-2

[11]. Friedhofer H, Nigro MV, Sturtz G, Ferreira MC. Correction of severe ptosis with a silicone implant suspensor: 22 years of experience. Plastic and reconstructive surgery. 2012 Mar 1;129(3):453e-60e. https://doi.org/10.1097/PRS.0b013e3182402deb

[12]. Hayashi K, Katori N, Kasai K, Kamisasanuki T, Kokubo K, Ohno-Matsui K. Comparison of nylon monofilament suture and polytetrafluoroethylene sheet for frontalis suspension surgery in eyes with congenital ptosis. American journal of ophthalmology. 2013 Apr 1;155(4):654-63. https://doi.org/10.1016/j.ajo.2012.10.022

[13]. Lai CS, Chang KP, Lee SS, Hsieh TY, Lai HT, Huang YH, Lai YW. The role of frontalis orbicularis oculi muscle flap for correction of blepharoptosis with poor levator function. Annals of Plastic Surgery. 2013 Dec 1;71:S29-36. https://doi.org/10.1097/SAP.0000000000000043

[14]. Pridgen BC, Woon CY, Kim M, Thorfinn J, Lindsey D, Pham H, Chang J. Flexor tendon tissue engineering: acellularization of human flexor tendons with preservation of biomechanical properties and biocompatibility. Tissue Engineering Part C: Methods. 2011 Aug 1;17(8):819-28. https://doi.org/10.1089/ten.tec.2010.0457

[15]. Sebastin SJ, Lim AY, Bee WH, Wong TC, Methil BV. Does the absence of the palmaris longus affect grip and pinch strength?. Journal of Hand Surgery. 2005 Aug;30(4):406-8. https://doi.org/10.1016/J.JHSB.2005.03.011

[16]. Thompson NW, Mockford BJ, Cran GW. Absence of the palmaris longus muscle: a population study. The Ulster medical journal. 2001 May;70(1):22. https://www.ncbi.nlm.nih.gov/pmc/articles/PMC2449224/

[17]. Kose O, Adanir O, Cirpar M, Kurklu M, Komurcu M. The prevalence of absence of the palmaris longus: a study in Turkish population. Archives of Orthopaedic and Trauma Surgery. 2009 May;129(5):609-11. https://doi.org/10.1007/s00402-008-0631-9

[18]. Soltani AM, Peric M, Francis CS, Nguyen TT, Chan LS, Ghiassi A, Stevanovic MV, Wong AK. The variation in the absence of the palmaris longus in a multiethnic population of the United States: an epidemiological study. Plastic Surgery International. 2012;2012. https://doi.org/10.1155/2012/282959

[19]. Brandon GJ, Azizi AB, Kalaji SM, Singh HS, Ramaiah Y, Retnabrabagaran SP. Variations in the absence of the palmaris longus muscle in a multiethnic population of Malaysia: An epidemiological study. Journal of Dental and Medical Sciences, 14(10), 117-122. https://doi.org/10.9790/0853-14104117122

[20]. Morais MA, Gomes MS, Helrigle C, Malysz T. Prevalence of agenesis of the palmaris longus muscle in Brazil and its clinics correlation. Journal of Morphological Sciences. 2017 Jan 16;29(4):0. http://www.jms.periodikos.com.br/article/587cb4b77f8c9d0d058b481d

[21]. Oudit D, Crawford L, Juma A, Howcroft A. The "four-finger" sign: to demonstrate the palmaris longus tendon. Plastic and Reconstructive Surgery. 2005 Aug 1;116(2):691-2. https://doi.org/10.1097/01.prs.0000175967.01538.3a

[22]. Gangata H. The clinical surface anatomy anomalies of the palmaris longus muscle in the Black African population of Zimbabwe and a proposed new testing technique. Clinical Anatomy: The Official Journal of the American Association of Clinical Anatomists and the British Association of Clinical Anatomists. 2009 Mar;22(2):230-5. https://doi.org/10.1002/ca.20751

[23]. Roohi SA, Choon-Sian L, Tan GH, Naicker AS, Med Rehab M. A study on the absence of palmaris longus in a multiracial population. Malaysian Orthopaedic Journal. 2007;1(1):26-8. https://pesquisa.bvsalud.org/portal/resource/pt/wpr-627372

[24]. Hiz Ö, Ediz L, Ceylan MF, Gezici E, Gülcü E, Erden M. Prevalence of the absence of palmaris longus muscle assessed by a new examination test (Hiz-Ediz Test) in the population residing in the area of Van, Turkey. Journal of Clinical & Experimental Investigations. 2011 Sep 1;2(3). https://doi.org/10.5799/ahinjs.01.2011.03.0050

[25]. Kyung DS, Lee JH, Choi IJ, Kim DK. Different frequency of the absence of the palmaris longus according to assessment methods in a Korean population. Anatomy & Cell Biology. 2012 Mar 1;45(1):53-6. https://doi.org/10.5115/acb.2012.45.1.53

[26]. Sharma DK, Shukla CK, Sharma V. Clinical assessment of absence of palmaris longus muscle and its association with gender, body sides, handedness and other neighboring anomalies in a population of central India. Journal of Anatomical Society of India. 2012 Jun 1;61(1):13-20. https://doi.org/10.1016/S0003-2778(12)80005-0

[27].Arquez HF. Morphological study of palmaris longus muscle. International Archives of Medicine. 2017 Jul 2;10. https://doi.org/10.3823/2485

[28]. Lamichhane PS, Sharma K, Lamichhane N. Study on palmaris longus muscle tendon agenesis among first year Filipino medical students. Journal of Gandaki Medical College-Nepal. 2017 Aug 1;10(1):17-20. https://doi.org/10.3126/jgmcn.v10i1.17906

[29]. Karimi-Jashni H, Rahmanian K, Jahromi AS. Agenesis of palmaris longus in southern of Iran: A population based study. OnLine Journal of Biological Sciences. 2014 Jan 1;14(1):8. http://dx.doi.org/10.3844/ojbssp.2014.8.11

[30]. Kigera JW, Mukwaya S. Frequency of agenesis palmaris longus through clinical examination-an East African study. PloS one. 2011 Dec 13;6(12):e28997. https://doi.org/10.1371/journal.pone.0028997

[31]. Alves N, Ramírez D, Deana NF. Study of frequency of the palmaris longus muscle in Chilean subjects. International Journal of Morphology. 2011;29(2):485-9. http://dspace.utalca.cl/handle/1950/8950

[32]. Yong MW, Yusof N, Rampal L, Arumugam M. Prevalence of absence of palmaris longus and its association with gender, hand dominance and absence of FDS tendon to little finger among Malay population. The Journal of Hand Surgery (Asian-Pacific Volume). 2017 Dec;22(04):484-9. https://doi.org/10.1142/S021881041750054X

[33].Sadeghifar A, Kahani AK, Saied A, Rasayi E. Interobserver and intraobserver reliability of different methods of examination for presence of palmaris longus and examination of fifth superficial flexor function. Anatomy & Cell Biology. 2018 Jun;51(2):79-84. https://doi.org/10.5115/acb.2018.51.2.79

[34]. ALIYU MN, TIRYAKIOGLU M. The palmaris longus muscle: A surface study of the population of North Cyprus. Marmara Medical Journal. 2021 Oct 1;34(3):267-7. https://doi.org/10.5472/marumj.101345

How to cite this article:

Yaseen Ahmed Wafa, Maher Abumosamah, Qais Gasibat. Prevalence of Palmaris Longus Muscle Agenesis Among Students Assessed Using Various Clinical Assessment Tests. Int J Anat Res 2023;11(1):8550-8558. **DOI:** 10.16965/ijar.2022.276