

Case Report

LITHOPAEDION

S. Saritha *¹, Gouri ².

¹ Professor, Department of Anatomy. KAMS&RI, Medical College, Hyderabad, Andhra Pradesh, India.

² Assistant Professor. Government Medical College, Hyderabad, Andhra Pradesh, India.

ABSTRACT

A lithopaedion or lithopedion is ancient Greek word meaning a stone baby. It is a rare phenomenon which occurs most commonly when a fetus dies during an ectopic pregnancy or during an abdominal pregnancy. The chance of abdominal pregnancy is one in 11,000 pregnancies. If the dead fetus is too large to be re-absorbed by the mother's body it becomes a foreign body to the mother's immune system. To protect from possible infection, the mother's body will encase the fetus in a calciferous substance. The fetus is gradually mummified becoming a stone baby. Lithopedion may occur from 14 weeks' gestation to full term. It is not unusual for a stone baby to remain undiagnosed for decades and found incidentally when taking plain x-rays films for various other investigations. This paper describes the known case of this phenomenon. The present case was about a 70 year old post-menopausal woman attended the Gynecology OPD with the complaints of mass per vaginam since 5 years. X-ray and Ultrasound scan of abdomen and pelvis revealed a lithopaedion.

KEYWORDS: Lithopaedion; abdominal pregnancy; X-ray; Ultrasound scan.

Address for Correspondence: Dr.S.Saritha. Professor, Department of anatomy, KAMS&RI Medical College, Hyderabad, Andhra Pradesh, India. **E-Mail:** kmr.saritha@gmail.com

Access this Article online

Quick Response code



Web site: International Journal of Anatomy and Research
ISSN 2321-4287
www.ijmhr.org/ijar.htm

Received: 03 March 2014

Peer Review: 03 March 2014 Published (O):30 March 2014

Accepted: 20 March 2014 Published (P):30 March 2014

INTRODUCTION

A lithopedion is an exceedingly rare obstetric phenomenon where the contents of an abdominal pregnancy calcify and become preserved [1].

Lithopedion were first discovered in 1557. Lithopaedion (stone baby) is the name given to an extra uterine pregnancy that evolves to fetal death and calcification. It is a rare encountered condition where an undiagnosed and untreated advanced abdominal pregnancy is present. The dead fetus is retained in the maternal abdominal body and later followed by calcification of the foetus.

We report a case 70 year old post-menopausal woman who presented with complaints of mass per vagina since 5 years. Complementary investigations including abdominal radiographs

and ultra sound of the abdomen and pelvis were done. Investigations revealed a lithopaedion.

Exploratory laparotomy was done and entire calcified mass was removed and send to anatomy department.

There are around 300 cases of lithopaedion reported in the world medical literature to date. The doctors of my institution have declared this is 301st case in the whole world. In our index case was old calcified dead foetus covered with thick membrane confirmed as case of lithopaedion.

Case Report

On February 4, 2012, doctors of SVS hospital in Mahaboonaagar, India removed a 35 year old 'stone baby' from 70 year-old woman. Her other children are alive and between the ages of 35-

40 years. She has five full terms normal vaginal deliveries at home. Last child birth was 25 years ago. She attained menopause 20 years back.

A 70 year old post-menopausal woman, P5L3D2 presented to the Gynecology OPD with the complaints of mass per vaginum since 5 years. The patient was resident of Mominpur a small village in Andhra Pradesh, INDIA. She had been experiencing chronic stomach pains and she was admitted to the hospital on January 25th of this year.

On examination a 24×16 cms oval, non-tender, mobile, hard mass with irregular margins and smooth surface was noted extending from the right hypochondrium to right iliac region.

Per vagina she had prolapse uterus with cystocele and rectocele.

X-ray abdomen (fig-1) revealed a fetal skeleton extending from hypochondrium to right iliac fossa along with three calcified masses in pelvis suggestive of lithopaedion with spine and intact ribs.

Ultrasound scan of abdomen and pelvis (Fig-2) showed dense calcified mass throwing an acoustic shadow extending from the right hypochondrium to pelvis. It also revealed a lithopaedion.

After several checkups, it was found that the patient had a Lithopedion, or better known as a 'stone baby'. The calcified fetus had made in to the abdomen in the course of 35 years. The patient was explained about the condition and she was admitted to hospital.

Fig. 1: Showing X-Ray Abdomen.

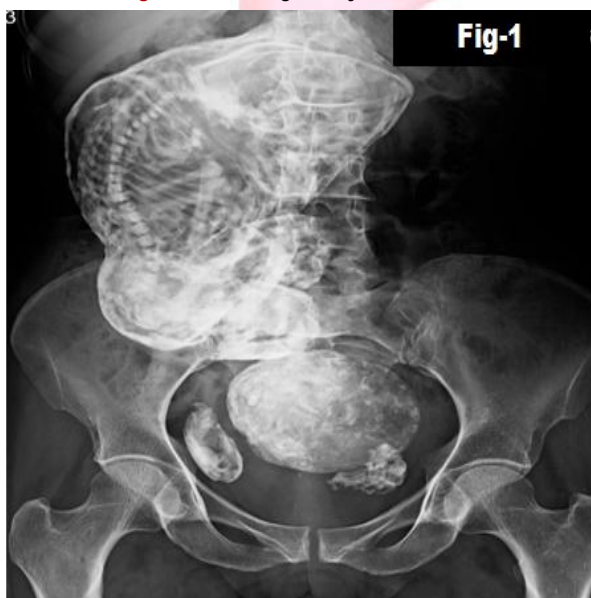


Fig. 2: Showing findings of Ultrasound scan of abdomen and pelvis

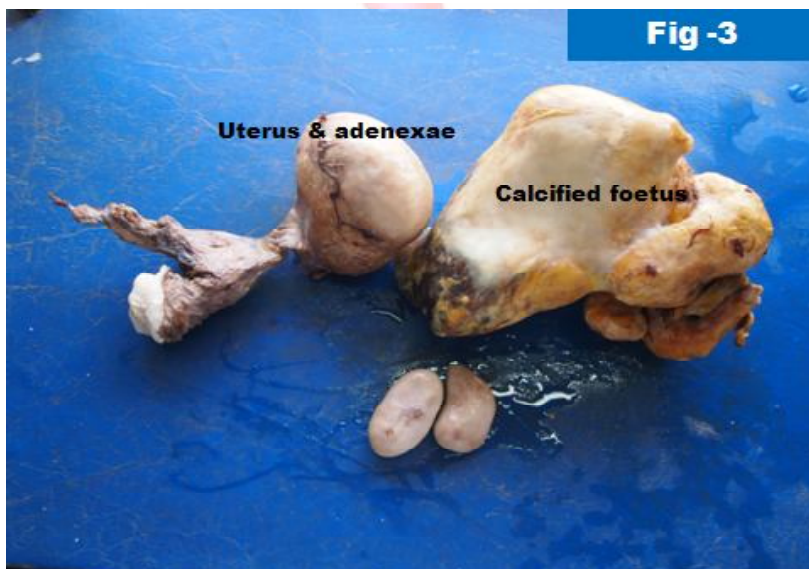
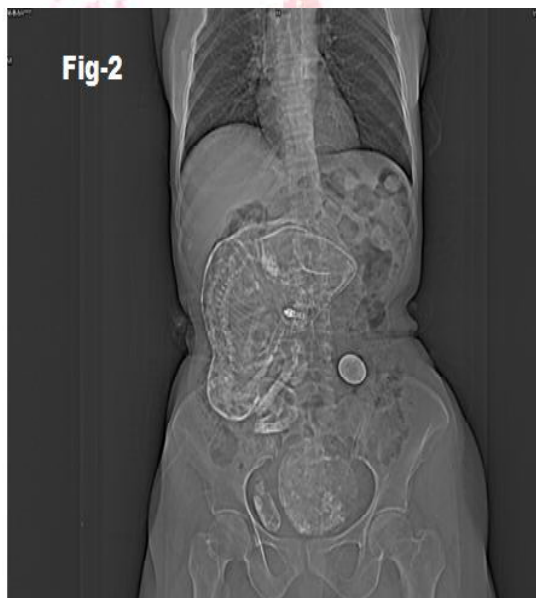

Fig. 3: Showing the Gross findings.

An operation to remove the mass was performed by a team comprised of surgeons & gynecologists.

The mass was measured at 14 inches and had hands, feet and head which were entangled among themselves and the calcified foetus was removed. It was later sent for detail autopsy studies to the Department of Anatomy.

GROSS FINDINGS (Fig 3)

The specimen of lithopaedion was measuring 24×16 cms about with intact limbs, spine. The head, the body and the hair were all calcified. We also received calcified uterus with cervix and adenexae, calcified left tubal mass (? Placenta). There were two small individual calcified masses, represent the amputated feet of the fetus.

DISCUSSION

The human body is magically intricate system. Our anatomy still holds many secrets, inspite of its depth of its complexity and we still have to understand when strange abnormalities arise. Stone baby sounds horribly tragic, but a rare phenomenon which results from a process that protects a mother after a failed abdominal pregnancy.

The condition was first described by Albucasis a physician in 10th century AD. The fewer than 300 cases have been reported in 400 years of medical literature. The doctors of my institution have declared this is 301st case in the whole world. The earliest lithopedion is one found in an archaeological excavation at Bering Sinkhole, on the Edwards Plateau in Kerr County, Texas dated to 1100 BC. Another early example was found in a Gallo-Roman archaeological site in Costebelle, southern France, dating to the 4th century.

The oldest reported case is that of a 94 year old woman, whose lithopedion was present for 60 years. In Lithopedion, fertilized egg implants anywhere outside the uterus, ectopic pregnancy, commonly being an abdominal pregnancy. The chance of abdominal pregnancy is one in 11,000 pregnancies. The estimated incidence is 1.5 to 1.8% of abdominal ectopic pregnancy [2].

The implanted fetus begins to grow, but before it reaches to an advanced stage it dies. If the dead fetus is too large to be reabsorbed by the mother's body the remains of the fetus and its

amniotic sac slowly calcify and forms a stone baby, to protect the mother's body form the infection from the decomposing tissue. Lithopedion may occur from 14 weeks' gestation to full term [3].

It is not unusual for a stone baby to remain undiagnosed for decades and found incidentally when taking plain films for various other reasons. Structures of the calcified fetus are seen clearly on abdominopelvic computed tomographic images [4].

In 1880, German physician Friedrich Kuchenmeister identified three subgroups [5]:

1) Lithokelyphos ("Stone Sheath"), where calcification occurs on the fetal membranes and not the fetus and the fetus degenerates within them.

2) Lithotecnon ("Stone Son") or "true" lithopedion, where the fetus itself is calcified after entering the abdominal cavity, following the rupture of the placental. (No calcification of the membranes).

3.) Lithokelyphopedion ("Stone Sheath and Child"), when both fetus and membranes are calcified.

D'Aunoy and King (1922) listed four changes which an abdominal fetus may undergo if it is not removed [6]:

(I) Skeletonization, where only the bones of the foetus remain following the disintegration and absorption of the soft parts.

(II) Adipocere, where the soft parts are replaced by fatty acids, soaps and salts of palmitic and stearic acids.

(IV) Suppuration, where the foetus is destroyed after an abscess has formed, usually due to E. coli infection.

(IV) True lithopaedion formation occurs if the foetus remains sterile and to varying degrees becomes infiltrated with calcium salts.

Abdominal pregnancy is an exceedingly rare occurrence, but even more unusual is prolonged retention of an advanced abdominal pregnancy with lithopedion formation.

We present the case of prolonged retention of an advanced abdominal pregnancy in an elderly woman of 70 years old who came from very poor

social-economic conditions. An abdominal series of x-ray and ultrasound revealed a fetal skeleton, a case lithopaedion. The woman underwent surgery and the stone baby was removed. (Fig-3) Our findings correlate with published cases that occurrence of lithopedion is very rare and it seen among women linked with poor antenatal care. Proper prenatal care and early diagnosis is important treatment.

CONCLUSION

Lithopedion remains a harsh reminder of poor antenatal checkup that currently prevails in the developing world. The discovery of a lithopaedion ('stone baby') is as dramatic as it is rare. A lithopaedion usually results from an abdominal pregnancy, typically secondary to a ruptured ectopic pregnancy. Ectopic abdominal pregnancies can have a complex outcome. Management approach can usually be very complicated and requires a unique treatment.

Conflicts of Interests: None

REFERENCES

- [1]. Burger NZ, Hung YE, Kalof AN et-al. Lithopedion: laparoscopic diagnosis and removal. *Fertil. Steril.* 2007;87 (5): 1208-9. doi:10.1016/j.fertnstert.2006.11.065 - Pubmed citation.
- [2]. Alymlahi EK, Chat L, Chellaoui M, Dafiri R. Lithopedion: stone baby. *Eurorad teaching files : Case 2439 (2003, Nov 2).* DOI: 10.1594/EURORAD/CASE.2439.
- [3]. Lachman N, Satyapal KS, Kalideen JM et-al. Lithopedion: a case report. *Clin Anat.* 2001;14 (1): 52-4. doi:10.1002/1098-2353(200101)14:13.0.CO;2-H - Pubmed citation.
- [4]. Sun G, Li M, Lu Y. Unrecognized lithopedion with 35 years' evolution diagnosed on computed tomographic scan. *Fertil. Steril.* 2010;94 (1): 341-2. doi:10.1016/j.fertnstert.2009.12.019 - Pubmed citation.
- [5]. Kuchenmeister .F. *Arch. Gynaek.* 17:153, 1881.
- [6]. Daunoy,R. and King E.L: *Ibid*,3:377,1992.

How to cite this article:

S. Saritha, Gouri. LITHOPAEDION: A CASE REPORT. *Int J Anat Res* 2014;2(1):283-86.