International Journal of Anatomy and Research,
Int J Anat Res 2017, Vol 5(2.1):3713-17. ISSN 2321-4287
DOI: https://dx.doi.org/10.16965/ijar.2017.155

Original Research Article

A STUDY OF MORPHOMETRY OF ADULT HUMAN LARYNX AND ITS IMPORTANCE IN CLINICAL APPLICATIONS

G.C.Poornima *[1], Dakshayini K.R [2].

[*1] Professor, Department of Anatomy, Mysore Medical College and Research Institute, Mysore, Karnataka, India.

[2] Professor and Head, Department of Anatomy, Mysore Medical College and Research Institute, Mysore, Karnataka, India.

ABSTRACT

Background: The knowledge of size, external and internal measurements of larynx is essential for diagnosis, treatment of laryngeal disorders. As hands-on experience in training is emphasised in Medical Education in all departments of Medicine and Surgery, it is important to have knowledge regarding laryngeal diameters in relation to right selection of operational tools, sizes techniques, preoperative training and designing of virtual and plastic models for training purposes.

Aim: The aim of the study was to document detailed morphometry of adult human larynx to aid in medical and surgical interventions of the larynx.

Materials and Methods: Fifty post-mortem specimens of adult human larynx were used for the study. The specimens were acquired by routine dissection. Measurements were taken using Digital Vernier caliper, scale, measuring tape. The data obtained was analysed using Microsoft Excel 2016. For each parameter-Mean, Range and SD was calculated. Z test was applied to know the significance of two means.

Results: Height of larynx-from floor of thyroid notch to Lower border of Cricoid cartilage, from upper border of Hyoid bone to lower border of Cricoid cartilage and from tip of Epiglottis to lower margin of Cricoid cartilage was 33.51±3.6mm, 50.43±6.77mm and 60.17±8.12mm respectively. Total height of Laryngeal cavity was 62.31±11.18mm. Bilateral symmetry was noted in both the Vocal and vestibular folds. The height of Vestibule 33.45±6.37mm, and was more than the Infraglottic height which was 24.21±3.5mm.

Conclusion: The wide individual dimension variation is useful in laryngeal microsurgery, laryngoscope, to know the sizes of operational tools, hands-on training for learners and design the tools for virtual and plastic models.

KEY WORDS: Laryngeal cavity, Morphology, Vocal folds, Vestibular folds.

Address for Correspondence: Dr G.C.Poornima, Professor, Department of Anatomy, Mysore Medical College and Research Institute, Mysore, Karnataka, India. Mobile: 9972515908
E-Mail: poornagc2009@gmail.com

Access this Article online

Quick Response code	Web site: International Journal of Anatomy and Research ISSN 2321-4287 www.ijmhr.org/ijar.htm
DOI: 10.16965/ijar.2017.155	Received: 16 Feb 2017 Peer Review: 17 Feb 2017 Revised: None Accepted: 03 Apr 2017 Published (O): 30 Apr 2017 Published (P): 30 Apr 2017

INTRODUCTION

Larynx is one of most complex human organ. It extends from C3 -C5, higher in children and adult females.The phonating mechanism is designed for voice production, connects with inferior of pharynx and with the trachea.It guards the airpassage,especially during swallowing and maintain patent airway [1].

The larynx has developed during evolution as complex mechanism of skeletal structures and

neuromuscular control, which allows it to modify the expiratory stream to produce highly complex pattern of sound with varying loudness up to 12 years of age. Elevated levels of testosterone in males at puberty results in strengthening of the walls of larynx, enlargement of laryngeal cavity, lengthening of vocal folds and the conspicuous laryngeal prominence. Precise knowledge of the morphometry of the laryngeal cavity is useful in various interventions like bronchoscopy and endoscopy [2]. Morphometric data is also useful in Otorhinolaryngology procedures such as partial or total laryngectomies, laryngeal microsurgery in cases of subglottic stenosis and post intubation stenosis.

Researchers have worked on geometric characterisation of laryngeal cartilage for biomechanical modelling. This can help in adjustments in the prephonatry its periodicity in vibration and to ease of phonation.Moreover in electrophysiology in radiodiagnostic studies like EMG,CT,MRI and surgical treatments like thyroplasty and arytenoid adduction, canine model is used for the study of mechanics and physiology of voice production,due to similarities in morphometry [3].

The laryngeal diameter in senile and its usefulness in ORL diagnostic and operational methods. To select right operational tools, sizes, the technique of choice, preoperative designing and building virtual and plastic models for physician training [4].

The work is done on metrical study of laryngeal skeleton in Nigerians and on ossification of laryngeal cartilages. This study is to invoke interest in condition post-intubation stenosis, subglottic stenosis of lower respiratory tract [5,6].

They have been studies done to describe preadolescent and adolescent laryngeal growth quantitatively from the data obtained from cadaveric human larynges [7].

Hirano investigated in their work regarding Asymmetry of laryngeal framework in adults more directly preponderance in asymmetry than children [8].

Eckel et al studied on autopsied specimens carried out morphometric measurements of laryngeal framework in adults - external & internal diameters of all laryngeal cartilages [9].

Eckel et al did a study to apply plastination method in preparation of whole organ sections of larynx and to determine potential of this method in borderline area between gross anatomy and histology with respect to cartilage, muscle and connective tissue patterns and also to know the extent of shrinkage and alteration in anatomic structure and proportions [10].

Joshi MM et al 2013 have done work on morphology of larynx taking dimensions of folds, laryngeal cavity and larynx as a whole in western population .This knowledge is useful in various clinical procedures [11].

The work has been done on external laryngeal framework i.e the precise level of vocal folds projected as external thyroid cartilage and its importance in laryngeal surgery like Thyroplasty, to mobilise paralysed vocal folds [12].

Sushma RK et al 2011 in their study found there is significant difference in male and female larynges.The dimensions of larynx and internal cricoid diameter is important, may act as a reliable guide for various interventions involving upper respiratory passages [13].

Raindrop Jose etal 2003 studied about anatomic measure of laryngeal framework in Filipinos and noted gender and race related differences [14].

Martin SE, Mathur et al 1997 in their work the effect of age ,sex ,obesity and posture on upper airway size, concluded that patient with sleep apnea as age advances there is narrowing of upper airway and men have greater upper airway collapsibility on lying down at Oropharyngeal junction then women [15].

Hence the objective of the present study of adult human larynx is to study parameters of larynx, laryngeal folds and cavity.

MATERIALS AND METHODS

This descriptive study was done in Department of Anatomy, Mysore Medical College and Research Institute, Mysore. Donated & unclaimed cadavers meant for purpose of medical teaching, training and researches were used for the study.

After obtaining the clearance from the Institutional ethical committee, the study was carried out for period of 6-8 months from March 2016 to December 2016.

The study sample included 50 larynx collected from adult cadavers aged 30-60 years of both sexes [Figure 1a &1b]. Fully developed normal adult human larynx were used for the study. Larynx from children, damaged, mutilated, and deformed larynx were excluded from the study.

Procedure: Laryngeal specimens extending from dorsum of tongue to upper part of Trachea were dissected and stored in 10% formalin for 3-5 days. The specimens were cleaned and measurements were taken using Digital Vernier callipers, measuring tape and scale. The following measurements were taken and the data was tabulated.

External diameters:

Height of larynx: From the floor of Thyroid notch to lower border of Cricoid cartilage(L1) Figure-2, From upper border of Hyoid bone to Lower border of Cricoid cartilage(L2) Figure-2, From Tip of Epiglottis to Lower border of Cricoid cartilage (L3)

Internal diameters-Laryngeal cavity: Height of Vestibule-tip of epiglottis to upper border of Vocal folds(a) Figure 3, Height of Sinus-right and left-between vocal and vestibular folds(b)-Figure 5, Height of Infraglottic cavity-between vocal folds to lower border of Cricoid cartilage(c) Figure-3

Total height of laryngeal cavity: Tip of epiglottis to lower border of Cricoid cartilage(d), Length of Vocal folds, Length of Vestibular folds-Bilaterally, Length and height of Aryepiglottic folds - Bilaterally-Fig-4 &5.

Fig. 1: 1.a. Materials used for dissection and taking measurements. 1.b Specimens used for dissection.

Fig. 2: Showing measurements of height of larynx.

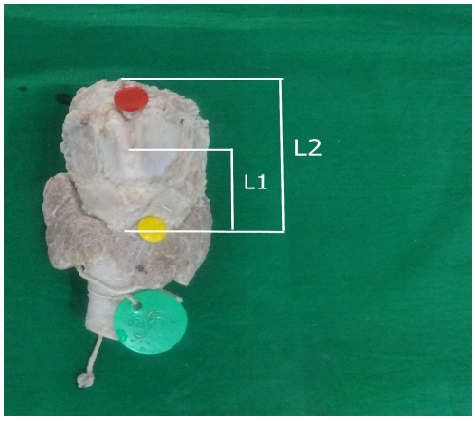

Fig. 3: Showing measurements of height of vestibule and height of infra glottic cavity.

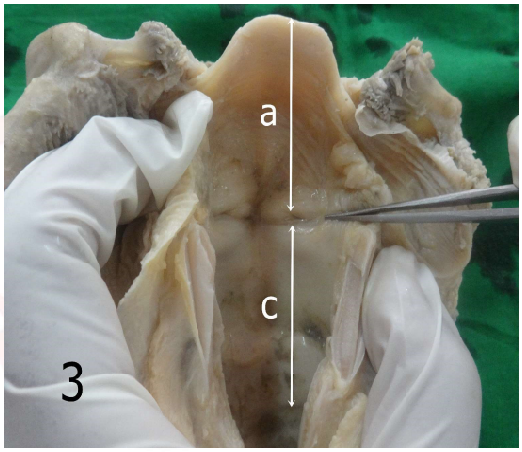

Fig. 4: Showing measurements of height of the aryepiglottic folds.

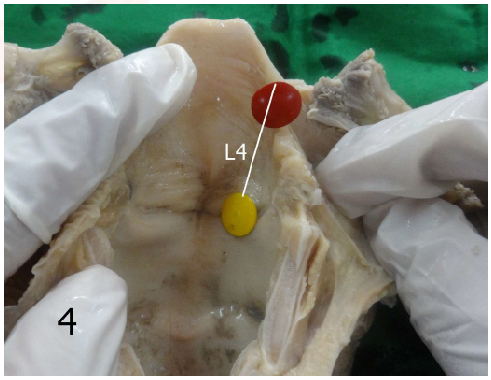

Fig. 5: Showing measurements of length of the aryepiglottic fold and the sinus of larynx.

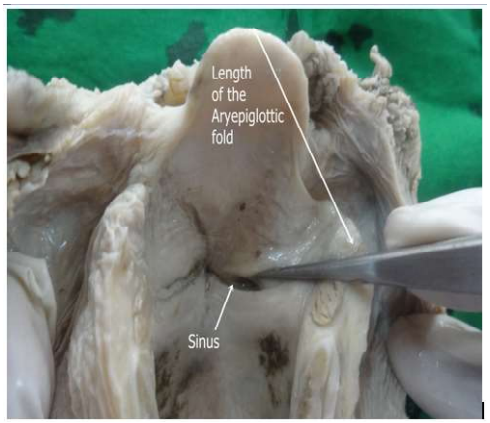

Statistical Analysis: Data was analysed using Microsoft Excel. For each parameter, the Mean, Range, SD were calculated. Z tests was used to test the significance of 2 means. Z value is less than 1.96 and p value >0.05 suggested that the observed difference between 2 means was not statistically significant. Z value is more than 1.96 and p value <0.05, meant the observed difference between the 2 means was statistically significant.

RESULTS

In the present study, height of larynx (L1) was 33.51±3.6mm. Height of larynx from Hyoid bone to Cricoid cartilage (L2) was 50.43±6.77mm and the height of Larynx from Tip of Epiglottis to Cricoid cartilage (L3) was 60.17±8.12mm.The average measurements of larynx is listed in Tab1.

Internal measurements of the larynx were as shown in Table 2. The mean height of vestibule was 33.45±6.37 mm and was more than the infra-glottic measurement, which was 24.21±3.52mm. The total height of laryngeal cavity was 62.31±11.18mm. There was no significant difference between the height of the sinus between right and left side.

Table 3 shows measurements of vocal folds. The length of the vocal folds length was 7-15 mm and vestibular folds is 8-18 mm on both sides Bilateral symmetry was noticed in vocal and vestibular folds.

Table 1: Showing measurements of Height of Larynx.

Sl no	Height of Larynx	Mean (mm)	S.D (mm)	Range (mm)
1	L1	33.51	3.6	25.6-42.6
2	L2	50.43	6.77	31.75-61.0
3	L3	60.17	8.12	41.6-76.62

Table 2: Showing measurements of the Laryngeal cavity.

Sl no	Laryngeal cavity	Mean (mm)	S.D (mm)	Range (mm)
1	a	33.45	6.37	19.21-43.17
2	b	2.32	1.01	0.78-4.5
3	c	24.21	3.52	17.8-33.6
4	d	62.31	11.18	25.73-81.5

Table 3: Showing the measurements of folds length.

Sl No	Parameter	Mean (mm) Right&left	Range (mm) Right &left	S.D (mm)	Z value	'p' value
1	Vocal folds	12.42mm	7.0-15mm	2.3	1.96	>0.05
2	Vestibular folds	12.94mm	8.0-18.0mm	2.42	1.96	>0.05

Table 4 shows the measurements of the arye-piglottic folds. The height of Aryepiglottic folds (L4) was 16.92 and 16.95 mm right and left sides respectively. The length of Ary-epiglo ttic folds was 12.97 and 13.01 mm right and left sides respectively.The morphology data showed no significant asymmetry between right and left sides.

Table 4: Showing the length and height of the Ary-epiglottic folds.

SL No	Parameter	Right side Mean±S.D and range (mm)	Left side Mean±S.D and range (mm)	'Z' Value	p-value
1	Length	12.97±4.60 (6.45-24.62)	13.01±4.65 (6.45-24.62)	1.96	>0.05
2	Height(L4)	16.92±3.89 (9.3-24.04)	16.95±3.87 (9.3-24.04)	1.96	>0.05

DISCUSSION

The present study provide a full data determining the size and & extent of laryngeal cavity. The findings of present work was similar to work done by Joshi MM et al in 2013 [11]. [Table 5 &6]

Table 5: Showing the Comparison of present work with MM Joshi et al.

	Present work	MM Joshi et.al
L1	33.51±3.6mm	32.42±3.41mm
L2	50.43±6.77mm	54.39±6.04mm
L3	60.17±8.12mm	57.13±7.32mm
a	33.45±6.37mm	32.11±5.77mm
b	2.32±1.01mm	2.87±1.37mm
c	24.21±3.52mm	23.05±3.13mm
d	62.31±11.18mm	61.52±6.84mm

Ajmani [1990] observed higher height of larynx from floor of thyroid notch to lower margin of Cricoid cartilage in Nigerians was 45.06±8.41 mm in males and 38.08±8.25mm in females.

Tayama [2001] observed that the size and basic morphology is similar in canine and human larynx.

Internal measurements of the laryngeal cavity in the present study was similar to the work done by Joshi MM et al in 2013 [11]. [Table-5 &6]

Zielinski et al 2001 [4] reported that mean height of Infra-glottic cavity was 25.90±3.80 mm in male and 22.18±3.67 mm in female and in the present study it was 24.21±3.52mm.

In present work, mean measurements of the

vocal and vestibular folds is slightly lesser than the work MM Joshi et al 2013[11]

The laryngeal framework was symmetric to greater extent in all larynges. Similarly Hirano et al (1989)[8] described that degree of asymmetry do not differ among different age groups there was directional preponderance in asymmetry.There must be some compensatory mechanisms for asymmetry framework to keep the vocal fold edges relatively symmetry.

In the present work, the length of right and left Aryepiglottic fold is-12.97±4.60 mm and 13.01±4.65mm and "z" valueis 1.96 and p value >0.05,so statistically not significant.The height of right and left aryepiglottic fold (L4) is 16.93±3.88 mm. This is almost similar to work of Joshi MM etal 2013 [11]. [Table 6].

Table 6: Comparison of present work with MM Joshi et al.

	Present work	MM Joshi et.al
Length of Vocal folds	Right-12.42mm Left-12.86mm Range(7-15)	Right-14.84mm Left-14.86mm Range-(9-25mm)
Length of Vestibular folds	Right-12.94mm, Left-12.98mm Range(8-18)	Right-14.89mm Left-14.92mm Range(10-24)
Length of Aryepiglottic fold	Right-12.97mm Left-13.01mm (±3.06mm)-avg of both sides	Right-16.43mm Left-15.85mm (±3.03mm)-avg of both sides
Height of Aryepiglottic fold(L4)	Right-16.95mm Left-17.64mm (±3.89mm)-avg of both sides	Right-17.94mm, left-17.64 mm (±2.57mm)-avg of both sides

The morphological data showed no significant asymmetry between right and left side as p value is >0.05.

Most of the work done is on laryngeal cartilages [6-10,12-14]. There is slight variation with other similar work, but statistically not significant. Most of the samples collected were of males so sexual differences could not be elicited.

There is not much work done on morphometric study of human adult larynx, so most of the available data is on laryngeal cartilages. The comparison between the similar works is limited and data available on morphometry is scarce. A sincere effort is made to make the study interesting with available material and time.

CONCLUSION

The study gives a detailed description of the dimensions of adult human larynx in the given sample size. There is slight variation in individual parameters. Bilateral asymmetry though present in majority of specimens, it is insignificant.

This study throws light on the morphometric data to be useful in Otorhinolaryngology, microsurgery, preparations in surgical tools, preparation of plastic and virtual models for training purposes & teaching modalities.

Conflicts of Interests: None

REFERENCES

[1]. Bannister LH. From The Respiratory System. In Gray's Anatomy. 38th ed. Edited by William PL, Bannister LH, Berry MM, Collins P, Dyson M, Dussek JE et al. Edinburg:Churchill Livingstone;1995:1637-1638.

[2]. Moore KL, Dalley AF. The Visceras of Neck. Clinically oriented Anatomy.4th Ed. Philadelphia:Lippincott William and Wilkins;1997:1038-1041.

[3]. Tayama N. Geometric characterisation of the laryngeal cartilage framework for biomechanical modelling. Ann Otol Rhino Laryngol 2001;110:1154-61.

[4]. Zielinski R. Morphometrical study on senile larynx. Folio Morphol (Warsz) 2001;60:73-78.

[5]. Ajmani M, Jain S, Saxena S. A metrical study of laryngeal cartilages and their ossification. Anat Anz 1980;148:42-48.

[6]. Ajmani M. A metrical study of laryngeal skeleton in adult Nigerians. J Anat 1990;171:187-191.

[7]. Kahane J.Growth of human prepubertal and pubertal larynx. J Speech Hear Res 1982;25:446-55.

[8]. Hirano M, Kurita S, Yukizane K, Hibi S. Asymmetry of the laryngeal framework. A morphologic study of cadaver larynges. Ann Otol Rhino Laryngol 1989;98:135-40.

[9]. Eckel H,Sittel C, Zorowka P, Jerke A .Dimensions of laryngeal framework in adults. Surg Radiol Anat 1994;16:31-6.

[10]. Eckel H, Sittel C, Walger M, Sprinzl G, Koebke J. Plastination: A new approach to Morphological Research and Instruction with Excised Larynges. Ann Otol Rhinol Laryngol 1993;102:660-64

[11]. Joshi MM, Joshi SS, Joshi SD. The morphological study of adult human larynx in a western Indian population. Larngol Voice 2011;1:50-4.

[12]. Meiteles LZ, Lin PT, Wenk EJ. An anatomic study of the external laryngeal framework with surgical implications. Otolaryngol Head Neck Surg. 1992 106(3):235-40

[13]. Kotian SR, Nayak V et al. Morphology of Human Larynx: an Anatomical Study. Cukurova Medical Journal 2014; 39(4):779-783.

[14]. Raindrop SJ, Embate, Romualdez J, LimW. Anatomic measurements of the laryngeal framework in Filipino adult cadavers. J of Otolaryngology 2003;18(3,4):121-129.

[15]. Martin SE, Mathur R, Marshall I, Douglas NJ. The effect of age, sex, obesity and posture on upper airway size. J Eur Resp.1997;10:2087-90.

How to cite this article: G.C.Poornima, Dakshayini K.R. A STUDY OF MORPHOMETRY OF ADULT HUMAN LARYNX AND ITS IMPORTANCE IN CLINICAL APPLICATIONS. Int J Anat Res 2017;5(2.1):3713-3717. **DOI:** 10.16965/ijar.2017.155