International Journal of Anatomy and Research,
Int J Anat Res 2016, Vol 4(4):3267-72. ISSN 2321-4287
DOI: http://dx.doi.org/10.16965/ijar.2016.456

Original Research Article

VARIATIONS OF FISSURES AND LOBES IN ADULT HUMAN LUNGS: A CADAVERIC STUDY FROM TELANGANA

Tallapaneni Sreekanth.

MD, Associate Professor, Department of Anatomy, Shadan Institute of Medical Sciences, Teaching Hospital & Research Center, Peerancheeruvu, Near Arramaisamma Temple, Hyderabad, Telangana, India.

ABSTRACT

Background and Aims: The complete classical fissures of the lung hold the lobes together only at the hilum, enabling the lobes to move on each other during respiration. The position of the fissures can be used as reliable land marks in specifying the pathological lesions in the lungs. The present study is conducted on the lung specimens for better understanding of the morphology of their fissures and lobes. Also to compare the variations present with the previous studies, and to correlate with the possible clinical implications.

Materials and Methods: In the present study thirty pairs of lungs were used that were obtained from the formalin fixed cadavers. All the specimens were meticulously observed for the patterns of the lobes and fissures. All the variations were noted and pictures were taken.

Results: thirty pairs of lungs were studied. 14(46.67%) right sided lung specimens and 22(73.33%) left sided lung specimens showed fissures and lobes according to the standard description of anatomy text books. 16 (53.33%) right sided lung specimens and 8(26.67%) left sided lung specimens showed variant pattern of fissures and lobes. 2 (6.66%)right sided lungs showed Incomplete oblique fissure. 3 (10%) right sided lungs showed absence of horizontal fissure and 7 (23.33%) showed incomplete horizontal fissures. 3 (10%) lungs showed Presence of accessory fissures. 6 (20%) left sided lung specimens showed incomplete oblique fissure and 2 (6.66%) showed accessory fissures.

Conclusion: The results of the present study and their comparison with the earlier studies clearly shows that there is a wide range of difference in the occurrence of accessory fissures, major and minor fissures between and among different populations. Prior awareness of the existence of incomplete major fissures or their absence, and the presence of accessory fissures of the lungs is an essential prerequisite for the C.T. surgeons planning for segmental resections or lobectomies, the pulmonologists diagnosing and the Radiologists reporting the chest radio graphs, horacic C.T. and M.R.I. scans.

KEY WORDS: Accessory Fissures, Incomplete Fissure, Absence Of Fissure.

Address for Correspondence: Dr. Tallapaneni Sreekanth, Associate Professor, Department of Anatomy, Shadan Institute of Medical Sciences, Teaching Hospital & Research Center, Peerancheeruvu, Near Arramaisamma Temple, Hyderabad, Telangana, India.
Mobile No: 70934 49309, 91006 83056. **E-Mail:** anatomysreekanth18@yahoo.com

Access this Article online

Quick Response code	Web site: International Journal of Anatomy and Research ISSN 2321-4287 www.ijmhr.org/ijar.htm	
DOI: 10.16965/ijar.2016.456	Received: 01 Nov 2016 Peer Review: 03 Nov 2016 Revised: None	Accepted: 01 Dec 2016 Published (O): 31 Dec 2016 Published (P): 31 Dec 2016

INTRODUCTION

A pair of lungs are the essential organs of respiration which are present in the thoracic cavity. The right lung is having two fissures, an oblique and horizontal fissure dividing it into an upper, middle and lower lobes. The oblique fissure separates the lower lobes of the right lung from the remaining two lobes. The horizontal

fissure is seen separating the middle and upper lobes. The left lung which is relatively narrower and lighter than the right lung has a single oblique fissure dividing it into an upper and lower lobes. In a fully abducted arm the left oblique fissure is approximately indicated by the vertebral border of scapula [1]. Identifying the accessory fissures by the radiologists during the interpretation of chest radiographs, C.T. and M.R.I. scans is a challenging task. As the fissures usually occur at the boundaries between the broncho pulmonary segments they are not appreciated as distinct entities or could be misinterpreted [2]. The frequently found accessory fissures are superior accessory fissure, inferior accessory fissure and left minor fissure. When the superior accessory fissure is present, it separates the superior segment from the rest of the segments of the lower lobe. The superior segment is called as dorsal lobe or posterior lobe. The inferior accessory when present, separates a small infra cardiac lobe from the remaining segments of the lower lobe of lungs on the diaphragmatic surface. The left minor fissure when present is seen separating the lingual from the remaining segments of the upper lobe of left lung [2]. Depending up on the depth and completeness of the accessory fissure its appearance varies in chest radiographs and C.T. M.R.I. scans[3]. Basically a fissure acts as a physical boundary between the segments of the lungs. These fissures may be complete or incomplete. When complete the lobes of the lungs remain held together only at the hilum by the bronchi and pulmonary vessels. When the fissures are incomplete the lobes of the lungs exhibit areas of parenchymal fusion. Occasionally the fissure may be totally absent [4].

The Grading of the pulmonary fissures was done by Craig and Walker. They proposed four grades depending upon the degree of the completeness of the fissure and the location of pulmonary artery at the base of the oblique fissure. Grade I- complete fissure with entirely separate lobes; Grade II- complete visceral cleft but parenchymal fusion at the base of the fissure; Grade III – visceral cleft evident for a part of the fissure; and Grade IV – complete fusion of lobes with no evident fissure line [5].

Ontogenetically the lungs are composite masses of both endodermal and mesodermal tissues. The mucosal lining of the bronchi and the epithelial cells of the alveoli are derived from the endodermal tissue of the lung bud. The muscles, cartilage of the bronchi and the blood vessels of the lung are derived from splanchnopleuric mesoderm of the foregut[6]. When the embryo is approximately 4 weeks old (about 28 days after fertilization) the endodermal respiratory diverticulum (lung bud) is seen as an outgrowth from the ventral wall of the foregut. This lung bud bifurcates into two primary or principle bronchial buds. The bifurcation starts on or after 22nd day and ends latest by 28th day[7]. The right bronchial bud divides into three secondary bronchial buds and the left bronchial bud divides into two secondary bronchial buds in the fifth week of intra uterine life. By the sixth week the tertiary bronchi are seen budding up from the secondary bronchial buds of both the lungs to form the bronchopulmonary segments.

There is obliteration of all the spaces between the individual bronchopulmonary segments except along the line of division of principle bronchi where the deep complete fissures remain dividing the right lung into three lobes and left lung into two lobes. These fissures are the obliquely and horizontally positioned in the right lung and obliquely place in the left lung [6]. The visceral pleura is reflected along these fissures covering the individual lobes on all sides. The monopodial branching of stem bronchi is the cause for accessory bronchi and lobes often seen in adult lung [8]. The defective development of the lung will give rise to different variations seen in the form of incomplete or absent major fissures or presence of accessory fissures and lobes [9,10].

MATERIALS AND METHODS

30 pairs of lungs from formalin fixed cadavers of Telangana, used for dissection by 1st year M.B.B.S (Pre medical) students in the Department of Anatomy at Shadan Institute of Medical Sciences, Teaching Hospital & Research Centre, Hyderabad, Telangana were studied. All the 60 lungs specimens were meticulously observed for the patterns of lobes and fissures. All the variations of the specimens were noted

and photographed.

RESULTS

Thirty pairs of lungs were studied. 14(46.67%) right sided lung specimens and 22 (73.33%) left sided lung specimens showed fissures and lobes according to the standard description of anatomical text books. 16 (53.33%) right sided lung specimens and 8 (26.67%) left sided lung specimens showed variant pattern of fissures and lobes. 2 (6.66%)right sided lungs showed Incomplete oblique fissure. One right sided lung specimen showed faint and incomplete, both oblique and horizontal fissures. Fig (1). On the costal surface the faint oblique fissure and horizontally running fissures were seen. The fissures were incomplete and did not meet with each other in their course. The upper lobe was seen incompletely separated from both lower and middle lobes by a faint incomplete horizontal fissure. There was no clear cut demarcation between the three lobes of the right lung.

The parenchymal tissue was continuous between all the three lobes. 7 (23.33%) right sided lung specimens showed incomplete horizontal fissures Fig (2). The incomplete horizontal fissures of various lengths were seen extending from the oblique fissure but did not reach the anterior border. The upper and lower lobes were seen as individual lobes. But the upper and middle lobes of these right sided lung specimens were not separate and had continuation of the parenchymal tissue. 3 (10%) showed absence of horizontal fissure. Fig (3). Only a single oblique fissure was seen in these right lungs. These 3 right sided lung specimens had only two lobes the upper and lower. The middle lobe was absent. 3 (10%) lungs showed Presence of accessory fissures Fig(4 &5). One right sided lung showed the presence of superior accessory fissure in its lower lobe. It was seen arising from the oblique fissure and running laterally for the short distance and in this process was dividing the apical segment incompletely from the other segments of the lower lobe. This apical portion of the lower lobe is called as dorsal or posterior lobe Fig (4). The other two right sided lungs showed an accessory fissure cutting both the oblique and horizontal fissures resulting in four separate lobes. On the costal surface the fissures were appearing as alphabet "X" dividing the lung into four individual lobes.

2(6.66%) left sided lung specimens showed the presence of an accessory fissures. One of them showed an accessory fissure running horizontally from the oblique fissure and cutting the anterior border. This left sided lung had 3 separate lobes upper, middle and lower lobes, just like the right lung. It was identified as a left lung due to the presence of cardiac notch and lingual Fig (6). The other lung showed accessory fissure running obliquely. The medial surface of the lung showed these accessory fissure separating a chunk of parenchymal tissue. Incomplete oblique fissure was seen in 6 (20%) left sided lung specimens Fig(7). The division of the left lung into upper and lower lobes was incomplete with continuation of the parenchymal tissue beyond the termination of the incomplete oblique fissure.

Table 1: Incidence of anatomical variations of fissures in the Right sided and in the Left sided Lung specimens.

Right Lung

Normal pattern of fissures & lobes	14 (46.67%)
Variant pattern of fissures and Lobes	16 (53.33%)
Absence of Oblique Fissure	Nil (0%)
Incomplete Oblique Fissure	2 (6.66%)
Absence of Horizontal Fissure	3 (10%)
Incomplete Horizontal Fissure	7(23.33%)
Presence of Accessory fissures	3 (10%)

Left Lung

Normal pattern of fissures & lobes	22(73.33%)
Variant pattern of fissures and lobes	8 (26.67%)
Absence of Oblique Fissure	Nil (0%)
Incomplete Oblique Fissure	6 (20%)
Presence of Accessory Fissures	2 (6.66%)

Fig. 1: Right lung showing incomplete oblique fissure and horizontal fissure.

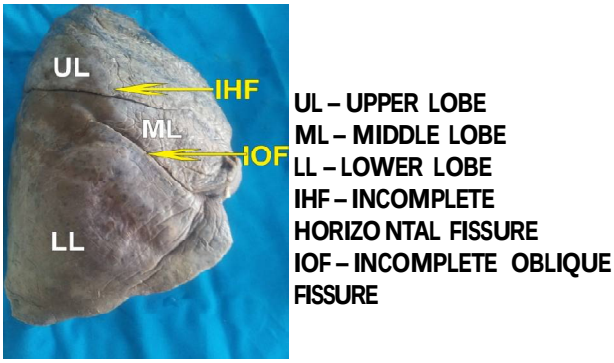

Table 2: Showing the incidence of variations of major and minor fissures of both the right and left sided lung specimens in the present study and comparison with the findings of other authors.

	Varalakshmi et al. 2014	Dutta et al. 2013	Kaul et al. 2011	Meenakshi et al.2004	Devi et al. 2011	Nene 2011	Lydia S. Quadros 2014	Radha K 2015	Present study 2016
Right lung - oblique fissure incomplete	16.70%	61.54%	24%	36.60%	9%	6%	5.55%	17%	6.66%
Absent	0	11.40%	8%	0	0	2%	0	0	0
Right lung- Horizontal fissure Incomplete	30%	38.89%	32%	63.30%	18%	8%	25%	40%	23.33%
Absent	10%	34.62%	40%	16-.6%	9%	14%	4%	17%	10%
Left lung Oblique fissure Incomplte	29.40%	48%	40%	46.60%	36%	12%	1%	23%	20%
Absent	3%	8%	0	0	9%	0	0	0	0

Fig. 2: Right lung showing incomplete horizontal fissure. the oblique fissure is complete separating the upper lobe from the lower lobe. the incomplete horizontal fissure is seen extending from the oblique fissure forwards.

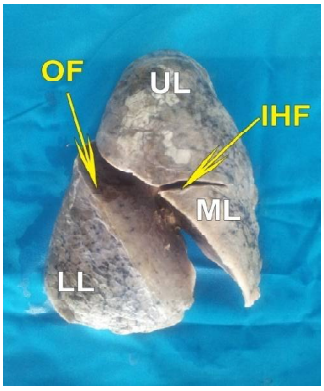

UL – UPPER LOBE
ML – MIDDLE LOBE
LL – LOWER LOBE
IHF – INCOMPLETE HORIZONTAL FISSURE
OF –OBLIQUE FISSURE

Fig. 3: Right lung showing only two lobes. an upper and lower lobes are seen due to an oblique fissure with absence of horizontal fissure.

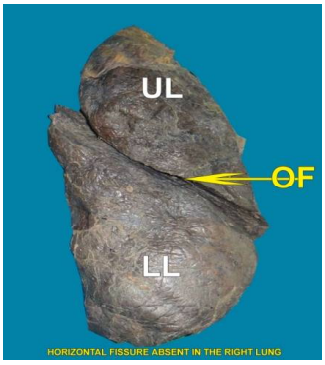

UL – UPPER LOBE
ML – MIDDLE LOBE
LL – LOWER LOBE
OF –OBLIQUE FISSURE

Fig. 4: Right lung showing accessory fissures with four lobes.



UL – UPPER LOBE
ML – MIDDLE LOBE
LL – LOWER LOBE
HF – HORIZONTAL FISSURE
OF –OBLIQUE FISSURE
AF –ACCESSORY FISSURE

Fig. 5: Accessory fissure seen on the costal surface of the right lung which is meeting with the horizontal and oblique fissures. Four individual lobes of the right lung are formed. A typical "x" appearance of the fissures can be seen



UL – UPPER LOBE
ML – MIDDLE LOBE
LL – LOWER LOBE
HF – HORIZONTAL FISSURE
OF –OBLIQUE FISSURE
AF –ACCESSORY FISSURE

Fig. 6: The normal right lung showing horizontal and oblique fissure. the left lung showing oblique fissure and horizontal [accessory fissure]. There is a clear demarcation of all the three lobes of the left lung due to the accessory horizontal fissure just as a right lung.

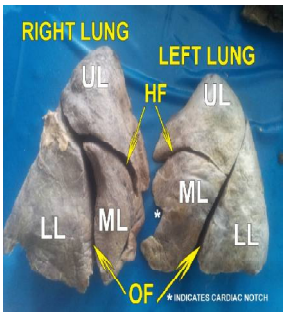

UL – UPPER LOBE
ML – MIDDLE LOBE
LL – LOWER LOBE
HF –HORIZONTAL FISSURE
OF –OBLIQUE FISSURE

Fig. 7: Left lung with incomplete oblique fissure the parenchymal tissue of the upper lobe and the lower lobe were continous with each other from the point of termination of the oblique fissure.

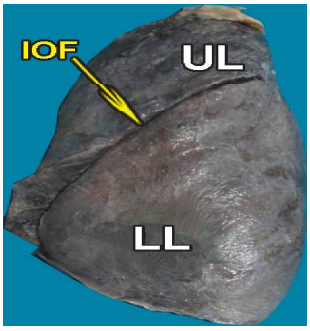

UL – UPPER LOBE
LL – LOWER LOBE
IOF – INCOMPLETE OBLIQUE FISSURE

DISCUSSION

In the present study 53.33% of right sided lung specimens showed interesting variations. 1 (3.33%) Right sided lung showed presence of both incomplete oblique and horizontal fissure. Enakshi Ghosh [11] after studying 46 right lungs reported the incidence of the both incomplete horizontal and oblique fissures to be 1.38%. The present study gives a higher incidence of the occurrence of both incomplete fissures in the right lung. The occurrence of incomplete oblique fissure in the right lung was reported by Varalakshmi [12] to be 16.7%, Dutta et.al [13] to be 61.54%, Kaul et.al., [14] to be 24% and Meenakshi et al., [15] to be 36.6% whereas Devi et.a [16] reported to be 9% Lydia S Quadros [18] reported to be 5.55%. In the present study the occurrence incomplete oblique fissure of the right lung was 6.66%. The incidence reported by Nene (2011) [17] was 6% which is very close to the present study. The incomplete fissure is considered to be the main cause of post operative air leakages besides altering the spread of diseases. It gives an atypical appearance of pleural effusion on chest radiographs [20]. Better understanding of the pulmonary pathologies like pleural effusion, pneumonia is possible only by the accurate recognition of incomplete major and minor fissures

Dutta et.al., [13] Kaul et.al.,[14] and Nene [17] reported the absence of oblique fissures to be 11.4%, 8% and 2% respectively. However, Many authors like Meenakshi et.al [15], Devi et.al [16], Lydias Quadros [18] and Radha K [19] reported the presence of oblique fissure in all right lungs studied by them. In the present study oblique fissure was present in all the right sided lung specimens but was incomplete in two lungs.

Meenakshi et al. [15], Dutta et.al [13] and Radha K reported the incidence of incomplete horizontal fissure to be 63.3%, 38.89%, 40% respectively. Nene [17] and Devi et.al [16] reported the incidence of incomplete horizontal fissure to be 8% and 18% respectively where as Lydias Quadros [18] reported to be 25% in the present study it was found to be 23.33% which is nearer to findings of Lydias Quadros.

Varalakshmi et.al. [12] and Devi et.al [16] reported the absence of the horizontal fissure to be10% and 9% resepectively. In the present study it was found to be 10% which is coinciding with the findings of varalakshmi. However, Kaul et.al., [14] and Dutta et.al, [13] reported the absence of horizontal fissure to be 40% and 34.62% which is very high compare to the present study. Thus a wide range of difference in the occurrence of accessory, major and minor fissures between and among different populations is evident.

Radha k[19], reported the incidence of incomplete oblique fissure of the left lung to be 23%. The maximum percentage of occurrence of incomplete oblique fissure was given by Dutta et.al, [13] to be 48% followed by Meenakshi et.al, [15] to be 46.6%. However, Lydias Quadros [18] reported the same to be just 1%. In the present study the incidence of incomplete oblique fissure in the left lung was found to be 20% which is near to the findings of Radha K.

Absence of the oblique fissure of the left lung was reported by Devi et.al. [16], Dutta et.al. [13] and Varalakshmi et.al. [12] was 9%, 8% and 3% respectively but the other authors reported its presence which is in support with the present study. The oblique fissure was present in all the left lungs but was incomplete in six lungs. The medical personnel must be aware of the frequency of variations in the pattern of the fissures of lungs and also the lobes to avoid and reduce the mortality and morbidity respectively during the treatment.

Enakashi ghosh [11] reported the absence of accessory fissures in her study. Lydia s Quadros [18] reported its incidence to be 13.88% in the right lung and 22.5% in the left lungs. Radha K, [19] reported their incidence to be 6.66% in the right lung and 13.33% in the left lungs. Meenakshi et.al, [15] reported the incidence of accessory fissures to be 3.33% in the right lung and 10% in the left lungs. In the present study their incidence was found to be 10% in the right lung and 6.66% in the left lungs which is not correlating with these authors. For a cardio thoracic surgeon the knowledge of accessory fissure is indispensible for planning segmental resections or pulmonary lobectomies.

CONCLUSION

The results of the present study and their

comparison with the reports of the earlier studies clearly show that there is a wide range of difference in the occurrence of accessory, major and minor fissures between and among different populations. This is indicating that a variety of genetic and environmental factors are affecting the development of the lungs resulting in the formation of such accessory / anomalous fissures. The prior awareness of the existence of the variant fissures and lobes will help the operating surgeons in the better preoperative planning for segmental resections and lobectomies. Accessory fissures are commonly confused with areas of pleural scars, linear atelectasis, or walls of bullae. The documentation and familiarization of the variations of the fissures and lobation of lungs is apt in the present era of machine vision for apt radiological diagnosis and better surgical treatment of pulmonary pathologies.

ACKNOWLEDGEMENTS

This publication is dedicated to Senior Advocate Sri Vedula Venkataramana Garu, a towering personality, tall and handsome, doyen in Law, roaring lion, brilliant in arguments, with great stunning memory. He is an inspiration for so many hardworking people. I thank H.O.D and the staff of Department of Anatomy for supporting me. I thank Mr. J. George William. Librarian, Shadan Institute of Medical Sciences, for all his help and Mr. Verma for labeling the pictures.

Conflicts of Interests: None

REFERENCES

[1]. Shah P, Johnson D, Standring S. Throax. In: Gray's Anatomy. 39th ed. Edinburgh: Chruchill Livingstone: 2005.p. 1068-9.

[2]. Godwin JD, Tarver RD. Accessory Fissures of the Lung. Am J Roentgenol, 1984;144:39-47.

[3]. Berkmen T, Berkmen YM, Austin JH. Accessory fissures of the upper lobe of the left lung: CT and plain film appearance. AJR Am J Roentgenol 1985;144:39-47.

[4]. Rosse C, Gaddum-Rosse P. Hollinshed text book of Anatomy. Philadelphia: Lipincott-Raven;1997:441-61.

[5]. Craig SR, Walker WS. A proposed anatomical classification of the pulmonary fissures. J R coll Surg Edinb 1997;422:233-4.

[6]. Larsen WJ Sherman LS, Potter SS, Scott WJ. Development of respiratory system (ch-11) Human Embryology. 3rd Edn. 2001. Elsevier. New York; 125-7.

[7]. Sadler TW (ed). Respiratory system (Ch-13). In, Langman's Medical Embryology, Philadelphia. 11th edn. Lippincot Williams & Wilkins. 2010:205-6.

[8]. Cronin P, Gross BH, Kelly AM, Kazerooni EA, Carlos RC. Normal and accessory fissures of the lung: evaluation with contiguous volumetric thin section multi detector C.T. Eur J Radiol 2010;75(2):8

[9]. Bergman RA, Afifi AK. Miyauchi R. Variations in peripheral segmentation of right lung and the base of the right and left lungs. In: illustrated Encyclopedia of Human Anatomic Variation. http:www.anatomyatlases.org/AnatomicVariants/OrganSystem/Text/LungsTrachea.Shtml (28th of November, 2010).

[10]. Medlar EM. Variations in interlobar fissures. AJR.1947;57:723-25.

[11]. Enakshi Ghosh, Rituparna Basu, Anjana Dhur, Anindya Roy, Hironmoy Roy, Amitava Biswas. Variations of fissures and Lobes in Human Lungs-A Multicentric Cadaveric Study from West Bengal, India. International Journal of Anatomy. Radiology and Surgery. 2013;2(1):5-8.

[12]. Varalakshmi, K.L., Nayak, N.J and Sangeetha, M. Mor phological Variations of Fissures of Lung; an Anatomical study. Indian Journal of applied Research. 2014;4(|8):467-469.

[13]. Dutta, S., Mandal, L., Mandal, Biswis, J., Ray, A and Bandopadhay, M. natural fissures of lung- Anatomical basis of surgical techniques and imaging. National Journal of Medical Research. 2013;3(2);117-121.

[14]. Kaul, N., Singh, V., Sethi, R. and Kaul, V. anomalous fissures and lobes of human lungs of North Indian Population of Western U.P. Journal of the anatomical Society of India. 2014;63:26-30.

[15]. Meenakshi S, Manjunath KY, Balasubramanyam V. Morphological variations of the lung fissures and lobes. Indian J Chest Dis Allied Sci 2004;46:179-82.

[16]. Bhimai ND, Rao BN, Sunitha V. Morphological variations of lung – a cadaveric study in north coastal Andhra Pradesh. Int J Biol Med Res 2011;2(4):1149-52.

[17]. Ajay Ratnakarrao Nene, Krishna Swami Gajendra, Manchiraju Venkata Ramananda Sarma. Lungs Lobes and fissures: a Morphological Study. International Journal of Experimental and clinical Anatomy 2011; 5:30-38.

[18]. Lydia S. Quadros, Ramesh Palanichamy and Antony S. D'souza. Variations in the lobes and fissures of lungs-a study in south Indian lung specimens. Eur. J. Anat. 2014;18(1):16-20.

[19]. Radha k, Durai Pandian K. Fissures and Lobes of Lungs: A Morphological and Anatomical Study. Int J. anat and Res.2015;3(2):995-98.

[20]. Kent EM, Blades B. the surgical anatomy of the pulmonary lobes. J Thoraic Surg. 1942;12:18-30.

How to cite this article: Tallapaneni Sreekanth. VARIATIONS OF FISSURES AND LOBES IN ADULT HUMAN LUNGS: A CADAVERIC STUDY FROM TELANGANA. Int J Anat Res 2016;4(4):3267-3272. **DOI:** 10.16965/ijar.2016.456